

**In the United States Court of Federal Claims**

**OFFICE OF SPECIAL MASTERS**

Filed: May 16, 2023

\*\*\*\*\*

MARJORIE MADAN,	*	PUBLISHED
	*	
Petitioner,	*	No. 19-537V
	*	
v.	*	Special Master Nora Beth Dorsey
	*	
SECRETARY OF HEALTH	*	Entitlement; Influenza (“Flu”) Vaccine;
AND HUMAN SERVICES,	*	Brachial Neuritis.
	*	
Respondent.	*	
	*	

\*\*\*\*\*

Amy A. Senerth, Muller Brazil, LLP, Dresher, PA, for Petitioner.  
Kyle Edward Pozza, U.S. Department of Justice, Washington, DC, for Respondent.

**DECISION**<sup>1</sup>

**I. INTRODUCTION**

On April 11, 2019, Marjorie Madan (“Petitioner”) filed a petition for compensation under the National Vaccine Injury Compensation Program (“Vaccine Act” or “the Program”), 42 U.S.C. § 300aa-10 et seq. (2018).<sup>2</sup> Petitioner alleges that she developed brachial neuritis

<sup>1</sup> Because this Decision contains a reasoned explanation for the action in this case, the undersigned is required to post it on the United States Court of Federal Claims’ website and/or at <https://www.govinfo.gov/app/collection/uscourts/national/cofc> in accordance with the E-Government Act of 2002. 44 U.S.C. § 3501 note (2018) (Federal Management and Promotion of Electronic Government Services). **This means the Decision will be available to anyone with access to the Internet.** In accordance with Vaccine Rule 18(b), Petitioner has 14 days to identify and move to redact medical or other information, the disclosure of which would constitute an unwarranted invasion of privacy. If, upon review, the undersigned agrees that the identified material fits within this definition, the undersigned will redact such material from public access.

<sup>2</sup> The National Vaccine Injury Compensation Program is set forth in Part 2 of the National Childhood Vaccine Injury Act of 1986, Pub. L. No. 99-660, 100 Stat. 3755, codified as amended, 42 U.S.C. §§ 300aa-10 to -34 (2018). All citations in this Decision to individual sections of the Vaccine Act are to 42 U.S.C. § 300aa.

(Parsonage-Turner Syndrome)<sup>3</sup> as the result of an influenza (“flu”) vaccination administered on September 27, 2017. Petition at Preamble (ECF No. 1). Respondent argued against compensation, stating that “this case is not appropriate for compensation under the terms of the Vaccine Act.” Respondent’s Report (“Resp. Rept.”) at 1 (ECF No. 37) (emphasis omitted).

After carefully analyzing and weighing the evidence presented in this case in accordance with the applicable legal standards, the undersigned finds that Petitioner has failed to provide preponderant evidence that her flu vaccine caused her brachial neuritis. Thus, Petitioner has failed to satisfy her burden of proof under Althen v. Secretary of Health & Human Services, 418 F.3d 1274, 1280 (Fed. Cir. 2005). Accordingly, the petition shall be dismissed.

## II. ISSUES TO BE DECIDED

The parties stipulate that (1) Petitioner received the flu vaccine at issue on September 27, 2017 in her right deltoid, (2) Petitioner had no history of brachial neuritis prior to vaccination, and (3) Petitioner underwent an anterior cervical discectomy with fusion (“ACDF”) surgery at C4-C5 and C5-C6 on November 22, 2017. Joint Statement of the Issues (“Joint Submission”), filed June 30, 2022, at 1 (ECF No. 83).

Diagnosis is not in dispute. Joint Submission at 2. The parties agree Petitioner developed brachial neuritis. However, the parties disagree as to the onset of Petitioner’s brachial neuritis. Id. Petitioner argues her brachial neuritis symptoms began October 23, 2017, approximately 26 days post-vaccination, while Respondent argues Petitioner’s brachial neuritis symptoms began November 26, 2017, approximately 60 days post-vaccination. Id.

The parties also dispute causation. Joint Submission at 2. The parties disagree as to whether Petitioner has satisfied all three Althen prongs. Id. Petitioner contends she has presented preponderant evidence of all three Althen prongs, establishing her brachial neuritis was caused-in-fact by her flu vaccine on September 27, 2017. Petitioner’s Brief in Support for a Motion for a Ruling on the Record (“Pet. Mot.”), filed July 12, 2022, at 14-19 (ECF No. 86). Respondent disagrees and argues Petitioner “failed to produce reliable evidence” of all three Althen prongs. Resp. Response to Pet. Mot. (“Resp. Response”), filed Nov. 10, 2022, at 13-19 (ECF No. 91).

The parties disagree as to whether Petitioner’s ACDF surgery was the cause of her brachial neuritis. Joint Submission at 2. Lastly, the parties disagree as to whether “[P]etitioner has established a prima facie case, thus shifting the burden to Respondent to put forth preponderant evidence ‘that [Petitioner’s] injury was in fact caused by factors unrelated to the vaccine.’” Id.

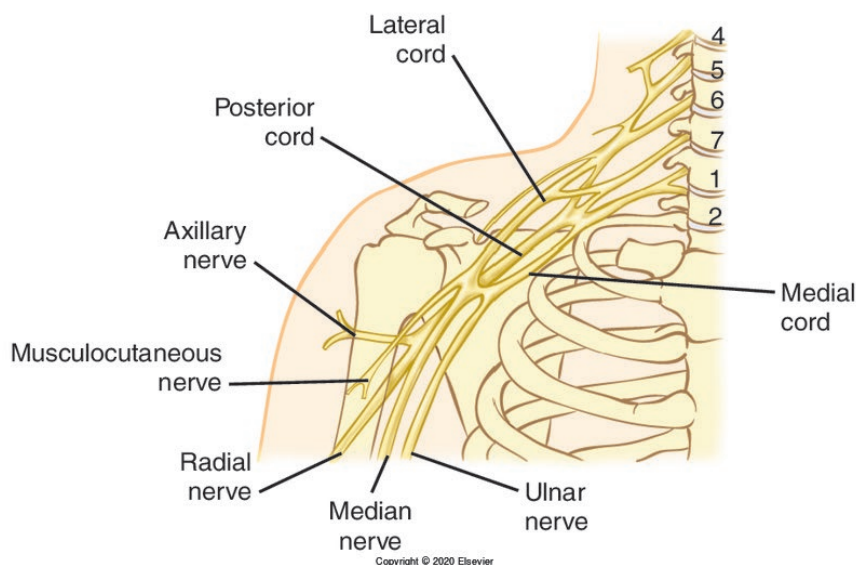
---

<sup>3</sup> The records refer to Petitioner’s condition as brachial neuritis, Parsonage-Turner Syndrome or PTS, and neuralgic amyotrophy. For clarity, the undersigned will use only brachial neuritis throughout this Decision.

### III. BACKGROUND

#### A. Medical Terminology

Brachial neuritis has been called by other names, including Parsonage-Turner Syndrome, brachial plexus neuropathy, neuralgic amyotrophy, idiopathic brachial plexus neuropathy, brachial plexitis, and brachial plexopathy.<sup>4</sup> Pet. Exhibit (“Ex.”) 27 at 14, 16; Pet. Ex. 29 at 1;<sup>5</sup> Pet. Ex. 33 at 1;<sup>6</sup> Pet. Ex. 37 at 1;<sup>7</sup> Resp. Ex. A, Tab 1.<sup>8</sup> Brachial neuritis “is a neurological condition affecting the peripheral nerves in the brachial plexus, a large conduit for nerves located deep in the shoulder.” Pet. Ex. 27 at 14. The brachial plexus is a network of nerves with its lymphatic system and blood vessels “originating from the anterior rami of spinal nerves C5-8 and T1. Situated partly in the neck . . . and partly in the axilla,” it is subdivided into “5 anterior rami, 3 trunks . . . , 6 divisions . . . , and 3 cords.” Plexus Brachialis, Dorland’s Med. Dictionary Online, <https://www.dorlandsonline.com/dorland/definition?id=98386> (last visited Apr. 24, 2023). It has numerous branches. Id.



<sup>4</sup> For consistency and clarity, the undersigned will only refer to the condition as brachial neuritis throughout this Decision, including when discussing the medical literature in this case.

<sup>5</sup> Joseph H. Feinberg & Jeffrey Radecki, Parsonage-Turner Syndrome, 6 Hosp. Special Surgery J. 199 (2010).

<sup>6</sup> G.A. Suarez et al., Immune Brachial Plexus Neuropathy: Suggestive Evidence for an Inflammatory-Immune Pathogenesis, 46 Neurology 559 (1996).

<sup>7</sup> Jeroen J.J. van Eijk et al., Neuralgic Amyotrophy: An Update on Diagnosis, Pathophysiology, and Treatment, 53 Muscle & Nerve 337 (2016).

<sup>8</sup> E. E. Fibuch et al., Postoperative Onset of Idiopathic Brachial Neuritis, 84 Anesthesiology 455 (1996).

Id.

Brachial neuritis presents as “a complex constellation of symptoms with abrupt onset of shoulder pain, usually unilaterally, followed by progressive neurologic deficits of motor weakness, dysesthesias, and numbness.” Pet. Ex. 29 at 1. “Th[e] pain may extend to the trapezius ridge, upper arm, forearm, and hand” and is “usually worse at night.” Id. at 2. “[T]he pain is usually not in the same nerve territory distribution as the paresis, and both are often not in the same territory as the sensory symptoms.” Pet. Ex. 37 at 1. Thus, “the best clue to the diagnosis of classic [brachial neuritis] is to evaluate the movement of the shoulder blades during a slow abduction-anteflexion movement, in which a unilateral disturbance of fluent scapulothoracic movement can be observed, resulting in winging.” Id. Winging is seen in about two-thirds of patients. Id. at 2. However, “[s]capular winging . . . is not always immediately recognized, especially when the patient is not appropriately disrobed and thoroughly examined.” Pet. Ex. 29 at 2.

Diagnostic evaluation includes magnetic resonance imaging (“MRI”) and electromyography (“EMG”)/nerve conduction studies (“NCS”). Pet. Ex. 37 at 7-9. Although the etiology is unclear, brachial neuritis has been reported following surgery, infection, trauma, rheumatic diseases, intense exercise, vaccination, childbirth, and various procedures and therapies. See Pet. Ex. 29 at 1-4, 2 tbl.1; Pet. Ex. 32 at 2, 8;<sup>9</sup> Pet. Ex. 34 at 1;<sup>10</sup> Pet. Ex. 37 at 3-4; Resp. Ex. A, Tab 1 at 2-3; Resp. Ex. A, Tab 4 at 4;<sup>11</sup> Resp. Ex. A, Tab 5 at 1.<sup>12</sup>

Brachial neuritis occurring between two to 28 days after vaccines containing tetanus toxoid is a covered condition in the Vaccine Injury Table. 42 C.F.R. § 100.3(a)(I)(B). The condition is not a Table Injury following the flu vaccine. See id. at § 100.3(a)(XIV). The Qualifications and Aids to Interpretation in the Vaccine Injury Table define brachial neuritis as “dysfunction limited to the upper extremity nerve plexus (i.e., its trunks, divisions, or cords). A deep, steady, often severe aching pain in the shoulder and upper arm usually heralds onset of the condition.” Id. at § 100.3(c)(6). “The pain is typically followed in days or weeks by weakness in the affected upper extremity muscle groups. . . . Atrophy of the affected muscles may occur.” Id.

---

<sup>9</sup> D. H. Marks, Parsonage-Turner Syndrome Associated with Influenza Vaccination: A Case Report with Discussion of Vaccination Neurologic Complications and Causation, 21 *Internet J. Neurology* 1 (2019).

<sup>10</sup> Francine J. Vriesendorp et al., Anti-Peripheral Nerve Myelin Antibodies and Terminal Activation Products of Complement in Serum of Patients with Acute Brachial Plexus Neuropathy, 50 *Archives Neurology* 1301 (1993).

<sup>11</sup> Richard I. Malamut et al., Postsurgical Idiopathic Brachial Neuritis, 17 *Muscle & Nerve* 320 (1994).

<sup>12</sup> Christopher J. Klein et al., Surgical and Postpartum Hereditary Brachial Plexus Attacks and Prophylactic Immunotherapy, 47 *Muscle & Nerve* 23 (2013).

## **B. Procedural History**

On April 11, 2019, Petitioner filed her petition along with medical records and an affidavit from Petitioner. Petition; Pet. Exs. 1-13. Petitioner filed additional medical records in May, July, October, and December 2019. Pet. Exs. 14-26. Respondent filed his Rule 4(c) Report, arguing against compensation, on May 20, 2020. Resp. Rept. at 1.

Petitioner filed an expert report from Dr. Frederick Nahm on September 21, 2020. Pet. Ex. 27. Respondent filed a responsive expert report from Dr. David Alexander on April 19, 2021. Resp. Ex. A.

Thereafter, the undersigned held a Rule 5 conference on June 15, 2021. Rule 5 Order dated June 17, 2021 (ECF No. 55). The undersigned noted two confounding factors: (1) Petitioner had cervical radiculopathy confirmed by studies, and (2) Petitioner had ACDF surgery and additional symptoms presented after surgery. *Id.* The undersigned preliminarily found Petitioner's medical records showed "[P]etitioner had pain in her right neck, shoulder, and arm after vaccination, but she did not develop the objective weakness/palsy and scapular winging until after surgery." *Id.* at 2. Given the confounding factors, the undersigned was unable to provide more conclusive preliminary findings. *Id.* at 3.

Petitioner filed medical records from August to December 2021 and a responsive expert report from Dr. Nahm in October 2021. Pet. Exs. 38-42; Pet. Status Rept., filed Sept. 15, 2021 (ECF No. 60). Thereafter, Respondent filed a supplemental expert report from Dr. Alexander in January 2022. Resp. Ex. C.

On March 8, 2022, the parties agreed to resolve entitlement through a Ruling on the Record. Joint Status Rept., filed Mar. 8, 2022 (ECF No. 75). The parties filed their joint submission on June 30, 2022. Joint Submission. Petitioner filed her motion for a ruling on the record on July 12, 2022, and Respondent filed his response on November 10, 2022. Pet. Mot.; Resp. Response.

This matter is now ripe for adjudication.

## **C. Factual History**

### **1. Medical History**

On September 27, 2017, at 48 years old, Petitioner received a flu vaccine in her right deltoid. Pet. Ex. 1 at 1. Petitioner had a prior medical history of Wolff-Parkinson-White syndrome,<sup>13</sup> a paralyzed vocal cord, kidney stones, gastroesophageal reflux disease, vitamin B-12 deficiency, and resolved Lyme disease. Resp. Response at 2. Petitioner also had a surgical

---

<sup>13</sup> Wolff-Parkinson-White syndrome is "the association of paroxysmal tachycardia or atrial fibrillation with preexcitation." Wolff-Parkinson-White Syndrome, Dorland's Med. Dictionary Online, <https://www.dorlandsonline.com/dorland/definition?id=111647> (last visited Apr. 24, 2023).

history of cholecystectomy in 1998, lumbar spine surgery, foot surgery, hysterectomy, and lithotripsy. Id. The parties stipulated that Petitioner had no history of brachial neuritis prior to vaccination. Joint Submission at 1.

On October 3, 2017, six days post-vaccination, Petitioner emailed her primary care provider Dr. Barry Feuer complaining of “surges of heat and heaviness in limbs,” similar to what she experienced when she was diagnosed with Lyme’s disease. Pet. Ex. 2 at 4. Petitioner requested a prescription of doxycycline<sup>14</sup> “as a precautionary measure.” Id. Later that day, she presented to Dr. Feuer’s office complaining of “[four] days of feeling very warm, fatigued, heavy sensation in limbs,” as well as bandlike pain in her head that “only lasts a few minutes.” Id. at 5. Physical examination was normal. Id. at 7-8. Assessment was fatigue and B12 deficiency. Id. at 8. Labs were ordered, including testing for Lyme and B12. Id. Petitioner tested negative for Lyme and her B12 was normal. Pet. Ex. 4 at 7.

Petitioner presented to chiropractor, Dr. Stephen M. Perlman, on October 16, 2017. Pet. Ex. 3 at 1. Petitioner reported left-sided<sup>15</sup> neck pain with radiation or referral into her upper back and down the arm to the hand. Id. Petitioner described her pain as “dull and sometimes sharp,” “constant and intense,” and worse when sleeping. Id. Petitioner thought the pain “may be due to a side effect of [her] flu shot.” Id. Cervical<sup>16</sup> spine compression was negative for radiculopathy. Id. Chiropractic and spinal manipulative therapy was performed. Id.

On October 18, 2017, Petitioner emailed Dr. Feuer requesting a prescription for doxycycline even though her blood work was negative for Lyme. Pet. Ex. 2 at 10. Petitioner reported her “neck/shoulder [were] stiff/burning,” and she described the pain as “excruciating.” Id. She also reported her fatigue improved, which she thought was due to her taking B12 twice daily. Id. Dr. Feuer prescribed doxycycline 100mg twice daily. Id. at 11.

Petitioner emailed Dr. Feuer again on October 23, 2017 and requested a prescription for an oral steroid because the doxycycline was not alleviating her “significant neck/shoulder/arm pain and numbness/tingling going down [her] arm.” Pet. Ex. 2 at 12. She reported she was “taking lots of [A]dtil with minimal improvement.” Id.

Later that day, October 23, Petitioner was seen by orthopedist Dr. Stephen Andrus for a consultation on referral from Dr. Feuer. Pet. Ex. 2 at 13. Petitioner reported “10/10 neck pain

---

<sup>14</sup> “For early Lyme disease, a short course of oral antibiotics, such as doxycycline or amoxicillin, cures the majority of cases. In more complicated cases, Lyme disease can usually be successfully treated with three to four weeks of antibiotic therapy.” Lyme Disease Antibiotic Treatment Research, Nat’l Inst. Allergy & Infectious Diseases, <https://www.niaid.nih.gov/diseases-conditions/lyme-disease-antibiotic-treatment-research> (last reviewed Nov. 20, 2018).

<sup>15</sup> This record described left-sided neck pain. Petitioner received the flu vaccine at issue in her right deltoid.

<sup>16</sup> Cervical means “pertaining to the neck.” Cervical, Dorland’s Med. Dictionary Online, <https://www.dorlandsonline.com/dorland/definition?id=8793> (last visited Apr. 24, 2023).

radiating to her right trap[ezius] and right arm;” “pain, throbbing, and numbness in her right arm;” “some subjective weakness;” “trigger points in her [trapezius muscles];” and “pain and ‘crunching’ in her right shoulder with movement.” Id. Petitioner also reported difficulty sleeping due to the pain. Id. She reported seeing “an acupuncturist with minimal relief”<sup>17</sup> and “a chiropractor with some relief.” Id.

Musculoskeletal physical examination revealed pain and restriction on cervical range of motion; 5/5 muscle strength bilaterally; normal sensation in bilateral upper extremities and head/neck; deep tendon reflexes of 3+ in right biceps and brachioradialis; tenderness, muscle spasms, and trigger points in trapezius and cervical paraspinal muscles; negative Spurling’s,<sup>18</sup> Neer, and Hawkins; and for shoulder range of motion, forward flexion of 180 bilaterally, abduction of 150 bilaterally, external rotation of 75 bilaterally, and internal rotation of T12 bilaterally. Pet. Ex. 2 at 16-17. Dr. Andrus diagnosed Petitioner with right cervical radiculopathy.<sup>19</sup> Id. at 18. “Physical exam[ination] show[ed] objective neurologic findings, including dermatomal sensory loss.” Id. He noted Petitioner had “[r]ight neck pain radiating to right trap[ezius] and arm with [numbness and tingling].” Id. Dr. Andrus ordered a cervical spine MRI and prescribed a Medrol Dose Pak for “severe pain exacerbation” and Skelaxin<sup>20</sup> at night. Id. Depending on the MRI results, he recommended an epidural injection. Id. He also indicated Petitioner could continue chiropractic care. Id.

Petitioner returned to her chiropractor on October 26, 2017. Pet. Ex. 39 at 11. She reported she felt better after a friend stretched out her arms and neck. Id. She also reported the pain was “in the neck [and] sometimes travel[ed] down the shoulder blade and arm.” Id. Diagnosis was “[s]prain of the ligaments of the cervical spine.” Id. On examination, Dr. Perlman noted hypertonic neck extensors. Id.

---

<sup>17</sup> From the records filed, it does not appear Petitioner saw an acupuncturist from October 2016 to January 2018. See Pet. Ex. 26.

<sup>18</sup> The Spurling test is used to determine whether an individual has cervical radiculopathy. Spurling Test, Dorland’s Med. Dictionary Online, <https://www.dorlandsonline.com/dorland/definition?id=112983> (last visited Apr. 24, 2023). “[T]he examiner presses down on the top of the head while the patient rotates the head laterally and into hyperextension; pain radiating into the upper limb ipsilateral to a rotation position of the head indicates radiculopathy.” Id.

<sup>19</sup> Cervical radiculopathy is “radiculopathy of cervical nerve roots, often with neck or shoulder pain; compression of nerve roots is a common cause.” Cervical Radiculopathy, Dorland’s Med. Dictionary Online, <https://www.dorlandsonline.com/dorland/definition?id=101392> (last visited Apr. 24, 2023).

<sup>20</sup> Skelaxin, a trademark for preparation of metaxalone, is a “skeletal muscle relaxant used in the treatment of painful musculoskeletal conditions.” Skelaxin, Dorland’s Med. Dictionary Online, <https://www.dorlandsonline.com/dorland/definition?id=45989> (last visited Apr. 24, 2023); Metaxalone, Dorland’s Med. Dictionary Online, <https://www.dorlandsonline.com/dorland/definition?id=30851> (last visited Apr. 24, 2023).

Petitioner emailed Dr. Andrus on October 30, 2017, indicating that she “picked up tramadol [prescription] on [F]riday” October 27, 2017, and because it made her nauseous, she stopped taking it. Pet. Ex. 2 at 20. She reported she had “been pretty miserable with neck/shoulder/arm pain and [was] having considerable weakness in right arm.” Id.

A cervical spine MRI was conducted on October 30, 2017 and revealed a small annular bulge at C3-C4, posterior disc ridge complex at C4-C5 with mass effect on the ventral nerve roots with severe bilateral foraminal stenosis secondary to endplate ridge, posterior disc ridge complex at C5-C6 with mild mass effect on the ventral nerve roots causing severe bilateral foraminal stenosis,<sup>21</sup> and an annular bulge at C6-C7 without mass effect. Pet. Ex. 2 at 23-24.

Petitioner emailed Dr. Andrus again on October 31, 2017, following her MRI, and requested a cortisone shot. Pet. Ex. 2 at 21. Dr. Andrus returned Petitioner’s email, stating that Petitioner’s “MRI showed a few disc bulges at multiple levels which is causing a narrowing of the spinal cord” and an injection can “improve symptoms related to the bulging disc” if she would like one. Id. The following morning, November 1, 2017, Petitioner emailed confirming she would like an epidural injection. Id. at 22. She described her pain as “excruciating,” and explained that “[she] cannot sleep” or “get comfortable,” and “if [she] could [she] would chop off [her] arm.” Id.

On November 3, 2017, Petitioner received a cervical epidural injection at C6-C7. Pet. Ex. 4 at 20-22. Diagnosis was confirmed as cervical radiculopathy. Id. at 20. Petitioner was prescribed Neurontin (gabapentin) for paresthesias. Id. at 21.

On November 11, 2017, Petitioner saw Dr. Alex Gitelman for a surgical consultation requested by Dr. Andrus. Pet. Ex. 4 at 23-26. Petitioner reported the injection “helped a little,” but she was still experiencing neck pain that radiated down her right arm as well as weakness in her right arm. Id. at 23. She also stated that the pain was worse at night and gabapentin was helping her sleep. Id. Physical examination showed diminished reflexes of 1+ in the right biceps, bilateral brachioradialis, and bilateral triceps and decreased strength of 4/5 in right biceps flexion. Id. at 24. Impression was right cervical radiculopathy. Id. at 25. Dr. Gitelman found Petitioner’s “symptoms correlate[d] well with the MRI findings of C4-5 and C5-6 disk osteophyte<sup>[22]</sup> complexes and foraminal stenosis.” Id. “In light of the ongoing symptoms and

---

<sup>21</sup> Foraminal stenosis occurs when narrowing in the spine causes compression of spinal nerves. Foraminal Stenosis, Cleveland Clinic, <https://my.clevelandclinic.org/health/diseases/24856-foraminal-stenosis> (last reviewed Mar. 28, 2023). “[It is] a type of spinal stenosis that affects the neural foramen, a series of openings on both sides of [the] spine.” Id.

<sup>22</sup> Osteophyte is “a bony excrescence or osseous outgrowth.” Osteophyte, Dorland’s Med. Dictionary Online, <https://www.dorlandsonline.com/dorland/definition?id=35888> (last visited Apr. 24, 2023).

neuropathy, surgical treatment with C4-5 and C5-6 ACDF<sup>[23]</sup> is reasonable,” and Petitioner agreed to the surgery. Id.

Petitioner underwent ACDF surgery at C4-C5 and C5-C6 on November 22, 2017. Pet. Ex. 4 at 40-42; Pet. Ex. 5 at 6-8. The operative note described the surgical procedure in detail. The “anterior cervical spine was identified,” and dissection of adjacent muscles was performed, to reach the C4 and C5 spine. Pet. Ex. 4 at 41. “The anterior osteophyte of C4 was removed . . . and near complete discectomy was performed. . . . Multiple loose disk fragments were removed . . . and there were multiple osteophytes impinging on the neural structures which were resected. Significant foraminal stenosis was noted bilaterally and bilateral foraminotomies<sup>[24]</sup> were performed.” Id. An intervertebral cage was placed to restore height and stability. Id. The next level, C5-6, was inspected and dissected. Id. “There was . . . significant nerve compression extending proximally and distally. Intervertebral disk space and additional endplate bone had to be resected for appropriate decompression and visualization. . . . Bilateral foraminotomies were performed and multiple disk fragments were resected . . .” Id. A cage was placed for height and stability. Id. An anterior cervical plate was placed into position and secured with appropriate length screws. Id. No complications were noted. Id.

Petitioner presented for a post-operative follow-up visit with Dr. Gitelman on December 1, 2017. Pet. Ex. 4 at 47-49. Dr. Gitelman documented Petitioner’s complaints of muscle spasms and “some pain” in her trapezius and shoulders. Id. at 47. He noted Petitioner was improving and her right upper extremity was “stronger” with “less radiculopathy.” Id. Petitioner was taking Advil and gabapentin. Id. Physical examination revealed tenderness of the bilateral trapezius muscles and 4+/5 strength in the right triceps extension. Id. at 48. Impression remained right cervical radiculopathy. Id. at 49. Dr. Gitelman prescribed a Medrol Dose Pak for pain control, ordered X-rays, and directed Petitioner to follow up in one to two weeks. Id.

On December 4, 2017, 12 days post-ACDF surgery, Petitioner returned to Dr. Gitelman for follow-up. Pet. Ex. 4 at 50-53. Petitioner complained of right shoulder swelling, explaining “it crunche[d] when [she] rotate[d] it,” right arm pain, and muscle spasms. Id. at 50. Petitioner thought she may have bursitis in her right shoulder. Id. She had no relief with Medrol. Id. Dr. Gitelman noted Petitioner’s X-rays were normal. Id. at 51. Physical examination again revealed tenderness of the bilateral trapezius muscles and 4+/5 strength in the right triceps extension. Id. at 51-52. Petitioner also had active range of motion in the right shoulder of 150 with abduction and tested positive for impingement/Hawkins test. Id. at 52. Impression was right shoulder joint pain. Id. Dr. Gitelman noted Petitioner “developed more right shoulder pain” since the surgery,

---

<sup>23</sup> ACDF “is a combination spinal decompression and spinal fusion surgery used to treat herniated discs, compressed nerves[,] or other conditions in the neck.” William D. Zelenty, ACDF Surgery: Anterior Cervical Discectomy and Fusion, Hosp. for Special Surgery, [https://www.hss.edu/conditions\\_spine-surgery-instrumented-anterior-cervical-discectomy-fusion.asp](https://www.hss.edu/conditions_spine-surgery-instrumented-anterior-cervical-discectomy-fusion.asp) (last updated Aug. 1, 2022).

<sup>24</sup> Foraminotomy is “the operation of removing the roof of intervertebral foramina, done for the relief of nerve root compression.” Foraminotomy, Dorland’s Med. Dictionary Online, <https://www.dorlandsonline.com/dorland/definition?id=19029> (last visited Apr. 24, 2023).

with “no significant abnormalities” on her X-rays. Id. Dr. Gitelman administered a right shoulder cortisone injection and ordered an MRI of Petitioner’s right shoulder. Id. Petitioner was prescribed cyclobenzaprine<sup>25</sup> for pain control and was directed to follow up in three weeks. Id. An MRI of Petitioner’s right shoulder was conducted on December 12, 2017 and was unremarkable. Id. at 58.

Petitioner saw Dr. Gitelman on December 15, 2017 for follow-up. Pet. Ex. 4 at 60-63. She reported “[s]ome relief” with shoulder injection, no mobility in shoulder, manageable pain, and muscle spasms. Id. at 60. Dr. Gitelman noted Petitioner “still ha[d] winging of the scapula.”<sup>26</sup> Id. Petitioner was taking gabapentin at night. Id. Physical examination revealed normal strength and sensation. Id. at 61. Petitioner’s right upper extremity abduction was 160 degrees with “prominent scapula winging with abduction.” Id. Impression was right cervical radiculopathy. Id. at 62. Dr. Gitelman noted Petitioner’s pain improved but “[Petitioner] noticed more winging of the right scapula,” which “[was] evident o[n] physical exam[ination].” Id. “[Petitioner] may have developed a long thoracic nerve neuropraxia, although it is uncommon for this to [appear] a week after surgery.<sup>[27]</sup> Will observe at this time, will get EMG if not much better at [six to eight] weeks.” Id. He ordered physical therapy for Petitioner’s “right winged scapula” and “right arm radiculopathy.” Id.

On December 18, 2017, Petitioner presented to Elite Physical Therapy & Rehabilitation. Pet. Ex. 7 at 7. Petitioner “complain[ed] of intermittent dull, achy, sore, tight pain on posterior, lateral left side of the neck.”<sup>28</sup> Id. She described her pain as 7/10 and stated it “is radiating towards outer side of the left hand and started [November 22, 2017] after [ACDF] surgery.” Id. She also stated she “started to feel the pain [six] months ago after playing golf.” Id. Physical examination revealed limited range of motion in neck with pain bilaterally; “severe tightness on the scalene, upper and lower trapezius, rhomboids, and paracervical muscle;” and “[g]rade 3 tenderness on the C2-T3, medial border of scapula, sub occipitals, trapezius, scalene, rhomboids, [and] paracervical muscle.” Id. at 9. On manual muscle testing, Petitioner had 2+/5 flexion and extension, 2+/5 lateral bending and rotation on the right, and 3-/5 lateral bending and rotation on the left. Id. It was recommended Petitioner attend three sessions of physical therapy per week for 10-12 weeks. Id. at 10. Petitioner attended a total of three sessions from December 18 to December 22, 2017. Pet. Ex. 7 at 3-15.

---

<sup>25</sup> Cyclobenzaprine is “used as a skeletal muscle relaxant for relief of painful muscle spasms.” Cyclobenzaprine Hydrochloride, Dorland’s Med. Dictionary Online, <https://www.dorlandsonline.com/dorland/definition?id=12135> (last visited Apr. 24, 2023). It does not appear that Petitioner took cyclobenzaprine. See Pet. Ex. 4 at 60, 69.

<sup>26</sup> This is the first medical record entry documenting winging of the scapula.

<sup>27</sup> Petitioner had surgery on November 22, 2017. Pet. Ex. 4 at 40-42. This visit was three weeks, or 23 days, after Petitioner’s surgery.

<sup>28</sup> This record refers to left-sided neck pain. See supra note 15.

Petitioner returned to Dr. Gitelman on January 23, 2018 and “still ha[d] winging of scapula” and “limited mobility in shoulder.” Pet. Ex. 4 at 69-72. Petitioner reported she was no longer doing physical therapy and was instead doing at-home exercises. Id. at 69. Physical examination revealed right upper extremity abduction to 170 degrees with “prominent scapula winging,” but was otherwise normal. Id. at 70. Impression was right shoulder joint pain. Id. at 71. Dr. Gitelman explained that “[w]hile this may be in part due to surgical positioning, it’s somewhat odd that the symptoms started only [four] days after the surgery. She also has a history of possible [brachial neuritis].” Id. He recommended a neurology evaluation and EMG with Dr. Leon Stephan Kranzler. Id.

Dr. Kranzler performed an EMG/NCS on January 25, 2018. Pet. Ex. 4 at 73. History documented “right scapula winging and pain beginning a number of days after surgery. Of note patient earlier in year had developed pain after flu shot but without any weakness.” Id. On April 4, 2018, Petitioner requested an amendment to the January 25, 2018 EMG/NCS. Id. at 82. In the amendment, Dr. Kranzler wrote, “[Petitioner] reported she had substantial pain/weakness within [two] weeks of flu shot which was received on [September 27, 2017]. Her arm pain continued after [ACDF] surgery ([November 23, 2017<sup>29</sup>]) for about [two] weeks; however, the right scapula began winging [four] days after the surgery date.” Id. Impression of EMG was “isolated right long thoracic and suprascapular neuropathies<sup>30</sup> most likely on an immune/inflammatory basis similar to brachial plexitis. Sparing of the deltoid, biceps, rhomboids[,] and paraspinals on EMG with normal sensory conductions make plexus or root involvement less likely.” Id. at 74.

On January 29, 2018, Dr. Gitelman wrote a letter stating Petitioner had a history of “[brachial neuritis], and developed right long thoracic nerve palsy. Neurologic evaluation showed that [this] [was] due to an inflammatory process. Vaccinations have been associated with such conditions. As such, [Dr. Gitelman] strongly recommend[ed] that [Petitioner] not undergo any vaccinations for the for[e]seeable future.” Pet. Ex. 2 at 30. Dr. Gitelman, on February 7, 2018, completed a medical exemption form for the flu vaccine, writing Petitioner had brachial neuritis that was “still active.” Id. at 31.

Petitioner had an initial evaluation with physical therapist Robert C. Strittmatter at Select Physical Therapy on February 5, 2018. Pet. Ex. 6 at 1. Petitioner’s flu vaccine “with severe cervical pain/stiffness” and ACDF surgery were both noted. Id. Onset of injury, described as “severe scapular winging and scapular pain/cervical pain,” was December 1, 2017. Id. On Petitioner’s Patient Information Form, she noted injury onset was December 1, 2017, diagnosis/body part was the shoulder, and injury was post-ACDF surgery. Pet. Ex. 38 at 6. On her Medical History Form, Petitioner noted her injury occurred due to “flu shot and post-surgical inflammation.” Id. at 9. Physical examination revealed severe scapular winging on the right and decreased range of motion. Pet. Ex. 6 at 1-2. Mr. Strittmatter summarized that “[o]ne month prior to ACDF, [Petitioner] received her flu shot and [complained of] severe cervical

---

<sup>29</sup> Petitioner’s ACDF surgery was November 22, 2017. Pet. Ex. 4 at 40-42; Pet. Ex. 5 at 6-8.

<sup>30</sup> Petitioner’s initial, technically specific diagnosis was right long thoracic and suprascapular neuropathies, but the records usually refer to her diagnosis as brachial neuritis. For continuity, the undersigned refers to Petitioner’s diagnosis as brachial neuritis.

pain/stiffness worse on the right that she attributed to a Lyme flare-up.” Id. at 3. Following surgery “[s]ymptoms exacerbated . . . and winging scapula developed with confirmed long thoracic nerve palsy along with suprascapular nerve palsy in her dominant right [upper extremity].” Id. He recommended Petitioner attend two sessions per week for a total of six weeks.<sup>31</sup> Id.

On February 21, 2018, Petitioner underwent a cervical spine MRI that revealed good post-operative appearance at C4-C5 and C5-C6, mild degenerative disc disease at C3-C4 and C6-C7, and no central spinal stenosis or nerve impingement. Pet. Ex. 4 at 87-88.

On February 26, 2018, Petitioner presented to Dr. Emily Slate on referral from Dr. Gitelman. Pet. Ex. 4 at 89-91. Dr. Slate documented,

[Petitioner] state[d] that she developed severe pain radiating from her shoulder into her arm shortly after receiving a flu shot in September. An MRI of her cervical spine showed foraminal stenosis at multiple levels and she underwent ACDF ([November 22, 2017]). Four days after the procedure, she noted new onset of scapular winging and “crunching” in her shoulder. MRI of the shoulder was normal and cortisone injection in the subacromial space had no effect. An EMG/NCS ([January 25, 2018]) showed denervation of the supraspinatus, infraspinatus[,] and serratus anterior consistent with brachial neuritis.

Id. at 89. Petitioner “complain[ed] primarily of weakness and general feeling of instability in her shoulder;” she denied numbness, paresthesias, or “any change/improvement since the onset of weakness;” and she indicated “[h]er radiating pain [] resolved although she [did] continue to have discomfort in the shoulder.” Id. Physical examination revealed scapular winging along with atrophy of the supraspinatus, infraspinatus, and acromioclavicular. Id. at 90. Impression was “likely [brachial neuritis] [status post] ACDF.” Id. Petitioner was to continue with physical therapy and her current pain management regimen. Id. Dr. Slate ordered MRIs of the upper right arm and brachial plexus. Pet. Ex. 9 at 10-11, 19.

On April 3, 2018, Petitioner underwent MRIs. Pet. Ex. 9 at 11, 19. Under indication, Petitioner’s history was documented as, “[p]ain extending down right extremity following [flu] vaccine September 2017. Pain subsided following cervical spine surgery in November 2017 but then developed weakness following surgery and subsequent scapular winging.” Id. at 11, 19. Impression of the “MRI of the brachial plexus and upper arm demonstrate[d] denervation changes of the right serratus anterior muscle . . . with suspected focal intrinsic constriction of the long thoracic nerve suggestive of [brachial neuritis].” Id. at 11, 20. “There [was] also selective denervation edema pattern of the lower section of the subscapularis muscle, which could reflect a superimposed C6 radiculopathy. Imaged portions of the right-sided cervical neural foramina demonstrate[d] severe foraminal stenosis at C5-6 and C6-7. Correlation with dedicated cervical spine MRI and electrodiagnostic studies [was] recommended.” Id. at 11-12, 20.

---

<sup>31</sup> It appears Petitioner did not attend additional sessions. See Pet. Ex. 6 at 1-8.

On April 12, 2018, Petitioner saw Dr. Perlman, her chiropractor. Pet. Ex. 39 at 14. Diagnosis was serratus anterior palsy. Id. Petitioner's winged scapula was noted on examination. Id.

Petitioner returned to Dr. Kranzler on May 17, 2018 for an EMG/NCS. Pet. Ex. 2 at 36. His history noted Petitioner's flu vaccine on September 27, 2017, "with subsequent right arm and shoulder pain," and Petitioner's ACDF surgery on November 22, 2017, with "scapula winging noted [four] days after surgery." Id. Dr. Kranzler found Petitioner's EMG/NCS "now reveal[ed] chronic axonal right long thoracic and suprascapular neuropathies" with "[n]o active denervation [] seen." Id. at 37. Improvement in both nerves, especially the suprascapular nerve, was noted. Id.

Petitioner returned to Dr. Gitelman on June 26, 2018. Pet. Ex. 4 at 102-04. She "continue[d] to have limited mobility in shoulder" and was "unable to rotate her right scapula." Id. at 102. Petitioner was not going to physical therapy but was instead doing at-home exercises. Id. She denied numbness, tingling, and neck pain, and she reported her biceps and triceps were stronger. Id. Dr. Gitelman noted Petitioner's cervical spine, pre-operative radiculopathy, and right upper extremity weakness were "much better." Id. at 104. "[Petitioner] continue[d] to have right shoulder pain and winged scapula [consistent with] [brachial neuritis]." Id. He noted Petitioner's recent EMG showed some improvement. Id. He recommended a brachial neuritis specialist regarding possible surgery. Id.

On November 7, 2018, Petitioner saw Dr. Christopher J. Winfree for neurosurgical management options. Pet. Ex. 8 at 2-4. On physical examination, Petitioner had "5/5 strength in her bilateral upper extremity muscles;" "full strength in her right trapezius, rhomboids, supraspinatus[,] and infraspinatus;" "a winging right scapula when she [held] her arm straight out in front of her against resistance suggestive of a long thoracic neuropathy;" and "no sensory deficit in the upper extremities." Id. at 3. Dr. Winfree determined Petitioner had "a classic case of [brachial neuritis]." Id. He recommended surgery for "exploration of the long thoracic nerve and internal neurolysis to release the hourglass constriction." Id.

Dr. Gitelman wrote a letter on February 5, 2019, noting Petitioner developed brachial neuritis and had not improved for over one year. Pet. Ex. 11 at 1. He wrote "[Petitioner] ha[d] severe winging of the right scapula and weakness in [l]ong [t]horacic nerve." Id. He recommended Petitioner see a subspecialist who specializes in this type of surgery (Dr. Lee). Id.

Accordingly, on February 11, 2019, Petitioner saw specialist Dr. Steve K. Lee for a consultation and Petitioner reiterated her clinical course. Pet. Ex. 9 at 7-10. Petitioner reported she was unable "to work out to the extent that she would like. She still works out as much as she can but the [right upper extremity] is not moving 'normally.'" Id. at 8. Petitioner "believe[d] the abnormal movements [led] to strain of the [right upper extremity] and [] she believe[d] she [was] developing compensatory left lower back pain." Id. Physical examination revealed right forward shoulder elevation of 4/5, right forward elevation lacked 10 degrees, and medical winging of scapula. Id. at 9. Dr. Lee wrote "clinical exam/history/imaging appear[ed] consistent with [brachial neuritis], however[,] there may be a component of cervical radiculopathy especially considering that [Petitioner] first noticed the [right upper extremity] weakness

postoperatively after ACDF.” Id. at 10. Dr. Lee ordered repeat EMG/NCS and recommended possible neurolysis of constriction bands depending on the EMG/NCS results. Id.

Dr. Joseph Feinberg conducted an EMG/NCS on April 10, 2019 that revealed “evidence of a right long thoracic neuropathy with severe denervation, limited axonal regeneration[,] and residual denervation . . . most likely secondary to [brachial neuritis]. There [was] no evidence of a brachial plexopathy or other peripheral neuropathy.” Pet. Ex. 14 at 1-2.

A repeat MRI of Petitioner’s right brachial plexus was done on April 24, 2019 and “redemonstrate[d] severe focal intrinsic constriction of the long thoracic nerve at the level of the coracoid process.” Pet. Ex. 15 at 1.

On May 8, 2019, Petitioner underwent a neuroplasty<sup>32</sup> of the brachial plexus and right long thoracic nerve at the chest wall with Dr. Lee. Pet. Ex. 18 at 56-57. Petitioner returned on May 13, 2019 with continued scapular winging. Id. at 188. She had no pain and “fe[lt] like her right arm [was] more stable when she [held] her arms overhead.” Id. One week later, on May 21, 2019, Petitioner followed up. Id. at 189. She felt her arm was more stable. Id. On examination, “[w]inging appear[ed] to be less severe.” Id. Petitioner was referred to Dr. Lawrence V. Gulotta for an evaluation of shoulder crepitus and to occupational therapy for range of motion and strengthening. Id. at 190.

Petitioner presented to Dr. Gulotta on June 4, 2019 for an evaluation of right shoulder snapping. Pet. Ex. 18 at 190. Petitioner reported that she noticed “snapping around her shoulder with motion” that “is uncomfortable but not frankly painful.” Id. On examination, Petitioner had “[p]rofound medial scapular winging” and “snapping of the superior border of the scapula against the thorax.” Id. at 193. Assessment was “[r]ight medial scapular winging causing snapping scapula secondary to long thoracic nerve palsy. Status post neuroplasty.” Id. at 194. Dr. Gulotta discussed a possible cortisone injection, but Petitioner declined,<sup>33</sup> and a possible “split pectoralis major transfer for scapular winging should the nerve not recover.” Id. Petitioner was seen for an initial physical therapy evaluation on June 13, 2019. Pet. Ex. 17 at 10-14. Impression was brachial neuritis. Id. at 12.

No additional relevant medical records have been filed.

---

<sup>32</sup> Neuroplasty is “plastic surgery of a nerve.” Neuroplasty, Dorland’s Med. Dictionary Online, <https://www.dorlandsonline.com/dorland/definition?id=33823> (last visited Apr. 24, 2023).

<sup>33</sup> Petitioner’s pain worsened and she requested a cortisone injection on June 14, 2019. Pet. Ex. 16 at 6. However, it does not appear Petitioner received this injection. Pet. Ex. 42 at 353 (noting the order for a cortisone injection expired one year later on June 15, 2020).

## D. Expert Reports

### 1. Petitioner's Expert, Dr. Frederick Nahm<sup>34</sup>

#### a. Background and Qualifications

Dr. Nahm is board certified in neurology and electrodiagnostic medicine. Pet. Ex. 27 at 1; Pet. Ex. 28 at 3. He obtained an M.S. and Ph.D. from the University of California, San Diego and an M.D. from the University of Michigan Medical School. Pet. Ex. 28 at 1. Following his M.D., he completed a neurology residency and three fellowships at Harvard. *Id.* at 2. Since 2002, Dr. Nahm has been the Founder and Managing Partner at NeuroCare Health P.C. *Id.* at 1. He is “engaged in clinical neurology, diagnostic neurophysiology, and intraoperative neuromonitoring.” Pet. Ex. 27 at 2. “As a fellowship trained neuromuscular expert, [he] ha[s] diagnosed and treated many individuals with various forms of brachial plexus injur[ies], including those related to infection, trauma, and vaccinations.” *Id.*

#### b. Opinion

Dr. Nahm opined “that the medical history, laboratory studies, and other findings support the view that the flu vaccine given to [] [P]etitioner, more likely than not, triggered an autoimmune inflammatory response which led to the development of brachial neuritis and neurological injury.” Pet. Ex. 27 at 20; see also Pet. Ex. 40 at 4.

#### i. Althen Prong One

Dr. Nahm opined that the flu vaccine can trigger an immune-mediated cross-reaction through molecular mimicry that can cause brachial neuritis, similar to that seen with Guillain-Barré Syndrome (“GBS”). Pet. Ex. 27 at 14-15, 20.

Although the 2012 Institute of Medicine (“IOM”)<sup>35</sup> report found “[t]he evidence [] inadequate to accept or reject a causal relationship between [flu] vaccine and brachial neuritis,” Dr. Nahm opined recent immunizations have been reported as the second most common risk factor in developing brachial neuritis. Pet. Ex. 27 at 14 (quoting Pet. Ex. 30 at 49) (citing Pet. Ex. 29 at 2 (“Recent immunization accounts for the second most common risk factor with cases reported in 15% of individuals who developed [brachial neuritis].” (citing Resp. Ex. A, Tab 1))); see also Pet. Ex. 32 at 8 (“[Brachial neuritis] . . . may follow viral illness or vaccination.”); Pet. Ex. 34 at 1 (“Infection, mostly viral, or immunization is a preceding event in 40% of cases.”). Additionally, the National Organization for Rare Disorders (“NORD”) stated that “although the exact cause of [brachial neuritis] is unknown, [brachial neuritis] is believed to be caused by an abnormality of the immune system—an immune-mediated disorder.” Pet. Ex. 32 at 2. Most cases of brachial neuritis, according to NORD, are “caused by an immune-mediated

---

<sup>34</sup> Petitioner submitted two expert reports from Dr. Nahm. Pet. Exs. 27, 40.

<sup>35</sup> Inst. of Med., Influenza Vaccine, in Adverse Effects of Vaccines: Evidence and Causality 293 (Kathleen Stratton et al. eds., 2012). The IOM is now the National Academy of Medicine.

inflammatory response to some infection or environmental trigger that damages the nerves of the brachial plexus,” with “[t]he most common ‘triggering’ factor . . . to be a recent viral illness, but can include recent immunization.” Id.

The relevant immune-mediated mechanisms identified by Dr. Nahm include nerve demyelination caused by “both humoral and cellular immune mechanisms,” such as “complement activation” and “molecular mimicry.” Pet. Ex. 27 at 13-14. Dr. Nahm stated that mononuclear inflammatory cells have been found in endoneurium<sup>36</sup> of biopsied affected nerves, and anti-peripheral nerve myelin (“anti-PNM”) antibodies and terminal complement products (C5b-C9) have been found in the serum of the those with brachial neuritis. Id. (citing Pet. Exs. 33-34). Similarly, patients with GBS have been found to have high levels of anti-PNM antibodies, “which can bind to peripheral nerve glycolipids and lead to peripheral nerve demyelination through complement activation.” Id. at 15 (citing Pet. Ex. 35).<sup>37</sup> He noted this is “exactly” what “ha[s] been shown to be present in the ser[a] of those with brachial neuritis.” Id. He also opined that because the flu vaccine has been linked to GBS, there is “some basis” for the same theories to link the flu vaccine and brachial neuritis, “given some commonality in the immunological profile of those with [brachial neuritis] and GBS.” Id. “Both conditions can be explained by reference to molecular mimicry, and given these similarities, [there is] a plausible biological explanation.” Id.

In support of his opinions, Dr. Nahm cited medical literature. Van Eijk et al. reviewed existing studies and concluded that brachial neuritis was “an organ-specific immune-mediated disorder. The immune hypothesis is supported by the fact that half of affected patients report antecedent events that trigger the immune system, mostly infections , but also surgery . . . .” Pet. Ex. 37 at 3-4. Citing Suarez et al., discussed in more detail below, van Eijk et al. reported that biopsies of brachial plexus nerve bundle fibers revealed findings consistent with an immune-mediated etiology. Id. at 4. These findings included T-cell infiltration, axonal degeneration, lymphocytes associated with autoimmune diseases, and increased levels of certain complement. Id.

Marks provided a discussion on the mechanisms thought to cause brachial neuritis, including molecular mimicry, and analogized brachial neuritis to GBS. Pet. Ex. 32. Marks explained molecular mimicry is a theory by which “a defined sequence and/or conformational homology between an exogenous agent (foreign antigen, such as [flu] vaccine) and self-antigen lead[] to the development of tissue damage and clinical disease from antibodies and T cells directed initially against the exogenous agent ([flu] antigens) that also react against self-antigen.” Id. at 6. After examining studies documenting the development of neurologic conditions,

---

<sup>36</sup> Endoneurium is “the connective tissue in a peripheral nerve fascicle” that “forms an interstitial layer around the neurilemma that surrounds individual myelinated nerve fibers and Remak bundles of unmyelinated fibers.” Endoneurium, Dorland’s Med. Dictionary Online, <https://www.dorlandsonline.com/dorland/definition?id=16353> (last visited Apr. 24, 2023).

<sup>37</sup> C. L. Koski et al., Anti-Peripheral Nerve Myelin Antibodies in Guillain-Barre Syndrome Bind a Neutral Glycolipid of Peripheral Myelin and Cross-React with Forssman Antigen, 84 J. Clinical Investigation 280 (1989).

including brachial neuritis and GBS, following vaccinations, including the flu vaccine, he found “[b]oth [brachial neuritis] and GBS are uncommon neurological disorders which have been temporally and causally related to [flu] vaccination.” Id. at 4-5. Thus, “a discussion of the immunologic and vaccination causation of GBS is [] relevant and applicable to any similar discussion of [brachial neuritis].” Id. at 5. He acknowledged “[t]he etiology of brachial neuritis is unclear but [noted it] is thought to be an immune-mediated inflammatory reaction against brachial plexus nerve fibers involving complement, [anti-PNM] antibodies[,] and T cells.” Id. Thus, when determining whether the flu vaccine can cause brachial neuritis, molecular mimicry is a “persuasive biological explanation” because it has been shown to link the flu vaccine to GBS. Id. at 6.

Dr. Nahm also cited to Suarez et al., who similarly suggested an immune-mediated mechanism was at play in the development of brachial neuritis. Pet. Ex. 33 at 1. The authors biopsied four patients with typical cases of brachial neuritis and found “prominent collections of inflammatory cells (especially T lymphocytes) within the brachial plexus.” Id. None of their patients reported an antecedent viral infection, immunization, or surgery. Id. at 2, 2 tbl.1. Although the cause of brachial neuritis is not known, Suarez et al. explained “several lines of evidence implicate both humoral and cellular immune mechanisms,” and specifically noted anti-PNM antibodies may be present in patients with brachial neuritis. Id. at 1-2. Suarez et al. hypothesized that brachial neuritis is an immune-mediated disease given its clinical similarities with serum sickness, although “[i]mmune complexes . . . have not been described in patients with acute [brachial neuritis].” Id. at 1-2.

The Vriesendorp et al. paper reported the findings of a study on the alternative pathway of the complement system and its potential role in the cause of brachial neuritis. Pet. Ex. 34 at 1. The authors studied three patients with acute brachial neuritis. Id. at 2. All three patients had a preceding infection. Id. They found that complement-fixing antibodies to peripheral nerve myelin and terminal complement activation products were elevated in the serum of patients with brachial plexus when compared to normal controls. Id. Notably, the levels of complement-fixing antibodies were “markedly increased” as compared to the controls. Id. The authors concluded that “[d]etection of anti-PNM antibodies and complement activation products in the serum . . . supports the hypothesis that complement-dependent, antibody-mediated demyelination” may play a role in causing the nerve damage seen in brachial neuritis. Id. at 3.

To further support his analogy between GBS and brachial neuritis, specifically that anti-PNM antibodies are found in both, Dr. Nahm cited Koski et al. Pet. Ex. 27 at 15 (citing Pet. Ex. 35). Koski et al. compared antibodies in GBS patients with those of healthy controls and disease controls. Pet. Ex. 35 at 1. One of the disease controls had brachial neuritis. Id. at 3. Koski et al. found complement-fixing antibodies in 10 acute-phase GBS patients “significantly elevated” over those of nine healthy controls and six disease controls, including the disease control with brachial neuritis. Id. at 3, 3 fig.3. Koski et al. did not discuss vaccinations or any effect they may have with regard to these antibodies.

Dr. Nahm cited to two case reports of brachial neuritis following flu vaccination. Pet. Ex. 27 at 14 (citing Pet. Exs. 31-32). The first, authored by Shaikh et al.,<sup>38</sup> discussed a case of brachial neuritis in a 46-year-old woman. Pet. Ex. 31 at 1. She presented with a one month history of severe left shoulder pain that was acute in onset and developed “a few days” following a flu vaccination in the left deltoid. Id. Within one week of pain onset, she developed weakness in her left upper extremity with difficulty performing usual activities. Id. Examination revealed left arm weakness (1/5) and painfully reduced range of motion in the left shoulder in all directions. Id. Cervical spine MRI was normal, excluding cervical radiculopathy or myelopathy. Id. EMG/NCS revealed “severe axonal denervation of the left deltoid and supraspinatus muscles with mild involvement of the infraspinatus muscle and evidence of reinnervation.” Id. Her treating physician diagnosed her with “postvaccination acute brachial neuritis.” Id. Shaikh et al. noted “[t]he aetiology of brachial neuritis is unclear but is thought to be an immune-mediated inflammatory reaction against brachial plexus nerve fibres involving complement, antiperipheral nerve myelin antibodies and T cells.” Id. at 1-2. The authors acknowledged that “there is insufficient evidence to accept (or reject) an association” between the flu vaccine and brachial neuritis. Id. at 2.

The second case report was authored by Marks, discussed above, and described a case of brachial neuritis following flu vaccination in a 61-year-old male. Pet. Ex. 32 at 1. The patient received a flu vaccine in August 2010 and had no adverse reaction. Id. He received his second flu vaccine in November 2013, and within six weeks, “he began experiencing dull, aching left shoulder pain, following by pain in the back of his neck initially characterized as ‘electrical and shooting, later tightness.’” Id. He then developed weakness of his left upper extremity, which progressed from his left thumb and index finger to his entire hand and proximal left upper extremity. Id. After a neurology evaluation, he was diagnosed with brachial neuritis. Id. Using generally accepted procedures to determine whether a causal relationship exists between the flu vaccine and the patient’s development of brachial neuritis, Marks took into account six criteria.<sup>39</sup> Id. at 2-3. He found that “[b]ecause of the number of supporting factors including temporality, consistency to other examples of vaccine-induced neurologic injury, and an absence of alternative explanations, the degree of causal relatedness for this case report is [p]robable, or expressed another way, more likely than not.” Id. at 7.

Dr. Nahm acknowledged that brachial neuritis may also follow surgery. Pet. Ex. 27 at 18-19. He opined “very little is known regarding the pathophysiology . . . given its rarity.” Id. at 19. “While many cases [of post-surgical brachial neuritis] have been associated with mechanical conditions such as improper positioning or traction on the brachial plexus, there is also speculation that surgical stress can provoke virus reactivation in nerve roots, but no evidence has been published in support of this conjecture” according to Dr. Nahm. Id. at 18.

---

<sup>38</sup> Maliha Farhana Shaikh et al., Acute Brachial Neuritis Following Influenza Vaccination, 2012 *BMJ Case Reps.* 1.

<sup>39</sup> For more information regarding these criteria and their application to the patient in Marks, see Pet. Ex. 32 at 2-7.

Regarding brachial neuritis after surgery, Dr. Nahm cited an article by Feinberg and Radecki. Pet. Ex. 29 at 3-4. They explained that brachial neuritis has been “reported extensively” following surgical procedures, and occurs after many different types of surgeries, including orthopedic procedures. Id. at 3. Several mechanisms have been postulated. Id. “The two leading theories regarding the etiology of postsurgical [brachial neuritis] include traction injury to the brachial plexus resulting from improper positioning and immune-mediated inflammation of the brachial plexus.” Id. The development of brachial neuritis following surgery can occur within 24 hours or up to a week or more following surgery. Id.

**ii. Althen Prong Two**

Dr. Nahm opined that Petitioner’s post-vaccination symptoms were consistent with brachial neuritis. Pet. Ex. 27 at 16. “[I]f [] [P]etitioner did have symptoms of a cervical radiculopathy, as was diagnosed by the orthopedic surgeon, then that condition would only account for a portion of [Petitioner’s] symptoms referable to the C6 root, and could not account for the entirety of [] [P]etitioner’s symptoms nor their temporal course.” Id.

Dr. Nahm summarized Petitioner’s clinical course and opined that “more likely than not, . . . [P]etitioner developed a flu vaccine related neuritis 19-26 days following the vaccine, eventually leading to the weakness which persisted despite surgical intervention for presumed cervical radiculopathy.” Pet. Ex. 27 at 15-17. On September 27, 2017, Petitioner received a flu vaccine. Id. at 16. Twenty-six days later, on October 23, 2017, Petitioner had severe pain of 10/10 in her right trapezius and arm. Id. at 15. Dr. Nahm noted that six days post-vaccination, Petitioner experienced fatigue and a heavy sensation in her limbs, which “may have [been] some initial systemic reaction to the vaccine administration;” however, “the majority of symptoms started 20 days later, approximately 26 days after the flu vaccine.” Id.

The pain documented on October 23, 2017 was then followed by numbness and weakness in the right biceps. Pet. Ex. 27 at 15-16 (citing Pet. Ex. 4 at 23-25 (records from November 11, 2017)). Petitioner underwent a cervical MRI on October 30, 2017 that showed abnormal findings in Petitioner’s mid-cervical region. Id. at 16. According to Dr. Nahm, due to Petitioner’s persistent symptoms of numbness and weakness, and Petitioner’s lack of response to epidural injections or pain medications, Petitioner underwent ACDF surgery on November 22, 2017. Id.

After surgery, Petitioner reported “[p]ersist[ent] right shoulder and trapezius pain” on December 1, 2017 and “worsened scapular winging” on December 15, 2017. Pet. Ex. 27 at 16. Dr. Nahm, quoting van Eijk et al., noted that “[i]n acute [brachial neuritis], the pain is more often in the region of the trapezius muscle and acromion, movement restriction is usually just or mainly present during active attempts at motion (i.e., due to paresis), and scapular movement is often discoordinated.” Id. at 17 (quoting Pet. Ex. 37 at 6). Additionally, Dr. Nahm noted the scapular winging was “possibly indicative of a long thoracic nerve neuropraxia, which according to the surgeon, Dr. Gitelman, was uncommon for this to occur a week after surgery.” Id. at 16.

Petitioner’s January 25, 2018 EMG indicated “right thoracic nerve and suprascapular neuropathies . . . most likely immune inflammatory related.” Pet. Ex. 27 at 16. Dr. Nahm

opined “the EMG findings were not suggestive of a radiculopathy, but rather an inflammatory appearing peripheral nerve neuropathies as in brachial neuritis.” Id. “If [] [P]etitioner’s pain and neurological symptoms ha[d] actually been due to cervical radiculopathy,” Dr. Nahm would have expected more findings on EMG consistent with a cervical radiculopathy. Pet. Ex. 40 at 4. “A normal EMG examination of [the deltoid, biceps, triceps and rhomboid muscles] does not support the opinion that the [P]etitioner’s neck, arm and trapezius pain were the result of a cervical radiculopathy severe enough to cause either the degree of pain and limitation reported, nor the documented biceps weakness.” Id. Petitioner’s March 16, 2018 MRI showed findings consistent with brachial neuritis. Pet. Ex. 27 at 16. On November 7, 2018, Petitioner saw Dr. Winfree who noted Petitioner had “roughly one year” of symptoms consistent with “a classic case of [brachial neuritis].” Id. at 18 (quoting Pet. Ex. 8 at 3).

Dr. Nahm further opined Petitioner “more likely than not” was suffering from brachial neuritis rather than cervical radiculopathy given her clinical course and lack of response to injections and physical therapy despite her cervical MRI findings. Pet. Ex. 27 at 17; Pet. Ex. 40 at 4. Petitioner first saw her chiropractor, Dr. Perlman, on October 16, 2017, where the objective examination found cervical spine compression was negative for cervical radiculopathy. Pet. Ex. 27 at 17 (citing Pet. Ex. 3 at 1). Additionally, Petitioner did not respond to cervical epidural injection, which Dr. Nahm opined would have helped if Petitioner’s symptoms were due to a cervical radiculopathy. Id. And after ACDF surgery, Petitioner had “little relief from the main symptoms of trapezius/shoulder pain,” although her right triceps weakness improved. Id. (citing Pet. Ex. 4 at 48).

“The onset of the [P]etitioner’s symptoms were acute, not more insidious as is seen with a cervical radiculopathy, and she did not respond as well to cervical epidural injections, as would be expected were this an acute radiculopathy.” Pet. Ex. 27 at 19; see also Pet. Ex. 40 at 4. Additionally, van Eijk et al. explained that “[c]ervical spine MRI will show abnormalities in over half of [brachial neuritis] patients, ranging from mild degenerative pathology to spinal stenosis with subclinical myelopathy,” and “cervical spine degeneration is very common in healthy adult subjects of any age.” Pet. Ex. 37 at 8. In practice, some patients are first diagnosed with cervical radiculopathy, confirmed by imaging, “but then, after a few weeks, suddenly develop[] additional pain and symptoms that fit into the clinical picture of [brachial neuritis].” Id. at 6, 8.

Dr. Nahm noted “one of the most common mimics of brachial neuritis is cervical radiculopathy,” and cited van Eijk et al. for support. Pet. Ex. 27 at 18 (citing Pet. Ex. 37); see also Pet. Ex. 29 at 3. Van Eijk explained that

[i]n the case of acute cervical radiculopathy, all symptoms of pain, sensory disturbances, and paresis will be present in a single root distribution, whereas [brachial neuritis] typically presents with patchy paresis with a localization that does not match the area of pain, as both do not match the distribution of sensory symptoms. Typically, the symptoms in [brachial neuritis] do not match a single root distribution, although, on superficial examination, it may appear so . . . .

Pet. Ex. 37 at 6.

Dr. Nahm opined that if Petitioner did have a “co-existing cervical radiculopathy, it would most likely have been a C6 or C5/6 given the fact that the only weakness documented in the records was that of the right biceps [] prior to the [ACDF] surgery.” Pet. Ex. 27 at 17 (citing Pet. Ex. 4 at 25). “A C6 radicular pattern would present with mainly pain and sensory changes down the arm in a dermatomal fashion, and not in the shoulder location that the [P]etitioner reported.” Id. Thus, he concluded that “[t]he overwhelming preponderance of evidence (including EMG and [NCS], and brachial plexus MRI studies) proves that the [P]etitioner ha[d] brachial neuritis.” Id. at 18

Next, with regard to whether Petitioner’s brachial neuritis was due to her vaccination or ACDF surgery, Dr. Nahm opined “[t]he preponderance of the clinical data including the [P]etitioner’s clinical course, suggests that the [P]etitioner was in a progressive course of neuritis that began after the flu vaccine that carried through to her surgery, and that the weakness may have been present at or before the time of the cervical surgery.” Pet. Ex. 27 at 18-19. He also noted that in Petitioner’s case, there was an “absence of any intraoperative monitoring abnormalities during the surgery [that] [] argue[s] against an intraoperative position cause” of Petitioner’s brachial neuritis. Id. at 18. Dr. Nahm acknowledged that the onset of Petitioner’s scapula winging was unclear because no examination of the scapular structures was done prior to surgery. Id. Thus, this “lack of any clear documentation raises the possibility that the more proximal weakness was present at or before the time of surgery[,] but this remains speculative.” Id. at 18-19.

Lastly, Dr. Nahm opined that Petitioner had no pre-existing condition or viral prodrome that would explain her development of brachial neuritis. Pet. Ex. 27 at 19.

Dr. Nahm concluded that “[t]he obvious and proximate cause” of Petitioner’s brachial neuritis was the flu vaccine. Pet. Ex. 27 at 19. “[P]etitioner may have had a co-existing condition of cervical radiculopathy (with C6 pattern weakness),” but that “would neither explain the clinical course of pain, nor the subsequent pattern of weakness and peripheral nerve injury shown on both EMG/NCS and MRI studies.” Id. Thus, he found a “preponderance of evidence” supports the finding that “[P]etitioner developed a post-vaccine brachial neuritis accounting for the severe and excruciating pain, and then the subsequent weakness due to injury of the long thoracic and suprascapular nerves.” Id.

### iii. Althen Prong Three

Dr. Nahm opined that the majority of Petitioner's symptoms began 26 days post-vaccination when she exhibited severe 10/10 pain in her right neck, trapezius, and arm.<sup>40</sup> Pet. Ex. 27 at 15, 19. He noted this is within the time frame in the Vaccine Injury Table for brachial neuritis after the tetanus toxoid vaccine (2-28 days) and for GBS post-flu vaccine (2-42 days). Id. Because "[b]rachial neuritis shares some immunological similarities to GBS, [] it is not unreasonable to assume that the time frame for a post-vaccine [brachial neuritis] would be similar to that of post-flu GBS." Id. at 19.

In support of his opinion as to Althen prong three, Dr. Nahm cited information from case reports. The patient in Shaikh et al. developed pain "a few days" after flu vaccination, and within one week, she developed weakness, and "was diagnosed with postvaccination acute brachial neuritis." Pet. Ex. 31 at 1. The patient in Marks developed symptoms consistent brachial neuritis within days to weeks (but within six weeks) after the flu vaccine, which "[was] consistent with the time period described in a number of neurologic non-allergic non-immediate reaction vaccine-related adverse effects." Pet. Ex. 32 at 1, 3. For support, Marks relied on medical literature discussing the development of GBS in the six weeks following vaccinations. Id. at 3.

For post-surgical brachial neuritis, Dr. Nahm stated onset "typically occurs within 24 hours," although there have been reports of a delayed onset. Pet. Ex. 27 at 18; see Pet. Ex. 29 at 3 (noting brachial neuritis symptoms post-surgery can occur within 24 hours of surgery or up to a week or more following surgery).

## 2. Respondent's Expert, Dr. David Alexander<sup>41</sup>

### a. Background and Qualifications

Dr. Alexander obtained his M.D. from the University of Minnesota, after which he completed an internship at Boston University and a neurology residency at the Neurological Institute of New York, Columbia-Presbyterian Medical Center. Resp. Ex. A at 2; Resp. Ex. B at 1. He is board certified in neurology, vascular neurology, and spinal cord medicine. Resp. Ex. A at 2; Resp. Ex. B at 2. Throughout his career, Dr. Alexander has held teaching positions,

---

<sup>40</sup> Dr. Nahm explained that Petitioner's symptom onset was 19 or 26 days post-vaccination. Pet. Ex. 27 at 5 n.1, 15 n.2. Dr. Nahm opined that Dr. Perlman's record from October 16, 2017, 19 days post-vaccination, likely contained a documentation error, indicating neck pain on the left side, not the right. Id. Because of this, Dr. Nahm preferred to use the later-in-time record, dated October 23, 2017, when Petitioner saw Dr. Andrus and reported right trapezius and right arm pain. Id.; see Pet. Ex. 2 at 13. Additionally, Dr. Nahm opined that an onset of "19 or 26 days post-vaccination[] ha[d] no material bearing on the argument being presented." Pet. Ex. 27 at 15 n.2. In the parties' joint submission, Petitioner argued her symptom onset was October 23, 2017, or 26 days post-vaccination. Joint Submission at 2.

<sup>41</sup> Respondent submitted two expert reports from Dr. Alexander. Resp. Exs. A, C.

including the Associate Director of Residency Training at the University of California, Los Angeles, as well as hospital affiliations and positions. Resp. Ex. A at 1-2; Resp. Ex. B at 2-3. “[He] ha[s] seen patients with neurological injuries and illness[es] in a variety of settings, including community private practice, university based private practice, and in part-time and full-time academic medicine for over 30 years.” Resp. Ex. A at 4. Specific to this case, Dr. Alexander has “served on an electrodiagnosis panel at a local community hospital one day per week for 19 years[] performing EMG and [NCS],” has conducted EMG/NCS on his own patients, and “ha[s] [] performed and interpreted over a thousand studies of patients with or suspected of having peripheral neuropathies including cervical radiculopathies, brachial neuritis and injuries of the brachial plexus.” Id.

## **b. Opinion**

Dr. Alexander opined that “Petitioner ha[d] symptoms, signs, MRI abnormalities[,] and directly visualized surgical findings consistent with a diagnosis of cervical radiculopathy and cervical spondylitic disc disease during days 19 to day 60 following her [flu] vaccine.” Resp. Ex. A at 16. Petitioner then developed brachial neuritis four days after ACDF surgery, and 60 days post-flu vaccination. Id. at 15-16. He opined “[m]ore likely than not, the surgical procedure stimulated an immune attack on the long thoracic and suprascapular nerves, leading to winging of the scapula.” Id. at 16.

### **i. Althen Prong One**

Regarding Petitioner’s theory of molecular mimicry, Dr. Alexander explained that “[a] vaccination, specifically the [flu] vaccination, would have to induce a cross-reactive response with a host cell determinant that is involved in autoimmunity, and that determinant is currently unknown in [brachial neuritis].” Resp. Ex. A at 12. Citing Olstone,<sup>42</sup> he explained that

“[c]onsidering that [five to six] amino acids are needed to induce monoclonal antibody response, the disparate proteins or peptide epitopes [i]n the vaccine would need to be close enough in homology, between vaccine and self, to share enough amino acid determinants or conformational shapes but distant enough to be recognized as foreign by the immune system. And the homology must be with a host epitope having an important biological role.

Id. (citing Resp. Ex. A, Tab 3 at 3).

Dr. Alexander opined that Dr. Nahm failed to provide any specific evidence or such homology. Resp. Ex. A at 12, 16. Dr. Alexander maintained that molecular mimicry is an “unproven hypothesis with little or no actual specific scientific support that it is a biologic probability in this case.” Id. at 12. “Generally waving the wand of molecular mimicry over the interaction between vaccines and brachial neuritis is clearly not sufficient.” Id.

---

<sup>42</sup> M. B. A. Olstone, Molecular Mimicry, Microbial Infection and Autoimmune Disease: Evolution of the Concept, 296 *Current Topics Microbiology & Immunology* 1 (2005).

Next, Dr. Alexander disagreed with Dr. Nahm's assertion that immunologic mechanisms cause brachial neuritis due to the presence of T and B cells in the endoneurium of affected nerves and anti-PNM antibodies in the serum of patients with brachial neuritis. Resp. Ex. A at 10-11. He opined that such findings are non-specific and not causally related to the flu vaccine. Id. at 10. The same findings, according to Dr. Alexander, would be present in post-operative immunologic-mediated brachial neuritis. Id. (citing Pet. Ex. 29 at 3 (noting that one of "[t]he two leading theories regarding the etiology of postsurgical [brachial neuritis] include[s] . . . immune-mediated inflammation of the brachial plexus"))).

Dr. Alexander also took issue with Dr. Nahm's analogy argument that because PNM antibodies are found in GBS, they can be found in brachial neuritis. Resp. Ex. A at 11. Dr. Alexander found Dr. Nahm's cite to Koski et al. "contrast[ed] findings in GBS with lack of same findings in brachial [neuritis]." Id. (citing Pet. Ex. 35). Specifically, in Koski et al., the authors compared antibody levels in GBS patients to those of healthy controls, which were healthy lab workers, and disease controls, one of whom had brachial neuritis. Id. (citing Pet. Ex. 35 at 2-3). They found anti-PNM antibodies were elevated in GBS subjects over healthy controls and disease controls, including the disease control with brachial neuritis. Id. (citing Pet. Ex. 35 at 3, 3 fig.3). Thus, he found Dr. Nahm was not correct in opining that GBS patients have PNM antibodies that bind glycolipid and complement, "exactly those which have been shown to be present in the serum of those with brachial neuritis." Id. (quoting Pet. Ex. 27 at 15).

Further, Dr. Alexander stated that post-operative brachial neuritis is a well-recognized syndrome. Resp. Ex. A at 16; see Resp. Ex. A, Tab 1 at 2. "[T]here is a growing recognition that some perioperative nerve injuries arise from an inflammatory process." Resp. Ex. A, Tab 5 at 1; see also Resp. Ex. A, Tab 1 at 3. Dr. Alexander opined that "[m]ore likely than not, the surgical procedure stimulated an immune attack on the long thoracic and suprascapular nerves, leading to winging of the scapula." Resp. Ex. A at 16. Thus, he did not disagree that an immune-mediated process occurred, but disagreed as to the triggering agent. See Resp. Ex. A at 16.

Dr. Alexander discussed studies that examined both vaccination and surgery as triggers for brachial neuritis. Resp. Ex. A at 9-10, 13-14. As to vaccination, he noted that Dr. Nahm's reliance on Feinberg and Radecki was misplaced because they cited no evidence to support recent immunization as the second most common risk factor for brachial neuritis. Id. at 9 (citing Pet. Ex. 29 at 2). For support, Dr. Alexander cited Fibuch et al., the study Feinberg and Radecki relied upon. Id. at 9-10 (citing Resp. Ex. A, Tab 1). Fibuch et al. cited to several studies that examined brachial neuritis and antecedent events. Resp. Ex. A, Tab 1 at 3. In one study, 111 cases of brachial neuritis were reviewed. Id. The most common antecedent events were acute trauma (37 cases), recurrent trauma (21 cases), infection (16 cases), flu-like symptoms (13 cases), and idiopathic (18 cases). Id. Injections were noted as an antecedent event in 12 cases (10.8%) and surgery was an antecedent event in seven cases (6.3%). Id. Fibuch et al. also

discussed studies from Beghi et al.<sup>43</sup> and Malamut et al., described in more detail below. Id. at 2-3 (citing Resp. Ex. A, Tab 2; Resp. Ex. A, Tab 4).

Beghi et al. reviewed 579 Mayo Clinic records from 1970 through 1981 of Rochester, Minnesota residents and examined those records from patients with a diagnosis suggestive of brachial neuritis. Resp. Ex. A, Tab 2 at 1. Cases with a definite weakness due to peripheral nervous system damage that could be localized to the arm(s) with no signs of spinal cord, primary root, or symmetrical peripheral nerve involvement were included, and cases of specific brachial plexus damage (i.e., direct trauma, compression, or radiation) or those with a progressive course of symptoms were excluded. Id. Of the 579 records, 11 cases met all criteria.<sup>44</sup> Id. at 2. An antecedent event within five weeks of onset of brachial neuritis was present in six of the 11 cases: two cases followed infection, one followed a tetanus toxoid vaccination, and one followed both a tetanus toxoid vaccination and a flu-like illness. Id. at 1, 2 tbl.2, 3. “[N]one had received swine flu or other [flu] vaccines in the preceding [five] weeks.” Id. at 3.

The authors in Beghi et al. postulated an analogy between brachial neuritis and the brachial neuropathy of serum sickness, explaining that “[o]ne of the basic mechanisms operating in serum sickness, an immune complex disease, supports the assumption that [brachial neuritis] might also be an immune-mediated disease, even though there is no firm evidence to link it to an antigen-antibody response.” Resp. Ex. A, Tab 2 at 3. They found “this mechanism could explain the tendency toward a more widespread involvement of the peripheral nervous system by the disease and the relapses in cases . . . that have no evidence of hereditary disease.” Id. Additionally, the authors noted “[i]nfectious disorders and vaccinations have repeatedly been reported as preceding the onset of neurological diseases in which an inflammatory or immune mechanism is suspected,” but their role in the pathogenesis of brachial neuritis remains unclear. Id.

Additionally, in 1948, Parsonage and Turner<sup>45</sup> identified 136 patients with brachial neuritis, 98 of which had evidence of a precipitating factor prior to onset. Resp. Ex. A, Tab 7 at 1. Surgery was a precipitating cause in 12 of the 98 patients (12.2%), the second most common precipitating factor behind infection (72.4%). Id. Parsonage and Turner determined post-surgical brachial neuritis could not have been due to a mechanical cause because “there was always a clear interval between the operation and the first symptom.” Id. For the 12 post-surgical patients, the onset intervals ranged from three to 14 days. Id. at 1-2. Vaccination and

---

<sup>43</sup> Ettore Beghi et al., Brachial Plexus Neuropathy in the Population of Rochester, Minnesota, 1970-1981, 18 *Annals Neurology* 320 (1985).

<sup>44</sup> For a list of diagnoses and reasons cases did not meet criteria, see Resp. Ex. A, Tab 2 at 2 tbl.1. Four cases received a diagnosis of possible brachial neuritis because other conditions could not be excluded, and thus, these four cases were not included by the authors because they could not be diagnosed with definite brachial neuritis. Resp. Ex. A, Tab 2 at 1.

<sup>45</sup> M. J. Parsonage & J. W. Aldren Turner, Neuralgic Amyotrophy: The Shoulder-Girdle Syndrome, 1 *Lancet* 973 (1948).

inoculation history was obtained in 67 of the 136 patients, and 11 of the 67 patients (16.4%) received an inoculation in the four weeks prior to onset. Id. at 2. The vaccines included typhoid, anti-tetanus toxoid, diphtheria antitoxin, and anti-typhus. Id.

Malamut et al. discussed six patients who developed brachial neuritis within 13 days following surgery. Resp. Ex. A, Tab 4 at 1-4. None of the patients had risk factors for brachial neuritis or evidence of other conditions. Id. at 4. Although the etiology of brachial neuritis is unknown, the authors noted cases of brachial neuritis have been reported following vaccinations and surgery. Id. The authors acknowledged “[t]he explanation for the apparent inciting influence of surgery in the production of [brachial neuritis] is speculative,” but other autoimmune neuropathies, including GBS, have been reported post-operatively. Id. at 4. “[GBS] is a more generalized demyelinative condition whereas [brachial neuritis] is more focal and causes primary axonal degeneration.” Id. Malamut et al. concluded that brachial neuritis due to surgery “is an underrecognized clinical entity.” Id. at 5.

Dr. Alexander also cited to Klein et al., a study on patients with hereditary brachial neuritis<sup>46</sup> who underwent surgery and childbirth, known triggers of brachial neuritis, from 1996 through 2009. Resp. Ex. A, Tab 5 at 1. The authors identified 25 patients who underwent 48 surgeries or parturitions. Id. Seventeen of the 25 (68%) had a total of 20 attacks of brachial neuritis, 13 of which were post-surgical. Id. at 3. The median onset time was three days (range 0-30 days). Id. Six of the 13 occurred following surgery on the affected limb, although the authors found “[t]he locations of surgeries leading to their attacks varied widely, and no correlation was found with type of surgery or anesthetic.” Id. at 3, 5. Thus, they “suggest[ed] direct trauma [was] not the only trigger.” Id. at 5. The authors concluded “[hereditary brachial neuritis] attacks occurring after the physical stresses of surgery or childbirth appear comparable to other brachial neuritis attacks.” Id. at 6. They suggested “inflammation . . . as a component of the pathogenesis.” Id. at 1.

Lastly, Fibuch et al. described a case of a post-surgical brachial neuritis. Resp. Ex. A, Tab 1 at 1. Twelve hours after surgery, their patient reported acute burning pain in both shoulders that radiated into the neck and scapula. Id. at 2. The following morning, the patient developed weakness in the shoulder girdle and that afternoon, she noticed a tingling sensation that radiated down her arm into her fingers. Id. Four weeks after onset, she was evaluated and received an EMG/NCS and MRI of the brachial plexus and neck. Id. She was subsequently diagnosed with post-operative idiopathic brachial neuritis. Id. Fibuch et al. examined other studies on brachial neuritis<sup>47</sup> and concluded that “a strong link to an immune reactive phenomenon can be made,” but they acknowledged that the etiology of brachial neuritis following surgery and general anesthesia are unknown. Id. at 3.

---

<sup>46</sup> For more information on hereditary brachial neuritis, see Resp. Ex. A, Tab 5.

<sup>47</sup> See, e.g., Resp. Ex. A, Tabs 2, 4.

**ii. Althen Prongs Two & Three**

Dr. Alexander opined that Petitioner’s symptoms specific for brachial neuritis began on November 26, 2017,<sup>48</sup> four days after her ACDF surgery for cervical spondylosis<sup>49</sup> and cervical radiculopathy, when she developed winging of her scapula. Resp. Ex. A at 10, 13, 15-16. This places onset four days after surgery and 60 days post-flu vaccination. Id. at 10. He opined that this timing “make[s] [] a temporal association with the vaccine difficult and, more likely than not, undermines the theory of vaccine causality.” Id. Additionally, this time course is consistent with post-surgical brachial neuritis described in the medical literature. Id. at 12-16.

Regarding her clinical course, Dr. Alexander found Petitioner’s clinical course and symptoms pre-surgery were consistent with a cervical radiculopathy, not brachial neuritis. Resp. Ex. A at 12-16; Resp. Ex. C at 2-3. Before surgery, on October 26, 2017, at a visit with Dr. Perlman, her chiropractor, Petitioner reported pain in her neck that “sometimes travel[ed] down the shoulder blade and arm.” Resp. Ex. A at 6 (quoting Pet. Ex. 3 at 5). Dr. Alexander noted that prior to surgery, “neck pain [was] the primary and dominant symptom,” and the neck pain and radiating pain down the arm is “typical of” and “expected in cervical radiculopathy, not [brachial neuritis].” Id. at 6-7, 12. Additionally, neck pain is not a common symptom of brachial neuritis. Id. at 12-13 (citing Pet. Ex. 29 at 1-2).

Based on his review of Petitioner’s medical records, Dr. Alexander stated “[t]here is little doubt that [Petitioner] had cervical radiculopathy.” Resp. Ex. A at 15; see also Resp. Ex. C at 2. All of Petitioner’s treating physicians agreed Petitioner had a cervical radiculopathy until November 26, 2017, when she developed brachial neuritis. Resp. Ex. A at 16. Petitioner was first seen for a full examination post-vaccination on October 23, 2017 by orthopedist Dr. Andrus and was diagnosed with cervical radiculopathy. Id. at 7, 12 (citing Pet. Ex. 2 at 13-17). Petitioner’s October 30, 2017 MRI was “markedly abnormal,” revealing “significant cervical degenerative disc disease and spondylosis,” which Dr. Alexander found consistent with a diagnosis of cervical radiculopathy. Id. at 7 (citing Pet. Ex. 2 at 23-24).

On November 3, 2017, Petitioner received a cervical injection for her cervical radiculopathy. Resp. Ex. A at 15 (citing Pet. Ex. 12 at 131-32). This injection was noted to “help[] a little.” Resp. Ex. C at 2. Dr. Alexander found this to be expected given Petitioner’s significant root compression, which he opined necessitated surgery rather than conservative care for lasting improvement. Id.

Further, Dr. Alexander noted that Dr. Gitelman first examined Petitioner on November 11, 2017, and his findings correlated with Petitioner’s MRI findings. Resp. Ex. A at 15 (citing Pet. Ex. 12 at 136). Dr. Gitelman conducted Petitioner’s ACDF surgery on November 22, 2017,

---

<sup>48</sup> The undersigned does not address Dr. Alexander’s arguments that Petitioner had neck pain prior to vaccination as it is not relevant to the issues in this case.

<sup>49</sup> Spondylosis is “degenerative spinal changes due to osteoarthritis.” Spondylosis, Dorland’s Med. Dictionary Online, <https://www.dorlandsonline.com/dorland/definition?id=46749> (last visited Apr. 24, 2023).

and his findings during surgery were consistent with Petitioner's MRI, physical examinations, and diagnosis of cervical radiculopathy. Id. (citing Pet. Ex. 12 at 151).

Prior to surgery, no treating physician noted a relationship between Petitioner's pain and the flu vaccine. Resp. Ex. A at 16. Petitioner's treating physicians do not mention an association between vaccination and brachial neuritis until January 29, 2018, four months post-vaccination and two months post-surgery. Id. at 8 (citing Pet. Ex. 2 at 30).

Dr. Alexander also commented on Petitioner's EMG conducted January 25, 2018, two months after surgery. Resp. Ex. C at 1-2. He found that "[t]he EMG showing normal nerve root function is consistent with the 'excellent decompression' of the bilateral C6 nerves roots," which "innervates the biceps, and its compression likely accounts for the 'mild weakness' of the biceps seen pre-operatively by Dr. Gitelman." Id. at 2. And thus, he disagreed with "Dr. Nahm's opinion that the lack of EMG findings of radiculopathy two months after surgery discounts cervical radiculopathy as severe enough to cause pain or mild biceps weakness." Id. He found this opinion from Dr. Nahm contradicts the MRI evidence of severe stenosis as well as the findings of "'significant' foraminal stenosis and compression by direct visualization [during] surgery." Id.

Regarding causation, Dr. Alexander opined "[m]ore likely than not[,] the diagnosis of [brachial neuritis] is that of post-surgical activation of the immune system." Resp. Ex. A at 16. He noted "[s]urgery is a risk factor for [brachial neuritis]" and "[p]ost-surgical [brachial neuritis] is thought to be immune mediated." Id. Petitioner did not show symptoms consistent with brachial neuritis until four days after surgery (November 26, 2017), when she demonstrated winging of the scapula. Id. at 10, 13-16. Petitioner's four-day onset post-surgery is "a clinical scenario consistent with Feinberg [and Radecki] and Fibuch [et al.] and consistent with the development of [brachial neuritis] post-operatively." Id. at 10.

Feinberg and Radecki stated brachial neuritis can occur "within 24 h[ours] of the procedure or up to a week or more following surgery." Pet. Ex. 29 at 3. The case report from Fibuch et al. noted an onset of brachial neuritis 12 hours following surgery. Resp. Ex. A, Tab 1 at 1-2. Additionally, Malamut et al. discussed six patients who developed brachial neuritis within 13 days following surgery. Resp. Ex. A, Tab 4 at 1-4. In Klein et al., the median onset time post-surgery and childbirth was three days (range 0-30 days). Resp. Ex. A, Tab 5 at 3. In the 12 post-surgical patients described in Parsonage and Turner, the onset interval ranged from three to 14 days. Resp. Ex. A, Tab 7 at 1-2.

Lastly, Dr. Alexander disagreed with Dr. Nahm's contention that Petitioner had no pre-existing autoimmune condition that could explain her development of brachial neuritis. Resp. Ex. A at 14-15. He noted Petitioner's prior medical history, including auto-immune disease,<sup>50</sup> and found this history "may [] be a contributing factor" in her development of brachial neuritis "[g]iven the inflammatory nature of post-operative . . . brachial neuritis." Id.

---

<sup>50</sup> For example, Dr. Alexander noted prior autoimmune workups in 2009 and 2015, positive anti-nuclear antibodies in 2009, Reynaud's phenomenon since childhood, and a paralyzed vocal cord in 2016. Resp. Ex. A at 14-15.

He concluded Petitioner “ha[d] two diagnoses: cervical disc disease and radiculopathy prior to surgery, with the new development of brachial [neuritis] post-operatively that was related to the operation itself.” Resp. Ex. C at 3.

#### IV. DISCUSSION

##### A. Standards for Adjudication

The Vaccine Act was established to compensate vaccine-related injuries and deaths. § 10(a). “Congress designed the Vaccine Program to supplement the state law civil tort system as a simple, fair and expeditious means for compensating vaccine-related injured persons. The Program was established to award ‘vaccine-injured persons quickly, easily, and with certainty and generosity.’” Rooks v. Sec’y of Health & Hum. Servs., 35 Fed. Cl. 1, 7 (1996) (quoting H.R. Rep. No. 908 at 3, reprinted in 1986 U.S.C.C.A.N. at 6287, 6344).

Petitioner’s burden of proof is by a preponderance of the evidence. § 13(a)(1). The preponderance standard requires a petitioner to demonstrate that it is more likely than not that the vaccine at issue caused the injury. Moberly v. Sec’y of Health & Hum. Servs., 592 F.3d 1315, 1322 n.2 (Fed. Cir. 2010). Proof of medical certainty is not required. Bunting v. Sec’y of Health & Hum. Servs., 931 F.2d 867, 873 (Fed. Cir. 1991). Petitioner need not make a specific type of evidentiary showing, i.e., “epidemiologic studies, rechallenge, the presence of pathological markers or genetic predisposition, or general acceptance in the scientific or medical communities to establish a logical sequence of cause and effect.” Capizzano v. Sec’y of Health & Hum. Servs., 440 F.3d 1317, 1325 (Fed. Cir. 2006). Instead, Petitioner may satisfy her burden by presenting circumstantial evidence and reliable medical opinions. Id. at 1325-26.

In particular, Petitioner must prove that the vaccine was “not only [the] but-for cause of the injury but also a substantial factor in bringing about the injury.” Moberly, 592 F.3d at 1321 (quoting Shyface v. Sec’y of Health & Hum. Servs., 165 F.3d 1344, 1352-53 (Fed. Cir. 1999)); see also Pafford v. Sec’y of Health & Hum. Servs., 451 F.3d 1352, 1355 (Fed. Cir. 2006). The received vaccine, however, need not be the predominant cause of the injury. Shyface, 165 F.3d at 1351. A petitioner who satisfies this burden is entitled to compensation unless Respondent can prove, by a preponderance of the evidence, that the vaccinee’s injury is “due to factors unrelated to the administration of the vaccine.” § 13(a)(1)(B). However, if a petitioner fails to establish a prima facie case, the burden does not shift. Bradley v. Sec’y of Health & Hum. Servs., 991 F.2d 1570, 1575 (Fed. Cir. 1993).

“Regardless of whether the burden ever shifts to the [R]espondent, the special master may consider the evidence presented by the [R]espondent in determining whether the [P]etitioner has established a prima facie case.” Flores v. Sec’y of Health & Hum. Servs., 115 Fed. Cl. 157, 162-63 (2014); see also Stone v. Sec’y of Health & Hum. Servs., 676 F.3d 1373, 1379 (Fed. Cir. 2012) (“[E]vidence of other possible sources of injury can be relevant not only to the ‘factors unrelated’ defense, but also to whether a prima facie showing has been made that the vaccine was a substantial factor in causing the injury in question.”); de Bazan v. Sec’y of Health & Hum. Servs., 539 F.3d 1347, 1353 (Fed. Cir. 2008) (“The government, like any defendant, is permitted

to offer evidence to demonstrate the inadequacy of the [P]etitioner's evidence on a requisite element of the [P]etitioner's case-in-chief."); Pafford, 451 F.3d at 1358-59 ("[T]he presence of multiple potential causative agents makes it difficult to attribute 'but for' causation to the vaccination. . . . [T]he Special Master properly introduced the presence of the other unrelated contemporaneous events as just as likely to have been the triggering event as the vaccinations.").

## B. Factual Issues

A petitioner must prove, by a preponderance of the evidence, the factual circumstances surrounding her claim. § 13(a)(1)(A). To resolve factual issues, the special master must weigh the evidence presented, which may include contemporaneous medical records and testimony. See Burns v. Sec'y of Health & Hum. Servs., 3 F.3d 415, 417 (Fed. Cir. 1993) (explaining that a special master must decide what weight to give evidence including oral testimony and contemporaneous medical records). Contemporaneous medical records, "in general, warrant consideration as trustworthy evidence." Cucuras v. Sec'y of Health & Hum. Servs., 993 F.2d 1525, 1528 (Fed. Cir. 1993). But see Kirby v. Sec'y of Health & Hum. Servs., 997 F.3d 1378, 1382 (Fed. Cir. 2021) (rejecting the presumption that "medical records are accurate and complete as to all the patient's physical conditions"); Shapiro v. Sec'y of Health & Hum. Servs., 101 Fed. Cl. 532, 538 (2011) ("[T]he absence of a reference to a condition or circumstance is much less significant than a reference which negates the existence of the condition or circumstance." (quoting Murphy v. Sec'y of Health & Hum. Servs., 23 Cl. Ct. 726, 733 (1991), aff'd per curiam, 968 F.2d 1226 (Fed. Cir. 1992))), recons. den'd after remand, 105 Fed. Cl. 353 (2012), aff'd mem., 503 F. App'x 952 (Fed. Cir. 2013).

There are situations in which compelling testimony may be more persuasive than written records, such as where records are deemed to be incomplete or inaccurate. Campbell v. Sec'y of Health & Hum. Servs., 69 Fed. Cl. 775, 779 (2006) ("[L]ike any norm based upon common sense and experience, this rule should not be treated as an absolute and must yield where the factual predicates for its application are weak or lacking."); Lowrie v. Sec'y of Health & Hum. Servs., No. 03-1585V, 2005 WL 6117475, at \*19 (Fed. Cl. Spec. Mstr. Dec. 12, 2005) ("[W]ritten records which are, themselves, inconsistent, should be accorded less deference than those which are internally consistent." (quoting Murphy, 23 Cl. Ct. at 733)). Ultimately, a determination regarding a witness's credibility is needed when determining the weight that such testimony should be afforded. Andreu v. Sec'y of Health & Hum. Servs., 569 F.3d 1367, 1379 (Fed. Cir. 2009); Bradley, 991 F.2d at 1575.

Despite the weight afforded to medical records, special masters are not rigidly bound by those records in determining onset of a petitioner's symptoms. Valenzuela v. Sec'y of Health & Hum. Servs., No. 90-1002V, 1991 WL 182241, at \*3 (Fed. Cl. Spec. Mstr. Aug. 30, 1991); see also Eng v. Sec'y of Health & Hum. Servs., No. 90-1754V, 1994 WL 67704, at \*3 (Fed. Cl. Spec. Mstr. Feb. 18, 1994) (Section 13(b)(2) "must be construed so as to give effect also to § 13(b)(1) which directs the special master or court to consider the medical records (reports, diagnosis, conclusions, medical judgment, test reports, etc.), but does not require the special master or court to be bound by them").

### C. Causation

To receive compensation through the Program, a petitioner must prove either (1) that she suffered a “Table Injury”—i.e., an injury listed on the Vaccine Injury Table—corresponding to a vaccine that she received, or (2) that she suffered an injury that was actually caused by a vaccination. See §§ 11(c)(1), 13(a)(1)(A); Capizzano, 440 F.3d at 1319-20. Petitioner must show that the vaccine was “not only a but-for cause of the injury but also a substantial factor in bringing about the injury.” Moberly, 592 F.3d at 1321 (quoting Shyface, 165 F.3d at 1352-53).

Because Petitioner does not allege she suffered a Table Injury, she must prove a vaccine she received caused her injury. To do so, Petitioner must establish, by preponderant evidence: “(1) a medical theory causally connecting the vaccination and the injury; (2) a logical sequence of cause and effect showing that the vaccination was the reason for the injury; and (3) a showing of a proximate temporal relationship between vaccination and injury.” Althen, 418 F.3d at 1278.

The causation theory must relate to the injury alleged. Petitioner must provide a sound and reliable medical or scientific explanation that pertains specifically to this case, although the explanation need only be “legally probable, not medically or scientifically certain.” Knudsen v. Sec’y of Health & Hum. Servs., 35 F.3d. 543, 548-49 (Fed. Cir. 1994). Petitioner cannot establish entitlement to compensation based solely on her assertions; rather, a vaccine claim must be supported either by medical records or by the opinion of a medical doctor. § 13(a)(1). In determining whether a petitioner is entitled to compensation, the special master shall consider all material in the record, including “any . . . conclusion, [or] medical judgment . . . which is contained in the record regarding . . . causation.” § 13(b)(1)(A). The undersigned must weigh the submitted evidence and the testimony of the parties’ proffered experts and rule in Petitioner’s favor when the evidence weighs in her favor. See Moberly, 592 F.3d at 1325-26 (“Finders of fact are entitled—indeed, expected—to make determinations as to the reliability of the evidence presented to them and, if appropriate, as to the credibility of the persons presenting that evidence.”); Althen, 418 F.3d at 1280 (noting that “close calls” are resolved in Petitioner’s favor).

Testimony that merely expresses the possibility—not the probability—is insufficient, by itself, to substantiate a claim that such an injury occurred. See Waterman v. Sec’y of Health & Hum. Servs., 123 Fed. Cl. 564, 573-74 (2015) (denying Petitioner’s motion for review and noting that a possible causal link was not sufficient to meet the preponderance standard). The Federal Circuit has made clear that the mere possibility of a link between a vaccination and a petitioner’s injury is not sufficient to satisfy the preponderance standard. Moberly, 592 F.3d at 1322 (emphasizing that “proof of a ‘plausible’ or ‘possible’ causal link between the vaccine and the injury” does not equate to proof of causation by a preponderance of the evidence); Boatmon v. Sec’y of Health & Hum. Servs., 941 F.3d 1351, 1359-60 (Fed. Cir. 2019). While certainty is by no means required, a possible mechanism does not rise to the level of preponderance. Moberly, 592 F.3d at 1322; see also de Bazan, 539 F.3d at 1351.

## V. ANALYSIS

### A. Onset

While the parties agree that Petitioner's diagnosis is brachial neuritis, they dispute onset, and specifically, whether her brachial neuritis began post-vaccination or after her ACDF surgery. The parties agree that Petitioner did not have brachial neuritis before vaccination.

The medical literature filed by the parties establishes that brachial neuritis presents with an abrupt onset of shoulder pain, usually accompanied by weakness and other neurological deficits. The "best clue" to diagnosis is the presence of scapular winging, which occurs in most patients. Pet. Ex. 37 at 1. The following chronology shows when Petitioner began complaining of "shoulder pain,"<sup>51</sup> when her treating physician first documented weakness, and when scapular winging was first noted.

Petitioner received her flu vaccination on September 27, 2017. On October 16, 2017, she saw her chiropractor, Dr. Perlman. Dr. Perlman documented that Petitioner complained of neck pain that radiated into her upper back. He did not document weakness or the presence of scapular winging. Petitioner was seen by orthopedist Dr. Andrus on October 23, 2017. Petitioner complained of subjective weakness; however, Dr. Andrus documented that she had full (5/5) muscle strength bilaterally. Thus, there was no objective finding of weakness. Dr. Andrus did not document scapular winging. Petitioner returned to her chiropractor on October 26, 2017. There is no documentation of weakness or scapular winging at that visit. On November 11, 2017, Petitioner presented to Dr. Gitelman, who found no significant weakness. Scapular winging was not documented.

In the six-week period following vaccination, Petitioner saw her chiropractor, orthopedist, and surgeon. During this period, there was no documented finding of significant muscular weakness. Importantly, the presence of scapular winging was not documented. Therefore, the undersigned finds there is no evidence of objective muscular weakness or scapular winging after vaccination and prior to Petitioner's ACDF surgery.

On November 22, 2017, Petitioner underwent ACDF surgery at C4-5 and C5-6 by Dr. Gitelman. Postoperatively, on December 4, 2017, Petitioner saw Dr. Gitelman for follow-up. At that visit, Dr. Gitelman noted that Petitioner "developed more right shoulder pain" since her surgery. Pet. Ex. 4 at 52. At Petitioner's next visit with Dr. Gitelman on December 15, Dr. Gitelman documented that Petitioner "still ha[d] winging of the scapula." *Id.* at 60. This is the first time that scapular winging is documented.

Approximately one month later, on January 23, 2018, Dr. Gitelman documented that Petitioner had prominent winging of her scapula and limited mobility of her shoulder. Dr.

---

<sup>51</sup> Cervical radiculopathy can cause shoulder pain as well as neck pain. See Pet. Ex. 29 at 3; Pet. Ex. 37 at 3. For this reason, the undersigned focuses on weakness and scapular winging, two symptoms characteristic of brachial neuritis, to determine onset.

Gitelman questioned whether Petitioner's shoulder issues were caused by positioning during surgery. He also noted that Petitioner's symptoms began four days after surgery.

Two days later, on January 25, 2018, Petitioner had a neurology evaluation and EMG/NCS with Dr. Kranzler. Dr. Kranzler also documented that Petitioner's right scapular winging began four days after surgery. Dr. Kranzler's diagnosis was "right long thoracic and suprascapular neuropathies most likely . . . immune/inflammatory [] similar to brachial plexitis." Pet. Ex. 4 at 74.

On January 29, 2018, Dr. Gitelman wrote a letter stating Petitioner had a history of "[brachial neuritis], and developed right long thoracic nerve palsy. Neurologic evaluation showed that [this] [was] due to an inflammatory process. Vaccinations have been associated with such conditions. As such, [Dr. Gitelman] strongly recommend[ed] that [Petitioner] not undergo any vaccinations for the for[e]seeable future." Pet. Ex. 2 at 30. Dr. Gitelman, on February 7, 2018, completed a medical exemption form for the flu vaccine, writing Petitioner had brachial neuritis that was "still active." Id. at 31.

On February 5, 2018, Petitioner saw physical therapist Strittmatter, who documented that onset of injury, specifically "severe scapular winging and scapular pain/cervical pain," was December 1, 2017. Pet. Ex. 6 at 1. Strittmatter's physical examination documented severe scapular winging. Petitioner completed an information form at that visit stating that onset was December 1, 2017. Next, Petitioner saw Dr. Slate on February 26, 2018. Dr. Slate wrote that four days after surgery, Petitioner noted new onset scapular winging. Additionally, Dr. Slate documented that Petitioner had weakness and instability in her shoulder. Dr. Slate's impression was "likely [brachial neuritis] [status post] ACDF." Pet. Ex. 4 at 90. Petitioner saw her chiropractor on April 12, 2018. On examination, winged scapula was noted.

None of Petitioner's treating physicians associated her brachial neuritis to her vaccination. Dr. Gitelman wrote a letter stating Petitioner's brachial neuritis "[was] due to an inflammatory process," that "[v]accinations have been associated with such conditions," and "strongly recommend[ing] that [Petitioner] not undergo any vaccinations for the for[e]seeable future." Pet. Ex. 2 at 30. However, he did not opine as to actual causation of Petitioner's brachial neuritis.

In summary, after ACDF surgery, Petitioner's surgeon, two neurologists, and a chiropractor consistently documented the presence of Petitioner's winged scapula, which was reported as beginning either four days after surgery (November 26, 2017) or December 1, 2017. She was diagnosed with brachial neuritis. In his medical records, Dr. Gitelman suggested Petitioner's brachial neuritis could be due to positioning during surgery. Dr. Slate attributed Petitioner's brachial neuritis to surgery. None of Petitioner's treating physicians opined that her brachial neuritis was caused by her vaccination.

Based on the medical records and entries by Petitioner's treating providers, the undersigned finds that the onset of Petitioner's brachial neuritis was either four days after surgery (November 26, 2017) or December 1, 2017.

To the extent that Petitioner's statements are inconsistent with and/or contradicted by the health care providers' histories documented in the contemporaneous medical records, and objective physical examinations or diagnostic testing, the undersigned defers to the contemporaneous records as the most reliable source of information. See Cucuras, 993 F.2d at 1528 (noting that "the Supreme Court counsels that oral testimony in conflict with contemporaneous documentary evidence deserves little weight"); Doe/70 v. Sec'y of Health & Hum. Servs., 95 Fed. Cl. 598, 608 (2010); Stevens v. Sec'y of Health & Hum. Servs., No. 90-221V, 1990 WL 608693, at \*3 (Cl. Ct. Spec. Mstr. Dec. 21, 1990) (noting that "clear, cogent, and consistent testimony can overcome such missing or contradictory medical records"); Vergara v. Sec'y of Health & Hum. Servs., No. 08-882V, 2014 WL 2795491, at \*4 (Fed. Cl. Spec. Mstr. May 15, 2014) ("Special Masters frequently accord more weight to contemporaneously-recorded medical symptoms than those recorded in later medical histories, affidavits, or trial testimony."). Other special masters faced with similar situations have found contemporaneous medical records more persuasive than the affidavits and testimonies of lay witnesses. See, e.g., Rote v. Sec'y of Health & Hum. Servs., No. 90-036V, 1992 WL 165970, \*5 (Cl. Ct. Spec. Mstr. July 1, 1992) (finding the lay witness testimony insufficient to overcome the weight of the contemporaneous medical records); Bergman v. Sec'y of Health & Hum. Servs., No. 90-1252V, 1992 WL 78671, \*4 (Cl. Ct. Spec. Mstr. Mar. 31, 1992) (same); Daiza v. Sec'y of Health & Hum. Servs., No. 90-1188V, 1992 WL 59709, \*4 (Cl. Ct. Spec. Mstr. Mar. 5, 1992) (same).

#### A. Althen Prong One

Under Althen prong one, Petitioner must set forth a medical theory explaining how the received vaccine could have caused the sustained injury. Andreu, 569 F.3d at 1375; Pafford, 451 F.3d at 1355-56. Petitioner's theory of causation need not be medically or scientifically certain, but it must be informed by a "sound and reliable" medical or scientific explanation. Boatmon, 941 F.3d at 1359; see also Knudsen, 35 F.3d at 548; Veryzer v. Sec'y of Health & Hum. Servs., 98 Fed. Cl. 214, 223 (2011) (noting that special masters are bound by both § 13(b)(1) and Vaccine Rule 8(b)(1) to consider only evidence that is both "relevant" and "reliable"). If Petitioner relies upon a medical opinion to support her theory, the basis for the opinion and the reliability of that basis must be considered in the determination of how much weight to afford the offered opinion. See Broekelschen v. Sec'y of Health & Hum. Servs., 618 F.3d 1339, 1347 (Fed. Cir. 2010) ("The special master's decision often times is based on the credibility of the experts and the relative persuasiveness of their competing theories."); Perreira v. Sec'y of Health & Hum. Servs., 33 F.3d 1375, 1377 n.6 (Fed. Cir. 1994) (stating that an "expert opinion is no better than the soundness of the reasons supporting it" (citing Fehrs v. United States, 620 F.2d 255, 265 (Ct. Cl. 1980))).

Due to the facts and circumstances of this case, specifically that Petitioner underwent ACDF surgery prior to onset of her brachial neuritis, the undersigned's determination as to causation turns on an analysis of Althen prong two. Even assuming that Petitioner has proven by preponderant evidence a sound and reliable causal mechanism under Althen prong one, the undersigned finds Petitioner did not provide preponderant evidence of a logical sequence of cause and effect where Petitioner had cervical ACDF surgery prior to the onset of her brachial neuritis.

Thus, the undersigned turns her focus to Althen prong two. See Vaughan ex rel. A.H. v. Sec’y of Health & Hum. Servs., 107 Fed. Cl. 212, 221-22 (2012) (finding the special master’s failure to rule on Althen prong one not fatal to his decision because Althen prong two was fatal to Petitioner’s case); Hibbard v. Sec’y of Health & Hum. Servs., 698 F.3d 1355, 1364 (Fed. Cir. 2012) (“discern[ing] no error in the manner in which the special master chose to address the Althen [prongs]” when he focused on Althen prong two after “assuming the medical viability of [the] theory of causation”).

## **B. Althen Prong Two**

Under Althen prong two, Petitioner must prove by a preponderance of the evidence that there is a “logical sequence of cause and effect showing that the vaccination was the reason for the injury.” Capizzano, 440 F.3d at 1324 (quoting Althen, 418 F.3d at 1278). “Petitioner must show that the vaccine was the ‘but for’ cause of the harm . . . or in other words, that the vaccine was the ‘reason for the injury.’” Pafford, 451 F.3d at 1356 (internal citations omitted).

In evaluating whether this prong is satisfied, the opinions and views of the vaccinee’s treating physicians are entitled to some weight. Andreu, 569 F.3d at 1367; Capizzano, 440 F.3d at 1326 (“[M]edical records and medical opinion testimony are favored in vaccine cases, as treating physicians are likely to be in the best position to determine whether a ‘logical sequence of cause and effect show[s] that the vaccination was the reason for the injury.’” (quoting Althen, 418 F.3d at 1280)). Medical records are generally viewed as trustworthy evidence since they are created contemporaneously with the treatment of the vaccinee. Cucuras, 993 F.2d at 1528. Petitioner need not make a specific type of evidentiary showing, i.e., “epidemiologic studies, rechallenge, the presence of pathological markers or genetic predisposition, or general acceptance in the scientific or medical communities to establish a logical sequence of cause and effect.” Capizzano, 440 F.3d at 1325. Instead, Petitioner may satisfy her burden by presenting circumstantial evidence and reliable medical opinions. Id. at 1325-26.

With regard to the second Althen prong, the undersigned finds Petitioner failed to provide preponderant evidence to support a logical sequence of cause-and-effect showing her flu vaccine caused her brachial neuritis for the following reasons.

To summarize Petitioner’s clinical course, she received a flu vaccination on September 27, 2017. Following vaccination, she saw various providers complaining of severe pain. In October 2017, no provider documented objective weakness or scapular winging. In November 2017, Petitioner presented to Dr. Gitelman, whose examination did not reveal significant weakness or scapular winging. Overall, during the six-week period following vaccination, Petitioner saw various specialists (chiropractor, orthopedist, and surgeon) and none documented objective muscular weakness or scapular winging characteristic of brachial neuritis.

On November 22, 2017, Petitioner underwent ACDF surgery at C4-5 and C5-6 by Dr. Gitelman. On December 4, Dr. Gitelman documented “more right shoulder pain” since the surgery. Pet. Ex. 4 at 52. On Documenter 15, he documented scapular winging. On January 23, 2018, Dr. Gitelman noted Petitioner had prominent winging of her scapula and limited mobility of her shoulder. He indicated the scapular winging occurred four days following surgery. On

January 25, 2018, Dr. Kranzler also documented onset of scapular winging four days after surgery.

On February 5, 2018, at a physical therapy initial evaluation, Petitioner and her physical therapist Strittmatter both placed onset of Petitioner's "severe scapular winging and scapular pain/cervical pain" on December 1, 2017. Pet. Ex. 6 at 1. Strittmatter's examination revealed severe scapular winging. Dr. Slate, on February 26, 2018, noted Petitioner developed new onset scapular winging four days after surgery. Dr. Slate also documented that Petitioner had weakness and instability in her shoulder. Petitioner's winged scapula was also indicated by her chiropractor on April 12, 2018.

In summary, after ACDF surgery, Petitioner's surgeon, two neurologists, and a chiropractor consistently documented the presence of Petitioner's winged scapula, which was reported as beginning either four days after surgery (November 26, 2017) or on December 1, 2017. Thereafter, she was diagnosed with brachial neuritis.

Petitioner's treating physicians also questioned whether Petitioner's injury was due to surgery. On January 23, 2018, Petitioner's surgeon, Dr. Gitelman questioned whether Petitioner's shoulder issues were caused by positioning during surgery. On January 25, 2018, Dr. Kranzler's diagnosis was "right long thoracic and suprascapular neuropathies most likely . . . immune/inflammatory [] similar to brachial plexitis." Pet. Ex. 4 at 74. And on February 26, 2018, Dr. Slate's impression was "likely [brachial neuritis] [status post] ACDF." *Id.* at 90.

None of Petitioner's treating physicians opined that her brachial neuritis was caused by or related to her vaccination. Dr. Gitelman wrote a letter stating Petitioner's brachial neuritis "[was] due to an inflammatory process." Pet. Ex. 2 at 30. While Dr. Gitelman noted that vaccinations have been associated with brachial neuritis, he did not opine that Petitioner's brachial neuritis was caused by vaccination. *See id.*

The experts devoted considerable time to the issues of whether Petitioner's brachial neuritis onset was pre- or post-ACDF surgery, and if post-ACDF surgery, then whether the surgery was the cause of her brachial neuritis. The experts agree an immune-mediated process may have occurred, but disagree as to the trigger of such process.

Dr. Nahm opined that Petitioner's brachial neuritis was caused by her flu vaccination because he believes that Petitioner had a progressive clinical course. He suggests her weakness "may have been present at or before the time of the cervical surgery." Pet. Ex. 27 at 19. The medical records, however, do not document any objective weakness until after ACDF surgery.

Next, Dr. Nahm concedes there is no "clear documentation" of scapular winging prior to surgery. But he questions "the possibility" that Petitioner had proximal weakness prior to surgery. Pet. Ex. 27 at 18-19. He acknowledges that this opinion is "speculative." *Id.*

Overall, the undersigned finds that here, Petitioner's theories are unsupported and speculative and/or conclusory in nature. When evaluating whether petitioners have carried their burden of proof, special masters consistently reject "conclusory expert statements that are not

themselves backed up with reliable scientific support.” Kreizenbeck v. Sec’y of Health & Hum. Servs., No. 08-209V, 2018 WL 3679843, at \*31 (Fed. Cl. Spec. Mstr. June 22, 2018), mot. for rev. denied, decision aff’d, 141 Fed. Cl. 138 (2018), aff’d, 945 F.3d 1362 (Fed. Cir. 2020). The undersigned will not rely on “opinion evidence that is connected to existing data only by the ipse dixit of the expert.” Prokopeas v. Sec’y of Health & Hum. Servs., No. 04-1717V, 2019 WL 2509626, at \*19 (Fed. Cl. Spec. Mstr. May 24, 2019) (quoting Moberly, 592 F.3d at 1315). Instead, special masters are expected to carefully scrutinize the reliability of each expert report submitted. See id.

Additionally, opinions expressed as possibilities are not sufficient. See, e.g., LaCour v. Sec’y of Health & Hum. Servs., No. 90-316V, 1991 WL 66579, at \*5 (Fed. Cl. Spec. Mstr. Apr. 15, 1991) (“Expert medical testimony which merely expresses the possibility—not the probability—of the occurrence of a compensable injury is insufficient, by itself, to substantiate the claim that such an injury occurred.”); Moberly, 592 F.3d at 1322 (emphasizing that “proof of a ‘plausible’ or ‘possible’ causal link between the vaccine and the injury” does not equate to proof of causation by a preponderance of the evidence); Waterman, 123 Fed. Cl. at 573-74 (denying Petitioner’s motion for review and noting that a possible causal link was not sufficient to meet the preponderance standard); Boatmon, 941 F.3d at 1359-60.

On the other hand, Respondent’s expert Dr. Alexander opined that Petitioner’s brachial neuritis was caused by “post-surgical activation of the immune system.” Resp. Ex. A at 16. And he explained that surgery is a risk factor for brachial neuritis. Dr. Alexander also cited supportive medical literature for this opinion.

The undersigned is not persuaded by Petitioner’s arguments, given Petitioner’s clinical course, treating physician medical records, and the experts’ opinions and supporting medical literature. As explained above, the medical records do not document objective signs of brachial neuritis until after surgery. The undersigned acknowledges that Petitioner is not required to eliminate other potential causes in order to be entitled to compensation. See Walther v. Sec’y of Health & Hum. Servs., 485 F.3d 1146, 1149-52 (Fed. Cir. 2007) (finding Petitioner does not bear the burden of eliminating alternative independent potential causes). However, she finds it reasonable to consider “evidence of other possible sources of injury”—here, Petitioner’s ACDF surgery—in determining “whether a prima facie showing has been made that the vaccine was a substantial factor in causing the injury in question.” Stone, 676 F.3d at 1379.

Therefore, the undersigned finds that Petitioner has failed to satisfy her burden under Althen prong two.

### C. Althen Prong Three

Althen prong three requires Petitioner to establish a “proximate temporal relationship” between the vaccination and the injury alleged. Althen, 418 F.3d at 1281. That term has been defined as a “medically acceptable temporal relationship.” Id. Petitioner must offer “preponderant proof that the onset of symptoms occurred within a time frame for which, given the medical understanding of the disorder’s etiology, it is medically acceptable to infer causation-in-fact.” de Bazan, 539 F.3d at 1352. The explanation for what is a medically

acceptable time frame must also coincide with the theory of how the relevant vaccine can cause the injury alleged (under Althen prong one). Id.; Koehn v. Sec’y of Health & Hum. Servs., 773 F.3d 1239, 1243 (Fed. Cir. 2014); Shapiro, 101 Fed. Cl. at 542; see Pafford, 451 F.3d at 1358. A temporal relationship between a vaccine and an injury, standing alone, does not constitute preponderant evidence of vaccine causation. See, e.g., Veryzer, 100 Fed. Cl. at 356 (explaining that “a temporal relationship alone will not demonstrate the requisite causal link and that [P]etitioner must posit a medical theory causally connecting the vaccine and injury”), aff’d, 475 F. App’x 765 (Fed. Cir. 2012).

Petitioner received her flu vaccination on September 27, 2017. And on November 22, 2017, Petitioner underwent ACDF surgery. As noted above, the undersigned determined Petitioner’s onset of brachial neuritis occurred on either November 26, 2017 or December 1, 2017. This would place onset 60 or 65 days post-vaccination.

Both parties provided medical literature that supports an onset of brachial neuritis between a few days and up to six weeks, or 42 days, following flu vaccination.<sup>52</sup> Here, Petitioner’s onset was 60 or 65 days post-flu vaccination, which does not fit into the onset periods discussed in the medical literature filed.

For example, Dr. Nahm cited to the Vaccine Injury Table time frame for brachial neuritis after the tetanus toxoid vaccine (2-28 days) and for GBS post-flu vaccine (2-42 days) for support. The patient in Shaikh et al. developed pain a few days after flu vaccination and weakness within one week of flu vaccination. Similarly, the patient in Marks developed symptoms consistent brachial neuritis within six weeks, or 42 days, after the flu vaccine.

Additionally, special masters have not awarded compensation when onset is too remote from vaccination given the purported mechanism. See, e.g., Barone v. Sec’y of Health & Hum. Servs., No. 11-707V, 2014 WL 6834557, at \*8-13 (Fed. Cl. Spec. Mstr. Nov. 12, 2014) (finding a GBS onset of six weeks post-vaccination appropriate given the mechanism of molecular mimicry); Greene v. Sec’y of Health & Hum. Servs., No. 11-631V, 2019 WL 4072110, at \*16-21 (Fed. Cl. Spec. Mstr. Aug. 2, 2019) (explaining that an onset of 41 days is not medically appropriate in a brachial neuritis case); Garner v. Sec’y of Health & Hum. Servs., No. 15-063V, 2017 WL 1713184, at \*15-18 (Fed. Cl. Spec. Mstr. Mar. 24, 2017) (finding an onset of brachial neuritis 45 days post-vaccination not medically acceptable given the theory of molecular mimicry), mot. for rev. denied, 133 Fed. Cl. 140.

The undersigned finds Petitioner failed to provide preponderant evidence of Althen prong three. Even if Petitioner were to prevail on this prong, temporal association alone is insufficient for Petitioner to show vaccine causation. Moberly, 592 F.3d at 1323; Grant v. Sec’y of Health & Hum. Servs., 956 F.2d 1144, 1148 (Fed. Cir. 1992) (“[A] proximate temporal association alone does not suffice to show a causal link between the vaccination and the injury.”). Thus, Petitioner is not entitled to compensation.

---

<sup>52</sup> For post-surgical brachial neuritis cases, medical literature placed onset between 24 hours and two weeks.

**VI. CONCLUSION**

For the reasons discussed above, the undersigned finds that Petitioner has not established by preponderant evidence that her flu vaccination caused her brachial neuritis. Therefore, Petitioner is not entitled to compensation and her petition must be dismissed. In the absence of a timely filed motion for review pursuant to Vaccine Rule 23, the Clerk of Court **SHALL ENTER JUDGMENT** in accordance with this Decision.

**IT IS SO ORDERED.**

**s/Nora Beth Dorsey**

Nora Beth Dorsey  
Special Master