

# In the United States Court of Federal Claims

## OFFICE OF SPECIAL MASTERS

No. 18-457V

Filed: September 10, 2019

UNPUBLISHED

LAURA RUSSELL,

Petitioner,

v.

SECRETARY OF HEALTH AND  
HUMAN SERVICES,

Respondent.

Special Processing Unit (SPU);  
Findings of Fact; Onset and Site of  
Vaccination; Influenza (Flu) Vaccine;  
Shoulder Injury Related to Vaccine  
Administration (SIRVA)

*Amy A. Senerth, Muller Brazil, LLP, Dresher, PA, for petitioner.*

*Traci R. Patton, U.S. Department of Justice, Washington, DC, for respondent.*

### **FINDINGS OF FACT**<sup>1</sup>

**Dorsey**, Chief Special Master:

On March 28, 2018, petitioner filed a petition for compensation under the National Vaccine Injury Compensation Program, [42 U.S.C. §300aa-10](#), *et seq.*,<sup>2</sup> (the “Vaccine Act”). Petitioner alleges that she suffered “right shoulder injuries” as a result of an influenza (“flu”) vaccine administered on December 31, 2016. Petition at 1. The case was assigned to the Special Processing Unit of the Office of Special Masters.

For the reasons discussed below, the undersigned finds that petitioner was administered a flu vaccine on December 31, 2016 in her right arm and that the onset of

---

<sup>1</sup> The undersigned intends to post this ruling on the United States Court of Federal Claims' website. **This means the ruling will be available to anyone with access to the internet.** In accordance with Vaccine Rule 18(b), petitioner has 14 days to identify and move to redact medical or other information, the disclosure of which would constitute an unwarranted invasion of privacy. If, upon review, the undersigned agrees that the identified material fits within this definition, the undersigned will redact such material from public access. Because this unpublished ruling contains a reasoned explanation for the action in this case, undersigned is required to post it on the United States Court of Federal Claims' website in accordance with the E-Government Act of 2002. [44 U.S.C. § 3501](#) note (2012) (Federal Management and Promotion of Electronic Government Services).

<sup>2</sup> National Childhood Vaccine Injury Act of 1986, Pub. L. No. 99-660, [100 Stat. 3755](#). Hereinafter, for ease of citation, all “§” references to the Vaccine Act will be to the pertinent subparagraph of [42 U.S.C. § 300aa](#) (2012).

her shoulder symptoms occurred within 48 hours of vaccination. Specifically, petitioner suffered shoulder pain within 48 hours of vaccination.

### **I. Relevant Procedural History**

Following the initial status conference held on May 11, 2018, respondent was ordered to file a status report indicating how he intends to proceed in this case. [ECF No. 8](#). On February 11, 2019, respondent filed a status report confirming that he intends to defend this case and requesting a deadline for the filing of his Rule 4(c) Report. [ECF No. 19](#).

Respondent filed his Rule 4(c) Report (“Res. Report”) on March 22, 2019. [ECF No. 21](#). In his report, respondent argued that, although petitioner alleged that she received the December 31, 2016 flu vaccination in her injured right arm, her medical records indicate the flu vaccination was administered in her left arm. Res. Report at 5. Respondent further asserted that petitioner has not established all of the elements necessary for a shoulder injury related to vaccine administration (“SIRVA”) Table Injury, including onset of the shoulder injury within 48 hours of the vaccination. *Id.* at 5-7.

Thereafter, a scheduling order was issued ordering petitioner to file a motion for subpoena authority to obtain additional vaccination records from Rite Aid. [ECF No. 22](#). Petitioner filed vaccination records collected pursuant to subpoena on May 17, 2019. [ECF No. 25](#).

On May 31, 2019, a scheduling order was issued noting that the undersigned had reviewed respondent’s Rule 4(c) Report and the evidence filed to date in this case. [ECF No. 27](#). The undersigned stated that briefing and a hearing were not necessary to make findings of fact regarding the site of petitioner’s flu vaccination and the onset of her alleged injury. *Id.* The undersigned set a deadline for the parties to file any additional relevant evidence they wished to have considered regarding these issues. *Id.* No additional evidence was filed. This matter is now ripe for adjudication.

### **II. Issues**

There are two issues in this case: (1) whether petitioner was administered a flu vaccine on December 31, 2016 in her injured right arm, and (2) whether petitioner’s first symptom or manifestation of onset after vaccine administration was within 48 hours as set forth in the Vaccine Injury Table. [42 C.F.R. § 100.3\(a\) XIV.B. \(2017\)](#) (influenza vaccination). Additionally, the Qualifications and aids to interpretation (“QAI”) for a Table SIRVA also require that a petitioner’s pain occurs within 48 hours. [42 C.F.R. § 100.3\(c\)\(10\)](#).

### **III. Authority**

Pursuant to Vaccine Act § 13(a)(1)(A), a petitioner must prove, by a preponderance of the evidence, the matters required in the petition by Vaccine Act

§ 11(c)(1). A special master may find that the first symptom or manifestation of onset of an injury occurred “within the time period described in the Vaccine Injury Table even though the occurrence of such symptom or manifestation was not recorded or was incorrectly recorded as having occurred outside such period.” Vaccine Act § 13(b)(2). “Such a finding may be made only upon demonstration by a preponderance of the evidence that the onset [of the injury] . . . did in fact occur within the time period described in the Vaccine Injury Table.” *Id.*

A special master must consider, but is not bound by, any diagnosis, conclusion, judgment, test result, report, or summary concerning the nature, causation, and aggravation of petitioner’s injury or illness that is contained in a medical record. Vaccine Act § 13(b)(1). “Medical records, in general, warrant consideration as trustworthy evidence. The records contain information supplied to or by health professionals to facilitate diagnosis and treatment of medical conditions. With proper treatment hanging in the balance, accuracy has an extra premium. These records are also generally contemporaneous to the medical events.” *Curcuras v. Sec’y of Health & Human Servs.*, [993 F.2d 1525, 1528](#) (Fed. Cir. 1993).

Additionally, when determining the impact of the evidence presented, the special master should consider factors such as the reliability and consistency of the evidence. *See Burns v. Sec’y of Health & Human Servs.*, [3 F.3d 415, 416](#) (Fed. Cir. 1993). “Written records which are, themselves, inconsistent, should be accorded less deference than those which are internally consistent. If a record was prepared by a disinterested person who later acknowledged that the entry was incorrect in some respect, the later correction must be taken into account.” *Murphy v. Sec’y of Health & Human Servs.*, No. 90-882V, [1991 WL 74931](#), at \*4 (Fed. Cl. Spec. Mstr. Apr. 25, 1991), *mot. for rev. denied*, 23 Cl. Ct. 726 (1991), *aff’d per curium*, [968 F.2d 1226](#) (Fed. Cir. 1992).

#### **IV. Findings of Fact**

##### **a. Site of Vaccination**

The undersigned finds that the record in this case establishes that petitioner was administered a flu vaccination in her right arm on December 31, 2016. The undersigned makes the aforementioned finding after a complete review of the record, including all medical records, petitioner’s affidavit, and respondent’s Rule 4(c) Report.

Specifically, the undersigned bases the finding on the following evidence:

- The “Corp Pharmacy: Prescription Inquiry” and “Corp Pharmacy: Service Details” forms from Rite Aid document that a flu vaccine was administered intramuscularly in petitioner’s left upper arm on December 31, 2016. Petitioner’s Exhibits (“Pet. Exs.”) 1 at 2; 9 at 2. A “Screening Questionnaire and Consent Form” from Rite Aid reflects an entry of “LA,” or left arm, under the site of administration section for the December 31, 2016 flu vaccination. Pet. Ex. 9 at 4.

- On March 6, 2017, petitioner presented to Fusion Healthcare for a medical appointment following an emergency room admission on January 22, 2017.<sup>3</sup> Pet. Ex. 2 at 17. Petitioner reported that she had suffered a “reaction” to a flu vaccine administered on December 31, 2016 and had experienced right arm soreness since that time. *Id.* Petitioner specified that the flu vaccine was administered in her right arm. *Id.*
- A March 27, 2017 MRI of petitioner’s right shoulder revealed, in pertinent part, mild supraspinatus and infraspinatus tendinopathy; trace amount of joint fluid; and minimal degenerative changes of the acromioclavicular joint. Pet. Ex. 3 at 3. These imaging findings are suggestive of a SIRVA. See Court Exhibit I, attached (S. Atanasoff, et al., *Shoulder injury related to vaccine administration (SIRVA)*, 28 Vaccine 8049, 8051-52 (2010) (noting that shoulder MRI findings such as fluid collection, localized tendon inflammation, and bursitis may be consistent with over-penetration of the vaccine needle into the synovial space of the shoulder.)).
- On May 18, 2017, petitioner presented to Anderson Physical Therapy for an initial evaluation. Pet. Ex. 3 at 40. Petitioner noted that in “December 2016” she had received a flu vaccine in her “right side” and had experienced shoulder pain since that time. *Id.*
- On June 18, 2018, petitioner filed a detailed affidavit providing additional information regarding her December 31, 2016 flu vaccination. Pet. Ex. 8. At the time of the vaccination, petitioner recalled that she was sitting in a private room and had turned sideways to the left-facing wall while her right arm faced the vaccine administrator. *Id.* at ¶ 7. Petitioner confirmed that she was administered the flu vaccination in her right arm. *Id.*

#### **b. Onset**

Based upon the record as a whole, and specifically the evidence cited below, the undersigned finds that the onset of petitioner’s right shoulder pain occurred within 48 hours after the administration of the December 31, 2016 flu vaccine.

- As established above, petitioner received a flu vaccine in her right arm on December 31, 2016.
- On March 6, 2017, petitioner presented to Fusion Healthcare with complaints of “right shoulder/arm pain” following a December 31, 2016 flu vaccination. Pet. Ex. 2 at 17. Petitioner stated that she had been

---

<sup>3</sup> Petitioner presented to the emergency room on January 22, 2017 with complaints of sore throat and difficulty breathing. Pet. Ex. 4 at 5. Petitioner was discharged the same day in stable condition with diagnoses of acute pharyngitis and acute anxiety. *Id.* at 6-7.

experiencing soreness since receiving the flu vaccination and denied any previous injury or trauma. *Id.* On examination, petitioner presented with right shoulder tenderness to palpation, “very guarded” range of motion, inability to move her arm behind her back, and positive scarf and empty can testing. *Id.* at 18.

- On May 18, 2017, petitioner presented to Anderson Physical Therapy for an initial evaluation. Pet. Ex. 3 at 40. Petitioner noted that in “December 2016” she had received a flu vaccine in her “right side” and had experienced shoulder pain since that time. *Id.* A contemporaneous “Physical Therapy Evaluation and Treatment Plan” form linked the onset of petitioner’s shoulder condition to the flu vaccination and noted that her arm “never got better.” *Id.* at 47. On examination, petitioner presented with tightness, right shoulder tenderness to palpation, reduced range of motion, and reduced strength. *Id.* at 40.
- On June 18, 2018, petitioner filed a detailed affidavit providing additional information regarding her December 31, 2016 flu vaccination. Pet. Ex. 8. Petitioner noted that her right shoulder symptoms, including pain, began “immediately” following vaccination. *Id.* at ¶¶ 7, 9. Petitioner averred that her symptoms did not subside but instead grew worse over time. *Id.* at ¶¶ 8-9. Petitioner indicated that her injury limited her ability to perform activities of daily living. *Id.* at ¶¶ 9, 12. Petitioner averred that, although her symptoms have improved, she continues to suffer from right shoulder pain. *Id.* at ¶ 13.

## V. Conclusion

In light of all of the above and in view of the record as a whole, the undersigned finds that (1) petitioner was administered an influenza vaccine in her right arm on December 31, 2016, and (2) the onset of petitioner’s right shoulder symptoms, including pain, occurred within 48 hours of vaccination.

**The parties are encouraged to consider an informal resolution of this claim. Petitioner shall file a joint status report by no later than Friday, October 11, 2019, updating the court on the status of the parties’ settlement discussions.**

**IT IS SO ORDERED.**

**s/Nora Beth Dorsey**  
Nora Beth Dorsey  
Chief Special Master



Contents lists available at ScienceDirect

Vaccine

journal homepage: [www.elsevier.com/locate/vaccine](http://www.elsevier.com/locate/vaccine)

Short communication

Shoulder injury related to vaccine administration (SIRVA)<sup>☆</sup>S. Atanasoff<sup>a,\*</sup>, T. Ryan<sup>a</sup>, R. Lightfoot<sup>b</sup>, R. Johann-Liang<sup>a</sup><sup>a</sup> U.S. Department of Health and Human Services, Health Resources and Services Administration, National Vaccine Injury Compensation Program, United States<sup>b</sup> The Division of Rheumatology and Women's Health, University of Kentucky School of Medicine, United States

## ARTICLE INFO

## Article history:

Received 30 July 2010

Received in revised form 1 October 2010

Accepted 3 October 2010

Available online 16 October 2010

## Keywords:

Vaccination

Shoulder pain

Immune-mediated inflammatory reaction

Bursitis

Tendonitis

## ABSTRACT

Shoulder pain is a common transient side-effect of vaccination. Infrequently, patients can develop prolonged shoulder pain and dysfunction following vaccination. A series of 13 cases are described in which persistent shoulder dysfunction and pain developed following immunization. Common clinical characteristics include absence of a history of prior shoulder dysfunction, previous exposure to vaccine administered, rapid onset of pain, and limited range of motion. The proposed mechanism of injury is the unintentional injection of antigenic material into synovial tissues resulting in an immune-mediated inflammatory reaction. Careful consideration should be given to appropriate injection technique when administering intramuscular vaccinations to reduce the risk of shoulder injury.

Published by Elsevier Ltd.

## 1. Introduction

The Vaccine Injury Compensation Program (VICP) was created in 1988 to ensure an adequate supply of vaccines, stabilize vaccine costs, and establish and maintain an accessible and efficient forum for individuals found to be injured by certain vaccines. The VICP is a no-fault alternative to the traditional tort system for resolving vaccine injury claims and provides compensation to people found to be injured by specific covered vaccines [1]. At its inception, the vast majority of VICP cases involved evaluation of possible vaccine-related injuries in children. In recent years, however, the program's demographics have shifted dramatically with more than 50% of submitted cases now involving adults [2].

Thousands of vaccinations are administered to children, adolescents and adults every day in the United States with transient pain at the vaccine injection site recognized as one of the more commonly seen side-effects of vaccination [3]. The experience at VICP suggests that vaccination may infrequently cause more severe, persistent shoulder pain with prolonged restriction of function. This report summarizes a series of cases in which persistent shoulder pain following vaccination was felt to be related to administration of the vaccine, proposes a mechanism by which such injuries may occur, identifies common historical and physical examination

findings in patients with shoulder pain related to vaccine administration and offers considerations for reducing the risk of shoulder injury related to vaccine administration.

## 2. Materials and methods

The Vaccine Injury Compensation Program houses an administrative database containing information on recent claims submitted to the Program. A query of the database was conducted to identify potentially relevant cases based on a claimed injury of "shoulder pain," "arm pain," "shoulder dysfunction," "frozen shoulder," "adhesive capsulitis," or "shoulder bursitis." "Brachial neuritis" was also included since this injury is frequently claimed when the arm is involved regardless of the actual diagnosis. Case histories of all submitted medical records were reviewed in detail to verify vaccination date, symptom onset and clinical course.

Cases consistent with a diagnosis of brachial neuritis or complex regional pain syndrome were excluded, as were cases of superficial localized soft tissue swelling with pain and/or superficial scarring. Two cases claiming arm pain were excluded because the onset of arm pain was reported many months following vaccination and records lacked sufficient documentation to verify any association between the onset of symptoms and vaccination. Following the review, 13 potential cases submitted between 2006 and 2010 were identified for inclusion in this report.

A literature search was conducted using PubMed and search terms of "vaccination," with "shoulder," "shoulder dysfunction," "arm pain," "needle length," and "BMI." The literature search was limited to publications in English.

<sup>☆</sup> Several of the authors are employees of the United States Department of Health and Human Services. The positions expressed and recommendations made in this paper do not necessarily represent those of the United States Government.

\* Corresponding author. Tel.: +1 301 443 2377; fax: +1 301 443 5443.

E-mail addresses: [satanasoff@hrsa.gov](mailto:satanasoff@hrsa.gov), [tryan@hrsa.gov](mailto:tryan@hrsa.gov) (S. Atanasoff).

**Table 1**  
Clinical Characteristics of  $n = 13$  patients with shoulder injury related to vaccination.

Demographics: gender	11 Female (85%)	2 Male (15%)	
Demographics: age	Mean age: 50 years	Age range: 26–83	
Body habitus	BMI mean: 27.2	BMI range: 19.4–41.3	Overweight/Obese 8 (62%)
Vaccine	8 Influenza (62%)	2 Td (15%)	1 HPV (8%)
Repeat or sequential vaccination	Confirmed: 11 (85%)	Unconfirmed: 2 (15%)	
Onset of pain	Immediate: 7 (54%)	Within 24 h: 5 (39%)	Within 4 days: 1 (8%)
Comment in records	Vaccine injection “too high”: 6 (46%)		
Signs and symptoms	Shoulder pain (100%)	Limited ROM 11 (85%)	Altered sensation 4 (31%) Weakness 4 (31%)
Diagnostic tests	Local injection site reactions (0%)	reduced deep tendon reflexes (0%)	
	MRI	MRI performed 9 (69%)	Fluid collections in deep deltoid/overlying tendons, fluid in bursa, tendonitis, tears
	X-ray	X-ray performed 7 (54%)	No diagnostic benefit
	EMG/NCV	EMG/NCV 5 (39%)	No indication of neurological disorder such as brachial neuritis
	Surgical exploration	Surgical exploration 1 (8%)	path of vaccine administration replicated by inserting a needle into the deltoid, area contained an inflamed and scarred bursa/thickened tissue around a damaged tendon.
Treatment	NSAIDs: 8 (62%)	Steroid injection: 8 (62%)	Physical therapy: 6 (46%) Surgery: 4 (31%)
Clinical course	Full recovery: 4 (31%)	Residual symptoms 9 (69%)	

### 3. Results

In the course of reviewing claims submitted from 2006 through 2010, the VICP identified 13 claims in which it appeared that vaccine administration led to significant shoulder pain and dysfunction. The demographic and clinical characteristics of these 13 cases are shown in Table 1. All individuals in this case series were adults, 85% were women, and, with one exception, all received either influenza vaccine or a tetanus-containing vaccine prior to the onset of symptoms. The mean body mass index (BMI) of patients in the case series was 27.2 (range 19.4–41.3).

A history of prior immunization with the same vaccine was confirmed in 85% of the cases. Among patients in whom a history of previous vaccination was confirmed, the interval between vaccinations was no less than 10 years for those receiving tetanus-containing vaccines and no less than 11 months for influenza vaccine. One patient developed shoulder symptoms following administration of the third of a three dose series of human papillomavirus (HPV) vaccine which was administered three months following the second HPV vaccination.

#### 3.1. History and physical examination

Shoulder pain was present in all patients. Onset of pain was reported as occurring less than 24 h after vaccination in 93% and occurred immediately following injection in 54% of our cases. Forty-six percent of the patients voiced concerns regarding vaccine administration, specifically that the vaccination had been administered “too high” in the deltoid. The most common findings on examination were limited and painful range of motion. Skin and local injection site reactions were not reported and sensory symptoms such as tingling and numbness in the affected extremity were uncommon. Weakness was not a common finding in any of the cases during the initial examination and when found was attributed to pain. Deep tendon reflexes, when tested, were noted to be normal.

#### 3.2. Diagnostic evaluation

Among the 39% of patients who underwent electrodiagnostic studies, none had findings suggestive of a neurological disorder such as brachial neuritis. When performed, MRI findings varied but included fluid collections in the deep deltoid or overlying the rotator cuff tendons (39%), bursitis, fluid “greater than typically seen” within the bursa, tendonitis, rotator cuff tears, and, in one patient, subchondral changes in the humerus with overlying severe tendonitis and fluid accumulation. A complete rotator cuff tear was found in 15% of cases and, in one case, associated atrophy of the

rotator cuff tendon was noted. Sixty-three percent of the MRIs performed in our case series were conducted within three months of the date of symptom onset and half were performed within six weeks of symptom onset. Routine X-rays of the shoulder were performed less frequently and did not provide helpful diagnostic information among patients in this series.

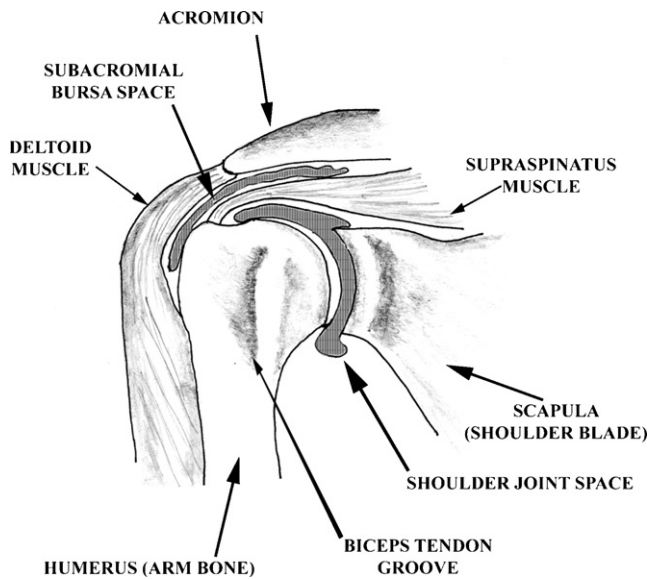
#### 3.3. Clinical course

The severity and duration of shoulder dysfunction varied among patients in this case series. More than half of the patients required at least one injection of a corticosteroid over time. Surgical intervention was performed in 31% of cases with half of those cases requiring a second surgical intervention. Review of the available records showed that shoulder symptoms persisted among our cases from six months to many years. All patients had symptoms for at least six months. Less than one third of patients had complete recovery while the majority of patients in this series had continuing symptoms including persistent pain, limited range of motion, and pain on range of motion at last follow-up.

### 4. Discussion

Bodor and Montalvo [4] reported two cases of shoulder pain, weakness, and reduced range of motion following vaccination with the onset of symptoms in both cases occurring two days after vaccination. Both patients had shoulder dysfunction and pain involving multiple structures of the shoulder with reduced range of shoulder motion. One patient developed adhesive capsulitis. Both required multiple steroid injections in locations including the subacromial bursa, bicipital tendon sheath and glenohumeral joint to reach complete resolution of pain. Using ultrasound the authors investigated the location and depth of the subdeltoid bursa in their two patients and in 21 healthy controls. They found that the bursa extended from 3.0 to 6.0 cm (1.18–2.36 in.) beyond the lateral border of the acromion and that it lay anywhere from 0.8 to 1.6 cm (0.31–0.62 in.) below the skin surface; depths easily reached by the 1 in. needle used in both patients. The authors hypothesized that the vaccine was injected into the subdeltoid bursa in both of their patients causing a robust local inflammatory and immune response. They further hypothesized that since the subdeltoid<sup>1</sup> bursa is contiguous with the subacromial bursa, this led to bursitis, tendonitis, and inflammation of the shoulder capsule. We found no other case reports

<sup>1</sup> For consistency and to reduce confusion, we will use the term “subacromial bursa” to refer to both the subdeltoid bursa and subacromial bursa in the remainder of the paper.



**Fig. 1.** Anatomy of the shoulder girdle. The relationships of the subdeltoid/subacromial bursa and shoulder joint space to the supraspinatus tendon and to the greater tuberosity on which it inserts.

or epidemiologic studies regarding shoulder dysfunction resulting from vaccination.

There have been several larger studies which utilized body weight, gender, and/or body mass index (BMI) together with ultrasound evaluation of deltoid fat pad and skin fold thickness to determine the appropriate needle length for intramuscular injection in different patient groups [5–7]. In one of the few studies addressing the risk of injecting into shoulder tissues underlying the deltoid muscle, Lippert and Wall [8] assessed the risk of over-penetration through the deltoid muscle in children ages 3–18 using the needle lengths recommended by the Centers for Disease Control. They reported a risk of over-penetration ranging from 11 to 61% when using the needle lengths recommended for each age group. We found no publications regarding the risk of over-penetration due to needle length in an adult population. However, considering the ultrasound measurement findings by Bodor and Montalvo, it is conceivable that a needle length of one inch or greater could reach the bursa or other tissues in some patients, particularly adults with a lower BMI (Fig. 1).

The act of inserting a needle or injecting a non-antigenic substance into the deltoid muscle would not be expected to cause an immune-mediated inflammatory response. Even when an individual is vaccinated in the deltoid muscle with a previously administered vaccine any local injection site reaction caused by vaccine antigen-antibody interaction is expected to be relatively brief and resolve as the antigen is cleared from the soft tissues over a period of several days. If, however, a vaccine is inadvertently injected into the synovial space of the shoulder (bursa or joint), pre-existing antibody in the synovial tissues, present as a result of earlier naturally occurring infection or vaccination, may lead to a more prolonged inflammatory response [9,10]. A study by Dumonde using rabbits demonstrated that antigen injected into the synovial space was bound to existing antibody in the connective tissues of the joint leading to formation of antigen-antibody complexes and acute inflammation which lasted for six weeks [11].

We took these publications into consideration as we analyzed our case series to determine whether the injuries could be caused by vaccine administration. Since it is usually not possible to attribute causation from a case series, we took Sir Austin Bradford Hill's proposed set of nine criteria or "viewpoints" into consideration in determining whether a causal relationship might

exist between vaccine administration and shoulder dysfunction in some cases [12]. The clinical details of the patients in this series together with the published research literature on this subject meet many of Hill's suggested criteria for a causal relationship including specificity, temporal association, biological plausibility, coherence, and experimental evidence. Of the patients in our series, none had a history of symptomatic shoulder problems prior to vaccination. They all received a vaccine to which they had previously been exposed. They all experienced the rapid onset of shoulder pain (range: immediate to four days) following vaccination. They all developed shoulder symptoms limited to the vaccinated shoulder. They all had symptoms and physical findings consistent with a local immune-mediated inflammatory musculoskeletal shoulder injury.

One of our cases provided additional evidence to support vaccine administration as a causal element in this type of injury. In this case, surgeons replicated the path of vaccine administration by inserting a needle into the deltoid area at the location identified by the patient as the injection site during reparative arthroscopic shoulder surgery. The path of the needle led through an area containing an inflamed and scarred bursa and thickened tissue around a damaged tendon. Beneath the tendon the needle came into contact with abnormally friable bone on the greater tuberosity of the humerus that gave way with pressure from the needle. We believe it is likely that this patient as well as the other patients in our series developed shoulder pain and dysfunction through the mechanism proposed by Bodor and demonstrated experimentally by Dumonde.

Although shoulder dysfunction due to mechanical or overuse injury is always a diagnostic consideration, the rapid onset of pain with limited range of motion following vaccination in our series of patients is consistent with a robust and prolonged immune response within already-sensitized shoulder structures following injection of antigenic substance into the subacromial bursa or the area around the rotator cuff tendon. We believe that this type of phenomenon is not due to a specific vaccine but results from injection of a vaccine antigen to which a person has previously been sensitized as a result of previous naturally occurring infection or past vaccination. This concept is consistent with the vaccines which were given in this case series, namely influenza and tetanus vaccines which are given repeatedly over time and HPV vaccine which is given as a series of injections. We confirmed that almost all of our cases had received at least one dose of the same vaccine in the past. The two cases for which prior vaccination could not be confirmed by the medical records included one case of influenza vaccine administration and one case involving administration of a tetanus-containing vaccine. It is likely that an adult patient would have received a prior tetanus-containing vaccination at some point in their lifetime. Although it is possible that an adult may receive a first-time influenza vaccine, it is unlikely that an adult would not have had exposure to influenza virus or an influenza infection in the past. The immune response to both vaccines and infections wanes over time and may explain some of the variation in severity and duration of symptoms in our case series.

In general, chronic shoulder pain with or without reduced shoulder joint function can be caused by a number of common conditions including impingement syndrome, rotator cuff tear, biceps tendonitis, osteoarthritis and adhesive capsulitis [13]. In many cases, these conditions may cause no symptoms until provoked by trauma or other events. Reilly et al. [14] reviewed a series of shoulder ultrasound and MRI studies obtained in asymptomatic persons past middle age and found partial or complete rotator cuff tears in 39% of those individuals. Therefore, some of the MRI findings in our case series, such as rotator cuff tears, may have been present prior to vaccination and became symptomatic as a result of vaccination-associated synovial inflammation. Other findings such as fluid collections, localized tendon inflammation, and bursitis are more

consistent with the vaccine needle over-penetration mechanism proposed here.

The fact that six patients in our case series reported vaccine administration “too high” in the shoulder indicates that in some of our cases the injury may have been the result of improper injection technique. Given that 62% of our cases were overweight or obese based upon BMI and that no case was considered underweight, needle length alone may not have been the cause of injection into tissues other than the deltoid. Bodor’s ultrasound findings revealed that the subacromial bursa can extend over 2.36 in. laterally from the acromion in some cases. Therefore, we agree with Bodor that avoiding the top third of the deltoid would help to reduce the risk of penetrating the bursa. In addition, while patients are often seated for vaccinations, the standing position of the provider administering the injection may also contribute to injecting inadvertently high into the deltoid. A seated patient may help to reduce the risk of injury during a syncopal episode, but an awareness of proper injection technique on the part of the vaccine administrator should also be emphasized. Thus, concurrent seating positions for both the administrator and the receiver may minimize the risk of the injection being “too high”. Additional considerations for possible future study would include the benefit of abducting the arm a few degrees laterally so that the bulk of the bursa is protected by the acromion process and possibly exploring alternate injection sites in patients with little shoulder muscle mass.

There is a notable absence of children in our case series despite the fact that they have exposure to a broad range of vaccine antigens in the first decade of life. A number of factors may explain their lack of representation in this case series. The thigh is the preferred site of vaccination in toddlers and infants thus eliminating the risk of shoulder injury in this group. In older children and adolescents, the subacromial bursa may not be as developed or as extensive as those in adults. Vaccine administration in older children may more commonly include techniques such as “bunching” of the subcutaneous and deltoid tissue prior to vaccination thus increasing the distance between the skin and subacromial bursa. Children, as a group, have a much lower likelihood of pre-existing asymptomatic shoulder injuries which might be aggravated as a result of an inflammatory reaction related to vaccination. Finally, annual influenza vaccination, the most common vaccine associated with shoulder injury in this series, may have been more selectively encouraged for children at higher risk for influenza-related complications in past years thus reducing the possibility of vaccine-related shoulder injury in children by chance alone.

Our study is limited by the absence of a control group to allow comparison of outcomes. Additionally, patients submitting petitions to the Vaccine Injury Compensation Program may not be representative of the general public, leading to the possibility of a reporting bias similar to that which might be seen with the Vaccine Adverse Event Reporting System (VAERS) [15]. The strength of our case series is that the medical records in VICP petitions are typically voluminous and comprehensive, allowing detailed analysis of each case. Thus, although there is no specific diagnostic test for shoulder dysfunction due to vaccine needle over-penetration, we are able to describe clinical qualifications and aids to diagnosis for this entity allowing identification of possible cases of shoulder injury related to vaccine administration (SIRVA).

## 5. Conclusions

The medical literature supports the possibility that a vaccine can be unintentionally injected into structures underlying the del-

toid muscle due to inappropriate needle length and/or injection technique [4–8]. The research literature supports the potential for inducing a prolonged immune-mediated inflammatory reaction if a vaccine antigen is injected into synovial tissue structures underlying the deltoid muscle [9–11].

Our clinical case series provides additional evidence supporting the report by Bodor and Montalvo [4] that vaccine administration in the upper third of the deltoid area can have long-lasting consequences unrelated to the specific vaccine administered. Commonalities of history and physical examination among patients in our case series may be helpful in identifying patients who may have developed shoulder pain and dysfunction as a result of inadvertent vaccination into the bursa or other tissues beneath the deltoid muscle.

Soft tissue atrophy including tendon atrophy or rupture is a recognized side effect of corticosteroid injection. In situations where recent vaccination is suspected as a possible cause of shoulder pain we suggest consideration of non-invasive imaging such as MRI or high resolution musculoskeletal ultrasonography, prior to steroid injection to define any pre-existing anatomic abnormalities. Non-invasive imaging might assume greater importance if symptoms persist and additional steroid injections are being considered.

The risk of vaccine administration-related shoulder injury may be reduced by giving careful consideration to appropriate needle length based on individual patient characteristics such as gender and body mass index. Care should be taken to insure that the needle is not inserted into the upper third of the deltoid muscle.

## References

- [1] For more information on the VICP go to <http://www.hrsa.gov/Vaccinecompensation/>.
- [2] Johann-Liang R. Institute of medicine project review of adverse events, [http://www.hrsa.gov/vaccinecompensation/Docs/Transcript\\_ACCV-6-5-09.pdf](http://www.hrsa.gov/vaccinecompensation/Docs/Transcript_ACCV-6-5-09.pdf), p. 82–94 [accessed 07.12.10].
- [3] Possible side-effects from vaccines, <http://www.cdc.gov/vaccines/vac-gen/side-effects.htm> [accessed 7.12.10].
- [4] Bodor M, Montalvo E. Vaccination-related shoulder dysfunction. *Vaccine* 2006;25(4):585–7.
- [5] Poland GA, Borrud A, Jacobson RM, McDermott K. Determination of deltoid fat pad thickness: implications for needle length in adult immunizations. *JAMA* 1997;277(21):1709–11.
- [6] Cook IF, Williamson M, Pond D. Definition of needle length required for intramuscular deltoid injection in elderly adults: an ultrasonographic study. *Vaccine* 2006;24(7):937–40.
- [7] Koster MP, Stellato N, Kohn N, Rubin LG. Needle length for immunization of early adolescents as determined by ultrasound. *Pediatrics* 2009;124(2):667–72.
- [8] Lippert WC, Wall EJ. Optimal intramuscular needle-penetration depth. *Pediatrics* 2008;122(30):e556–563.
- [9] Cooke TD, Jasin HE. The pathogenesis of chronic inflammation in experimental antigen-induced arthritis. I. The role of antigen on the local immune response. *Arthritis Rheum* 1972;15(4):327.
- [10] Cooke TD, Hurd ER, Ziff M, Jasin HE. The pathogenesis of chronic inflammation in experimental antigen-induced arthritis. II. Preferential localization of antigen-antibody complexes to collagenous tissues. *J Exp Med* 1972;135(2):323.
- [11] Dumonde DC, Glynn LE. The production of arthritis in rabbits by an immunological reaction to fibrin. *Brit J Exp Pathol* 1962;43:373.
- [12] Hill AB. The environment and disease: association or causation? *Proc R Soc Med* 1965;58:295–300.
- [13] Woodward T, Best T. The painful shoulder. Part II. Acute and chronic disorders. *Am Fam Physician* 2000;61:3000–291.
- [14] Reilly P, Macleod I, Macfarlane R, Windley J, Emery RJ. Dead men and radiologists don’t lie: a review of cadaveric and radiological studies of rotator cuff tear prevalence. *Ann R Coll Surg Engl* 2006;88(2):116–21.
- [15] The Main Limitations of VAERS Data. About the VAERS Program, <http://vaers.hhs.gov/about/index> [accessed 7.12.10].