

In the United States Court of Federal Claims

OFFICE OF SPECIAL MASTERS

No. 17-121V

Filed: September 8, 2022

\*\*\*\*\*
C.V.
Petitioner,
v.
SECRETARY OF HEALTH AND
HUMAN SERVICES,
Respondent.
\*\*\*\*\*

TO BE PUBLISHED

Decision on Entitlement; Tetanus
Diphtheria Acellular Pertussis (Tdap)
Vaccine; Sterile Abscess; Delayed-Type
Hypersensitivity Reaction; Frozen Shoulder

Amber Wilson, Wilson Science Law, Washington, DC, for Petitioner
Mallori Openchowski, U.S. Department of Justice, Washington, DC, for Respondent

DECISION ON ENTITLEMENT1

Oler, Special Master:

On January 27, 2017, C.V. ("Petitioner") filed a petition for compensation under the National Vaccine Injury Compensation Program, 42 U.S.C. § 300aa-10, et seq.2 (the "Vaccine Act" or "Program") alleging that she suffered from shoulder pain and numbness as a result of the tetanus, diphtheria, and pertussis (Tdap) vaccine she received on December 5, 2015. Pet. at 3. For the reasons discussed in this decision, although I find that Petitioner has articulated a sound and reliable theory under Althen prong one, I conclude that she has not demonstrated that the Tdap vaccine she received "did cause" her condition. Accordingly, her petition must be dismissed.

1 This Decision will be posted on the United States Court of Federal Claims' website, in accordance with the E-Government Act of 2002, 44 U.S.C. § 3501 (2012). This means the Decision will be available to anyone with access to the internet. As provided in 42 U.S.C. § 300aa-12(d)(4)(B), however, the parties may object to the Decision's inclusion of certain kinds of confidential information. To do so, each party may, within 14 days, request redaction "of any information furnished by that party: (1) that is a trade secret or commercial or financial in substance and is privileged or confidential; or (2) that includes medical files or similar files, the disclosure of which would constitute a clearly unwarranted invasion of privacy." Vaccine Rule 18(b). Otherwise, this Decision will be available to the public in its present form. Id.

2 National Childhood Vaccine Injury Act of 1986, Pub. L. No. 99-660, 100 Stat. 3755. Hereinafter, for ease of citation, all "§" references to the Vaccine Act will be to the pertinent subparagraph of 42 U.S.C. § 300aa (2012).

## I. Procedural History

Petitioner filed a petition on January 27, 2017, alleging she suffers from a frozen shoulder as a result of the tetanus, diphtheria, and pertussis (“Tdap”) vaccination she received on December 5, 2015. Pet. at 1, 4.

Petitioner filed medical records and a statement of completion on February 17, 2017. ECF Nos. 6, 7. Respondent filed a Rule 4(c) Report on August 30, 2017, recommending that compensation be denied. Resp’t’s Rep., ECF No. 16.

On March 13, 2018, I held a Rule 5 Conference. During this conference, I indicated that Petitioner’s alleged injury was unclear, and noted some discrepancies between her affidavits and the medical records. *See* Scheduling Order dated March 15, 2018, ECF No. 24. I gave the parties 30 days to file a status report indicating how they would like to proceed. *See id.* On May 30, 2018, Petitioner filed a status report indicated she wished to file an expert report. ECF No. 31.

On September 19, 2018, Petitioner filed an expert report from Dr. Aton Holzer. Ex. 12. Petitioner filed additional medical records on November 9, 2018 and January 17, 2019. ECF Nos. 38, 40.

On May 30, 2019, Respondent filed expert reports from Drs. Markus Boos and David Ring. Exs. A, C. The parties briefly engaged in informal settlement negotiations from August-November 2019. I held a status conference on November 7, 2019, where Respondent indicated he wished to proceed on a litigation track. *See* Scheduling Order dated November 7, 2019, ECF No. 47.

On December 9, 2019, I issued an order with additional questions for Dr. Holzer. ECF No. 49. Petitioner filed a supplemental report from Dr. Holzer on March 11, 2020. Ex. 27.

On May 6, 2020, I held a status conference with the parties. *See* Scheduling Order dated May 7, 2020, ECF No. 56. Based on the expert reports that had been filed up to that date which discussed a lump that moved around at or near the vaccine injection site, I requested C.V. file a supplemental affidavit describing the lump at her injection site with more specificity. *See id.* Petitioner filed the affidavit on June 8, 2020. Ex. 32.

On July 17, 2020, I held another status conference with the parties and informed them that I had additional questions for the experts.<sup>3</sup> *See* Scheduling Order date July 20, 2020, ECF No. 58. The parties filed those expert reports on October 1, 2020. Exs. M, 33. The parties also indicated they believed they had no additional evidence to file and requested a briefing schedule. ECF No. 63.

---

<sup>3</sup> During the status conference, I informed the parties that I was inclined to find that a subcutaneous nodule existed in Petitioner’s arm following vaccination. For the reasons discussed in this decision, I have ultimately concluded that Petitioner has not presented preponderant evidence supporting the existence of a subcutaneous nodule at the injection site.

Petitioner filed a motion for a ruling on the record on February 1, 2021. ECF No. 65. On May 7, 2021, Respondent filed a response brief. ECF No. 68. Petitioner filed a reply brief on June 7, 2021. ECF No. 70. This matter is now ripe for an adjudication.

## **II. Fact Evidence**

### **A. Petitioner's First Affidavit**

Petitioner filed her first affidavit on February 17, 2017. Ex. 6. She stated that for two weeks after she received the Tdap vaccine on December 5, 2015, she experienced pain and redness at the injection site. *Id.* at 1. Approximately three weeks after vaccination, Petitioner stated she was still experiencing pain and that a lump had formed “under the skin near the injection site.” *Id.* Over the next week, the pain and swelling increased substantially. *Id.* Petitioner was simultaneously recovering from shingles and was expending time and resources on recovering and was not focused on her shoulder issues. *Id.*

Over the next few months, Petitioner averred that her arm and shoulder pain kept increasing, to the point that she could no longer raise or extend her arm; she was feeling a pins and needles sensation from her shoulder to her hand. Ex. 6 at 1. Petitioner stated that by March 2016, there was a golf ball sized lump at the injection site. *Id.* She emailed her primary care provider (PCP) on April 29, 2016 about vaccine related injuries. *Id.* at 2.

In early May 2016, Petitioner described that she was pulling a baking dish out of the oven when she lost feeling in her left hand and she nearly dropped the dish; she caught it with her right hand and suffered a burn. Ex. 6 at 2. Petitioner made an appointment for May 10, 2016. During this appointment, the inflation of a blood pressure cuff on her left arm caused her excruciating pain. *Id.* She returned on May 17, 2016 for her arm pain, which continued to worsen. *Id.*

On September 29, 2016, Petitioner saw a neurologist who diagnosed her with a frozen shoulder. Ex. 6 at 2. The neurologist suggested that Petitioner schedule an MRI and undergo physical therapy. Petitioner indicated she could not afford these therapies. *Id.*

By November 2016, Petitioner began experiencing some improvements; she was able to lift her arm and the pain was more intermittent. Ex. 6 at 2.

### **B. Petitioner's Supplemental Affidavit**

Petitioner filed a supplemental affidavit on June 8, 2020 pursuant to my request. Ex. 32. Petitioner clarified that the lump did not disappear or move and was always located near the vaccine injection site. *Id.* The lump grew and “felt like having a small, round ball between the muscle and the skin. You could tell that the lump was not attached to my arm bone or muscle, but it was located and growing in only one specific location on my arm under the skin.” *Id.*

### **C. Affidavit of R.V.**

R.V. filed an affidavit in support of his wife's claim. Ex. 7. R.V. stated that Petitioner did

not initially believe the December 2015 Tdap vaccination was the cause of her condition. *Id.* at 1. However, she began experiencing increasing pain over time that would lead her to wake up crying from pain. *Id.* Petitioner was not able to find a position she could sleep in and was in extreme pain when she bumped her left arm into objects. *Id.* R.V. further stated that Petitioner was unable to perform simple tasks, like turn on a light switch, and has experienced difficulty navigating her own home. *Id.*

#### **D. Petitioner's Correspondence with NorthShore Medical Group**

NorthShore Medical Group maintained documentation of messages that patients send to their doctors. These communications have been filed as exhibit 10.

On April 29, 2016, Petitioner messaged her PCP, Dr. Han, asking for the name and contact information of the manufacturer of her December 5, 2015 Tdap vaccination. Ex. 10 at 1.

On May 11, 2016, Petitioner sent Dr. Han a message about her appointment the prior day. Ex. 10 at 2, 4. Petitioner noted that a technician had used the wrong size blood pressure cuff, which caused her excruciating pain. *Id.* at 2. Her blood pressure was noted to be high at the beginning of the appointment but at the end of the reading, the technician returned with a larger cuff, which inflated five times and produced erroneous readings. *Id.* On the fifth attempt, Petitioner reported that her arm turned a reddish/blue color and she was in tears because of the pain. *Id.* Petitioner described that she had “two long red bruises on her arm and more pain than before because of her negligence. If [the technician] would have listened and fetched a larger cuff at the beginning of the appointment, I wouldn't be sitting here with new injuries to the arm... It may sound insignificant but I live with constant pain in that arm.” *Id.* Notably, Petitioner did not mention a lump in her arm or that the blood pressure cuff caused a lump in her arm to burst, merely that she experienced pain.

On May 15, 2016, Petitioner sent another message to Dr. Han mentioning she had booked an appointment for Tuesday evening (May 17, 2016). She stated “I need to discuss the vaccine injury further as I am going to pursue this. I'll need documentation.” Ex. 10 at 4.

On May 18, 2016, Petitioner again messaged Dr. Han. She wrote, “As per our conversation last night, the secured fax number is 877-652-5042. Please fax to the attention of Brittany Shalla... They just need the medical records pertaining to the left arm where I received the tetanus vaccination, mainly the first time I came to see you about it and any subsequent visits and any diagnosis.” Ex. 10 at 7.

On May 25, 2016, Petitioner followed up with Dr. Han, stating “The attorney's office says they didn't receive any documentation from you. As per previous request, sent on 5/18, the fax # is 877-652-5042, attn: Brittany Shalla. The arm is worse than ever. I was up the night before last with intense pain. Last night the pain was radiating up to the shoulder and down to the wrist. I don't feel like I should have to pay for P.T., this isn't my fault. The vaccine co should.” Ex. 10 at 8.

On June 11, 2016, Petitioner sent the following message to Dr. Han: “Please update the medical records to include my allergic reaction to the tetanus vaccine.” Ex. 10 at 10. Dr. Han confirmed, “It has been updated” that same day. *Id.*

### **III. Medical Records**

#### **A. Relevant Pre-Vaccination History**

Petitioner has a significant medical history which includes type 2 diabetes, hypertension, anxiety, obesity, asthma, herpes zoster ophthalmicus, herpes zoster uveitis, hypercholesteremia, knee pain, and a heart murmur. Ex. 2 at 3, 118-21. Petitioner was also a two-pack/day cigarette smoker for approximately ten years, and quit around 2000. *Id.* at 118.

Petitioner received a Tdap vaccine in her left deltoid on December 5, 2015; she was 58 years old at the time of vaccination. Ex. 2 at 3, 111; Ex. 24 at 5.

#### **B. Post-Vaccination History**

On December 12, 2015, Petitioner visited Kaya Cuper for a follow-up regarding her herpes uveitis. Ex. 5 at 42-48. A review of symptoms noted that Petitioner was experiencing pain and redness, but she did not report blurred vision, double vision, photophobia, or discharge. *Id.* at 45. Petitioner was prescribed over-the-counter eye drops to help with superficial keratitis in her right eye, especially before computer use, reading, and driving. *Id.* at 45, 48.

On March 14, 2016, Petitioner saw Dr. Andrea Honigsblum at the NorthShore Eye and Vision Center for a three-month uveitis follow-up. Ex. 5 at 49-55. Petitioner reported pain and occasional redness but no blurry vision or floaters. *Id.* at 52. Dr. Honigsblum encouraged Petitioner to follow up in three months for her herpes zoster uveitis and to receive another dilated eye exam for her diabetes. *Id.* at 54.

On May 10, 2016, Petitioner presented to Dr. Jini Han, her PCP, to follow up on her type 2 diabetes and to discuss dysphagia. Ex. 2 at 123. Petitioner reported that she was struggling with the costs of her medication and was not taking insulin consistently. *Id.* at 129. Petitioner also reported that her zoster uveitis and associated eye pain continued and she was experiencing some difficulty swallowing her medications. *Id.* She chewed things carefully and had no issue with food; she had no GERD symptoms, and did not experience choking, coughing, or regurgitation. *Id.* Petitioner had her blood drawn for a metabolic panel. *Id.* at 126. Her bloodwork was normal with the exception of her glucose level (high), chloride level (low), and hemoglobin A1C level (high). *Id.* at 126-27. Petitioner’s physical exam was normal. *Id.* at 130.

On May 17, 2016, Petitioner returned to Dr. Han for “left arm pain.” Ex. 2 at 137-41. Dr. Han noted that Petitioner received the Tdap vaccine in her left upper arm and did not experience severe pain during injection. *Id.* at 137. The medical records document the following:

Subsequently, developed swelling at site of injection, no obvious redness. Resolved after a couple weeks. Then the pain and a ping pong sized knot at site of the

injection recurred. Has persisted since and bothers her a lot. Recently had BP taken in the left arm and this has exacerbated her arm pain. The prior swelling in the arm reportedly “popped” due to the BP cuff pressure and is not [sic] longer present although the pain is worse. Sharp grabbing pain in upper arm made worse with lifting the arm, grabbing things with the arm. Sometimes loses feeling in the arm or hand transiently. Has to be careful when lifting things, cooking. Keeps her left arm close to her body for fear it will “give out” when holding things. Denies pain in the shoulder joint. States she never had this pain prior to the injection. Denies injury to the left arm to account for these sx. Pain can wake her from sleep esp with turning in bed.

*Id.*

On September 29, 2016, Petitioner visited Dr. Jesse Taber, a neurologist. Ex. 3 at 10-16. Dr. Taber noted Petitioner’s medical issues as: left frozen shoulder syndrome, multifactorial gait disorder, diabetic polyneuropathy associated with type 2 diabetes mellitus, orthostatic hypotension, hypersomnia, post herpetic neuralgia, and chronic daily headaches. *Id.* at 10-24. Under allergies, acetaminophen-codeine was noted to cause stomach pain in 2013 and Adacel caused severe arm pain (entered on June 11, 2016). *Id.* at 11.

Dr. Taber wrote a letter to Dr. Han summarizing the visit and his plan for treatment. Ex. 3 at 19-24. Dr. Taber recounted that Petitioner told him she had experienced a “vaccine injury” in December 2015 and she had persistent soreness in her left deltoid. *Id.* at 19. C.V. also told Dr. Taber that she developed a “lump the size of a golf ball which moved around for about six months but she reports that in June you applied an automatic blood pressure cuff which inflated five or six times and the lump ‘busted’”. *Id.* Petitioner noted that her hand lost strength a few times in May and that she was experiencing pain and limited range of motion in left shoulder abduction. *Id.* Petitioner was unable to go to physical therapy due to the cost but had been performing home exercises recommended by Dr. Han. *Id.*

Dr. Taber also noted other symptoms unrelated to her left arm and shoulder. Petitioner reported that her balance was worse than before and that she had headaches daily that affect the right side of her face and head, that began when she had a shingles infection. *Id.* at 19-20. Petitioner also described intermittent vertigo and lightheadedness when she stands too quickly. *Id.* at 20.

Dr. Taber’s physical exam revealed some give away strength in the left arm (4/5 strength in certain areas), abduction of the left shoulder to 135 degrees. He noted that Petitioner had a left frozen shoulder, and indicated that the paresthesias could be the result of an underlying cervical radiculopathy. Ex. 3 at 23-24. Dr. Taber recommended Petitioner undergo physical therapy for her left shoulder, gait, and balance issues. *Id.* at 24. Dr. Taber also recommended a CT scan or MRI to look for a pinched nerve. *Id.* Dr. Taber recommended duloxetine<sup>4</sup> for her shoulder and face pain but stated she needed to be in better control of her blood pressure before taking the medication. *Id.*

---

<sup>4</sup> Duloxetine hydrochloride: a serotonin-norepinephrine reuptake inhibitor, used for the treatment of major depressive disorder and the relief of pain in diabetic neuropathy; administered orally. Dorland’s Online

No other medical records pertinent to my determination have been filed.

#### **IV. Expert Opinions and Qualifications**

##### **A. Petitioner's Expert, Dr. Aton Holzer**

###### 1. Qualifications

Dr. Holzer received his medical training at Weill Medical College of Cornell University. Ex. 13 at 1 (hereinafter "Holzer CV"). He completed an internship in internal medicine at the Columbia-Presbyterian Medical Center. Holzer CV at 1. Dr. Holzer then completed his residency in dermatology at the University of Alabama, Birmingham, followed by a fellowship in procedural dermatology at The Methodist Hospital in Houston, Texas. *Id.* Dr. Holzer serves as the Director of Mohs Surgery at Tel Aviv Sourasky Medical Center in Tel Aviv, Israel as well as an independent contractor for Mohs Surgery at Dermatology Consultants of Broward in Pembroke Pines, Florida. From 2011 through 2015, Dr. Holzer practiced at Skin and Cancer Associates in South Miami, Florida. *Id.* Dr. Holzer is board certified in dermatology. *Id.* He has published 16 peer-reviewed papers and has given numerous presentations in his field. *Id.* at 2.

###### 2. Expert Reports

Dr. Holzer filed three reports in this case. Exs. 12 (hereinafter "First Holzer Rep."), 27 (hereinafter "Second Holzer Rep."), and 33 (hereinafter "Holzer Response to Questions").

In his first expert report, Dr. Holzer theorized that the administration of the Tdap vaccine caused Petitioner to develop a delayed-type hypersensitivity reaction causing the growth of a subcutaneous nodule which developed into a sterile abscess at the injection site. First Holzer Rep. at 5. Dr. Holzer explained that a subcutaneous nodule is a common adverse event at the injection site following immunization, and that these nodules are characterized as "firm papules or lesions that extend into the dermis or subcutaneous tissue." *Id.* The Brighton Collaboration developed diagnostic criteria for subcutaneous nodules following immunization. *Id.* at 3. (citing Rothstein, 2004).<sup>5</sup>

---

Med. Dictionary, <https://www.dorlandsonline.com/dorland/definition?id=15011> (last accessed Aug. 31, 2022).

<sup>5</sup> Level 1 Diagnostic Certainty Criteria for Subcutaneous Nodules include:

1. The presence of a well-demarcated soft tissue mass or lump THAT IS
  2. Firm AND
  3. Is at the injection site (in subcutaneous tissue, fat, fascia, or muscle).
- AND the following should not appear:
1. Abscess formation AND
  2. Erythema AND
  3. Warmth.

Dr. Holzer also explained that sterile abscesses are another, less common, type of adverse reaction to immunization at the injection site. *Id.* at 4. A sterile abscess is an enclosed mass of “liquefied fat and muscle resulting from necrosis of the surrounding tissue.” *Id.* Sterile abscesses are thought to form due to a hypersensitivity to non-infectious foreign material, such as a vaccine. *Id.* The Brighton Collaboration developed diagnostic criteria for sterile abscesses as well.<sup>6</sup> *Id.*

Dr. Holzer noted that one of the theories in the medical literature is that the aluminum adjuvants in the Tdap vaccine (and other vaccines) cause some patients to develop delayed-type hypersensitivity reactions post-immunization. First Holzer Rep. at 5. Vaccine manufacturers add aluminum salts to vaccines to promote antigen uptake and improve the body’s immune response to the vaccine. *Id.* Some patients experience adverse reactions to the aluminum adjuvants. *Id.* In a later report, Dr. Holzer added that vaccines containing aluminum are the ones most commonly associated with the development of subcutaneous nodules at the injection site. Second Holzer Rep. at 4. He added further that improper administration of a vaccine containing aluminum adjuvants subcutaneously rather than intramuscularly may also increase the risk of the development of a subcutaneous nodule. *Id.* at 5.

Dr. Holzer posited that the slow growth of a subcutaneous nodule would explain the increasing pain, weakness, and numbness in the arm that Petitioner reported. First Holzer Rep. at 6. He opined that Petitioner’s symptoms are consistent with a post-immunization adverse event and that the record supports her claim that she developed a lump at the injection site. *Id.* Dr. Holzer further opined that Petitioner’s case meets the criteria for Level 2 diagnostic certainty for a sterile abscess. *Id.* He posited that the blood pressure cuff caused the spontaneous drainage described in the Brighton criteria. *Id.* He noted that patients who are overweight are at a greater risk for developing sterile abscesses at the vaccine injection site, and stated that Petitioner’s medical record shows that her weight at the time makes it more likely that she developed this complication. *Id.* Dr. Holzer further posited that the increasing pain likely caused Petitioner to guard her arm to avoid pain, thereby causing musculoskeletal strain which manifested in adhesive capsulitis (frozen shoulder). *Id.*

Upon my request to explain what in Petitioner’s medical record supported a diagnosis of delayed hypersensitivity reaction, Dr. Holzer emphasized his opinion that Petitioner’s reports of the symptoms she experienced are reliable. Second Holzer Rep. at 2-3. First, he noted that Dr. Han, Petitioner’s longtime primary care provider, opined in a letter that Petitioner is “a reliable

---

<sup>6</sup> Level 1 Diagnostic Certainty Criteria for Sterile Abscess include:

1. Spontaneous or surgical drainage of material from the mass; AND
2. Material obtained from the mass prior to initiating antimicrobial therapy but with negative evaluation for infectious etiology.

Level 2 Diagnostic Certainty Criteria for Sterile Abscess include:

1. Spontaneous or surgical drainage of non-purulent material from the mass; OR
2. Collection of material e.g. fluid diagnosed by imaging technique or fluctuance; AND
3. The absences of signs of local inflammation such as erythema, pain to light touch, and warm to touch at the injection site; OR
4. No resolution/improvement temporally related to antimicrobial therapy.

historian of her health and symptoms.” *Id.* (quoting Ex. 11 at 1). Second, Dr. Holzer noted that the reports of indigent patients are often more likely to be reliable because patients who lack ready access to medical care due to financial burdens take accurate reporting seriously, both to arrive at an accurate diagnosis and to avoid unnecessary testing that they cannot afford. *Id.* at 2. Dr. Holzer opined that the timeline of symptoms Petitioner reported is consistent with accounts in the medical literature of delayed-type hypersensitivity reaction after vaccination progressing to sterile abscess (i.e., redness and swelling at the injection site that resolves within a matter of several days, followed weeks or months later by a subcutaneous nodule developing at the injection site). *Id.* at 3.

Dr. Holzer challenged Dr. Boos’ assertion that diagnosing Petitioner with an adverse vaccine reaction without contemporaneous medical documentation was not possible. Second Holzer Rep. at 2. Dr. Holzer pointed out that the onset delay of several weeks after vaccination is consistent with the medical literature on sterile abscesses. *Id.* at 3. Dr. Holzer emphasized that the timing of the onset is particularly important: the resolution of the immediate swelling and redness prior to the development of the secondary mass supports his analysis that the lump was a subcutaneous nodule that progressed into a sterile abscess. *Id.* He also noted that the progressive nature of the problem that Petitioner described (i.e., increasing pain and weakness over a period of time) is also consistent with the medical literature on post-immunization reactions. *Id.* at 4.

Dr. Holzer challenged Dr. Boos’ interpretation of Petitioner’s statement that the lump was “moving around.” Second Holzer Rep. at 6. He pointed out that Petitioner never said that the lump moved from the injection site or that it seemed to not have been firmly fixed to the underlying tissue, only that it was capable of moving slightly when pushed. *Id.* He opined that this was consistent with the medical literature on subcutaneous nodules. *Id.* at 6-7.

Dr. Holzer also challenged Dr. Ring’s conclusion that reactive subcutaneous tissue would not be affected by a blood pressure cuff and would not disappear after the application of pressure. Second Holzer Rep. at 7. He argued that excessive pressure, such as beneath a blood pressure cuff, has been known to have adverse effects such as pain, skin discoloration, and acute nerve injury. *Id.* He opined that the positioning of the subcutaneous nodule on a large nerve would explain the increasing pain and weakness that Petitioner reported. *Id.* He also pointed out that adhesive capsulitis or frozen shoulder can occur as a secondary effect of other pain because patients are known to guard or protect a part of their body in which they are experiencing pain to prevent more pain. *Id.* at 8. He posited that this would explain Petitioner’s symptoms. *Id.*

Dr. Holzer indicated that the rupture of a subcutaneous nodule such as the one he opines Petitioner had would not necessarily lead to either spontaneous drainage of fluid from the skin or other external symptoms in the area. Second Holzer Rep. at 9.

In his third expert report, Dr. Holzer opined that “[i]n dermatology, nodule is a term of clinical observation, not pathologic diagnosis.” How precisely a nodule can progress into a sterile abscess is not easy to ascertain because a sterile abscess is actually a type of nodule. Holzer Response to Questions at 1. Sterile abscesses are believed to form as a result of an inflammatory reaction to the aluminum adjuvant in many vaccines. *Id.* at 2. Dr. Holzer challenged Dr. Boos’ claim that patch testing would have been necessary to determine whether Petitioner was having a

reaction to the aluminum in the Adacel vaccine. *Id.* He opined that patch testing for aluminum sensitivity is susceptible to false negative results. *Id.* He conceded that “it cannot be determined when or how [Petitioner’s] subcutaneous nodule turned into a sterile abscess.” *Id.* at 3.

Dr. Holzer conceded that, for purposes of the Brighton Collaboration criteria for sterile abscesses, the blood pressure cuff that he posits caused the lump to rupture was in fact an external stimulus. Holzer Response to Questions at 3. According to Dr. Holzer, this does not preclude a finding that the lump was a sterile abscess. *Id.* He pointed out that the Brighton criteria were not designed to be used a clinical setting, but rather for data collection purposes to determine vaccine safety. *Id.* He added that evaluating a soft-tissue lump is challenging “due to the clinical overlap in presentation,” opining that even had Dr. Han examined the lump at Petitioner’s appointment, she may have been unable to say whether it was a solid nodule or a fluid-filled subcutaneous nodule. *Id.* at 4-5.

Dr. Holzer concluded by observing that the “unfortunate blood pressure cuff rupture adds weight to the retrospective determination that her subcutaneous nodule is likely a sterile abscess using the Brighton Collaboration definition.” Holzer Response to Questions at 5. He opined that the blood pressure cuff increased pressure on the lump, causing it to spontaneously rupture. *Id.* He also reiterated his opinion that, whether the lump was a subcutaneous nodule or a sterile abscess “does not change the strength of the evidence in favor of vaccine causation.” *Id.*

## **B. Respondent’s Expert, Dr. Markus Boos**

### **1. Qualifications**

Dr. Boos received his medical degree from the University of Chicago and completed his dermatology residency at the University of Pennsylvania. Ex. B at 1 (hereinafter “Boos CV”). He is board certified in dermatology and pediatric dermatology. Boos CV at 1. In addition to his medical degree, Dr. Boos holds a Ph.D. in immunology from the University of Chicago. *Id.* His research focused on dermatology and immunology, and he has published 26 peer-reviewed articles and three book chapters. *Id.* at 5-8. Dr. Boos is currently an Attending Physician in dermatology at Seattle Children’s Hospital in Seattle, Washington. *Id.* at 2. He also runs a dermatology-immunology clinic with clinical immunologists. Ex A. at 1.

### **2. Expert Reports**

Dr. Boos filed two expert reports in this case. *See* Ex. A (“First Boos Rep.”) and Ex. M (“Boos Response to Questions”).

In his first report, Dr. Boos challenged Dr. Holzer’s theory that Petitioner’s Tdap vaccination caused her to develop a subcutaneous nodule that became a sterile abscess and caused her frozen shoulder. First Boos Rep. at 3. Dr. Boos noted that the documentation of the lump in the medical record is based on Petitioner’s reporting only, and that the medical record contains no examination or palpation of the lump by a medical professional. *Id.* at 4. Dr. Boos opined that Petitioner’s allegations about her symptoms are not consistent with the contemporaneous medical record. *Id.* Specifically, he questioned Petitioner’s claim that the lump burst when compressed by

a blood pressure cuff on May 10, 2016, because the medical record for that appointment makes no mention of a lump. *Id.*

Dr. Boos conceded that a lump at a vaccine injection site could meet the diagnostic criteria for a subcutaneous nodule. First Boos Rep. at 4. However, he opined that Petitioner’s medical record lacks the typical associated findings of a subcutaneous nodule resulting from an aluminum-induced hypersensitivity reaction, namely, pruritis,<sup>7</sup> dermatitis,<sup>8</sup> hyperpigmentation, lichenification,<sup>9</sup> and hypertrichosis.<sup>10</sup> *Id.* at 4-5. Furthermore, Dr. Boos opined that Petitioner’s case does not meet the Level 1 or Level 2 Brighton criteria for a sterile abscess. *Id.* at 5. Patch testing is needed to confirm an aluminum-induced hypersensitivity reaction, and Petitioner never underwent a patch test. *Id.* at 4.

Dr. Boos opined that Petitioner’s description of the alleged lump having “popped” under the blood pressure cuff is unlikely. First Boos Rep. at 4. He stated that release of foreign material into the surrounding subcutaneous tissue due to the rupture of such a nodule would likely have caused clinical signs and symptoms of an immune reaction, such as redness, swelling, or fever. *Id.* Because Petitioner’s medical record notes none of these symptoms, and only describes increased pain, Dr. Boos opined that it is unlikely that Petitioner had a nodule or sterile abscess that ruptured as suggested by Dr. Holzer. *Id.*

Dr. Boos challenged Dr. Holzer’s opinion that the pain Petitioner associated with the lump was secondary to “stretching the subcutaneous space and triggering cutaneous and intramuscular nociceptors (pain receptors) in surrounding skin and muscle.” First Boos Rep. at 5 (quoting First Holzer Rep. at 6). Dr. Boos opined that this explanation was vague and unlikely because a nodule of sufficient size to cause such a reaction was never documented by a medical provider. *Id.*

Dr. Boos concluded his expert report by noting that “there is a paucity of clinical, radiologic or laboratory evaluation in this case to support the diagnoses alleged, or to support a causative relationship between the Adacel vaccine and petitioner’s subsequent shoulder pain.” First Boos Rep. at 6.

---

<sup>7</sup> Pruritus is another term for itching. *Pruritis*, Dorland’s Online Med. Dictionary, <https://www.dorlandsonline.com/dorland/definition?id=41580> (last accessed August 22, 2022).

<sup>8</sup> Dermatitis is inflammation of the skin. *Dermatitis*, Dorland’s Online Med. Dictionary, <https://www.dorlandsonline.com/definition?id=13334&searchterm=dermatitis> (last accessed August 22, 2022).

<sup>9</sup> “[H]ypertrophy of the epidermis, with thickening and toughening of the skin to give it a leathery appearance, and exaggeration of its normal markings; this is caused by prolonged rubbing or scratching and may be on seemingly normal skin or on skin that has a pruritic disorder.” *Lichenification*, Dorland’s Online Med. Dictionary, <https://www.dorlandsonline.com/dorland/definition?id=28226&searchterm=lichenification> (last accessed August 22, 2022).

<sup>10</sup> Hypertrichosis is excessive growth of the hair. *Hypertrichosis*, Dorland’s Online Med. Dictionary, <https://www.dorlandsonline.com/dorland/definition?id=24051&searchterm=hypertrichosis> (last accessed August 22, 2022).

In his second expert report, Dr. Boos explained what nodules and sterile abscesses are in greater detail. Boos Response to Questions at 1-2. He explained that the term “nodule” is not a diagnosis because it gives no indication of etiology. *Id.* at 1. Whether a nodule can drain as Petitioner claims depends on the type of nodule at issue and whether the contents are liquid capable of being expressed. *Id.* at 1-2. Dr. Boos noted that sterile abscesses are ill-defined in the medical literature, and that this term also does not indicate any etiology. *Id.* at 2. He opined that it is possible for a nodule to progress into a sterile abscess if the nodule was either (1) infectious, or (2) inflammatory. *Id.* Dr. Boos reiterated that, while it is possible for a nodule to develop into a sterile abscess, Petitioner’s medical record does not contain any evidence that this occurred. *Id.* On May 17, 2016, Dr. Han noted no mass, erythema, edema, or skin discoloration during her physical exam. *Id.* (citing Ex. 2 at 141).

Dr. Boos also disagreed with Dr. Holzer’s assertion that the compression of the lump by the blood pressure cuff caused an acute nerve injury to Petitioner’s shoulder. Boos Response to Questions at 3. First, he observed it is unlikely that a blood pressure cuff would be placed high on a patient’s arm such that it would be able to exert pressure on the deltoid (i.e., the injection site). *Id.* He also noted that Petitioner alleges that the lump ruptured under the blood pressure cuff, but that the medical record contains no evidence of accompanying external symptoms. *Id.* Dr. Boos opined that “[i]t is highly unlikely that an inflammatory nodule *with drainable contents* could acutely rupture under pressure and cause enough damage to adversely affect nerve function but not elicit a clinically evident inflammatory response in the subcutaneous tissue characterized by swelling, erythema, and tenderness.” *Id.* (emphasis in original). Similarly, Dr. Boos opined that it would be possible, though highly unlikely, to develop a delayed-type hypersensitivity reaction without any changes in the overlying skin. *Id.* at 4.

### **C. Respondent’s Expert, Dr. David Ring**

#### **1. Qualifications**

Dr. Ring received his medical degree from the University of California, San Diego and a Ph.D. in Psychosocial Aspects of Arm Pain from the University of Amsterdam. Ex. D at 1 (hereinafter “Ring CV”). Dr. Ring completed an orthopedic surgery residency at the Harvard Combined Orthopedic Residency, and fellowship in hand and microvascular surgery at the Massachusetts General Hospital. Ring CV at 1, Ex. C at 1. Dr. Ring was an instructor, assistant professor, associate professor and professor of orthopedic surgery at Harvard Medical School from 1999-2016 and is currently a professor of surgery at the Dell Medical School at the University of Texas Austin. *Id.* Dr. Ring is a member of numerous professional societies including (but not limited to): the American Academy of Orthopaedic Surgeons, American Society for Surgery of the Hand, Orthopaedic Trauma Association, American Orthopaedic Association. *Id.* at 6-7. Dr. Ring is an ad hoc reviewer for various journals, including the New England Journal of Medicine, Annals of Surgery, JAMA Internal Medicine, Osteoarthritis, and more. *Id.* at 8-9. Dr. Ring has given talks nationally and internationally on orthopedic surgery. *See id.* at 13-39. He is board certified in orthopedic surgery, with an added qualification in hand surgery. *Id.* at 39. Dr. Ring has published over 560 peer-reviewed papers and over 100 book chapters. *Id.* at 40-76, 82-105.

## 2. Expert Report

Dr. Ring submitted one expert report in this case. Ex. C (hereinafter “Ring Rep.”). Dr. Ring opined that Petitioner’s presentation does not support a SIRVA table claim. Ring Rep. at 1. Dr. Ring opined that if Petitioner had a subcutaneous reaction, it would not involve issues with her shoulder joint. He further noted that she never met the criteria for adhesive capsulitis. *Id.* The description of Petitioner’s lump and the lump popping when a blood pressure cuff was applied “does not fit with Dr. Holzer’s proposed theory of chronic inflammation. Reactive subcutaneous tissue would not be affected by a blood pressure cuff and would certainly not disappear after applying pressure.” *Id.* at 2.

Dr. Ring noted that neither Dr. Han nor Dr. Taber specialize in musculoskeletal issues and that Dr. Taber’s diagnosis of frozen shoulder was incorrect due to Petitioner’s ability to abduct her left arm. Ring Rep. at 2. Idiopathic adhesive capsulitis requires a higher degree of stiffness and her limitation due to pain indicates she could lift higher than 135 degrees. *Id.* Dr. Ring opined that Petitioner’s pain with elevation is more consistent with age-related rotator cuff tendon changes. *Id.* Based on Petitioner’s medical records, Dr. Ring does not believe Petitioner has a SIRVA injury. *Id.* at 3.

## V. **Applicable Law**

### A. **Petitioner’s Burden**

Under the Vaccine Act, a petitioner may prevail in one of two ways. First, a petitioner may demonstrate that she suffered a “Table” injury—i.e., an injury listed on the Vaccine Injury Table that occurred within the time period provided in the Table. § 11(c)(1)(C)(i). “In such a case, causation is presumed.” *Capizzano v. Sec’y of Health & Hum. Servs.*, 440 F.3d 1317, 1320 (Fed. Cir. 2006); *see* § 13(a)(1)(B). Second, where the alleged injury is not listed in the Vaccine Injury Table, a petitioner may demonstrate that she suffered an “off-Table” injury. § 11(c)(1)(C)(ii).

For both Table and non-Table claims, Vaccine Program petitioners bear a “preponderance of the evidence” burden of proof. Section 13(1)(a). That is, a petitioner must offer evidence that leads the “trier of fact to believe that the existence of a fact is more probable than its nonexistence before [he] may find in favor of the party who has the burden to persuade the judge of the fact’s existence.” *Moberly v. Sec’y of Health & Hum. Servs.*, 592 F.3d 1315, 1324 (Fed. Cir. 2010); *see also Snowbank Enter. v. United States*, 6 Cl. Ct. 476, 486 (1984) (mere conjecture or speculation is insufficient under a preponderance standard). Proof of medical certainty is not required. *Bunting v. Sec’y of Health & Hum. Servs.*, 931 F.2d 867, 873 (Fed. Cir. 1991). In particular, a petitioner must demonstrate that the vaccine was “not only [the] but-for cause of the injury but also a substantial factor in bringing about the injury.” *Moberly*, 592 F.3d at 1321 (quoting *Shyface v. Sec’y of Health & Hum. Servs.*, 165 F.3d 1344, 1352 (Fed. Cir. 1999)); *Pafford v. Sec’y of Health & Hum. Servs.*, 451 F.3d 1352, 1355 (Fed. Cir. 2006). A petitioner may not receive a Vaccine Program award based solely on his assertions; rather, the petition must be supported by either medical records or by the opinion of a competent physician. Section 13(a)(1).

In attempting to establish entitlement to a Vaccine Program award of compensation for a non-Table claim, a petitioner must satisfy all three of the elements established by the Federal Circuit in *Althen*. *Althen* requires that petitioner establish by preponderant evidence that the vaccinations he received caused her injury “by providing: (1) a medical theory causally connecting the vaccination and the injury; (2) a logical sequence of cause and effect showing that the vaccination was the reason for the injury; and (3) a showing of a proximate temporal relationship between vaccination and injury.” *Id.* at 1278.

Each of the *Althen* prongs requires a different showing. Under *Althen* prong one, petitioners must provide a “reputable medical theory,” demonstrating that the vaccine received *can cause* the type of injury alleged. *Pafford*, 451 F.3d at 1355-56 (citations omitted). To satisfy this prong, a petitioner’s theory must be based on a “sound and reliable medical or scientific explanation.” *Knudsen v. Sec’y of Health & Hum. Servs.*, 35 F.3d 543, 548 (Fed. Cir. 1994). Such a theory must only be “legally probable, not medically or scientifically certain.” *Id.* at 549.

Petitioner may satisfy the first *Althen* prong without resort to medical literature, epidemiological studies, demonstration of a specific mechanism, or a generally accepted medical theory. *Andreu v. Sec’y of Health & Hum. Servs.*, 569 F.3d 1367, 1378-79 (Fed. Cir. 2009) (citing *Capizzano*, 440 F.3d at 1325-26). Special Masters, despite their expertise, are not empowered by statute to conclusively resolve what are complex scientific and medical questions, and thus scientific evidence offered to establish *Althen* prong one is viewed “not through the lens of the laboratorian, but instead from the vantage point of the Vaccine Act’s preponderant evidence standard.” *Id.* at 1380. Accordingly, special masters must take care not to increase the burden placed on petitioners in offering a scientific theory linking vaccine to injury. *Contreras v. Sec’y of Health & Hum. Servs.*, 121 Fed. Cl. 230, 245 (2015) (“[p]lausibility ... in many cases may be enough to satisfy *Althen* prong one” (emphasis in original)), *vacated on other grounds*, 844 F.3d 1363 (Fed. Cir. 2017). But this does not negate or reduce a petitioner’s ultimate burden to establish her overall entitlement to damages by preponderant evidence. *W.C. v. Sec’y of Health & Hum. Servs.*, 704 F.3d 1352, 1356 (Fed. Cir. 2013) (citations omitted).

The second *Althen* prong requires proof of a logical sequence of cause and effect, usually supported by facts derived from a petitioner’s medical records. *Althen*, 418 F.3d at 1278; *Andreu*, 569 F.3d at 1375-77; *Capizzano*, 440 F.3d at 1326 (“medical records and medical opinion testimony are favored in vaccine cases, as treating physicians are likely to be in the best position to determine whether a ‘logical sequence of cause and effect show[s] that the vaccination was the reason for the injury’”) (quoting *Althen*, 418 F.3d at 1280). Medical records are generally viewed as particularly trustworthy evidence, because they are created contemporaneously with the treatment of the patient. *Cucuras v. Sec’y of Health & Hum. Servs.*, 993 F.2d 1525, 1528 (Fed. Cir. 1993).

However, medical records and/or statements of a treating physician’s views do not *per se* bind the special master to adopt the conclusions of such an individual, even if they must be considered and carefully evaluated. Section 13(b)(1) (providing that “[a]ny such diagnosis, conclusion, judgment, test result, report, or summary shall not be binding on the special master or court”); *Snyder v. Sec’y of Health & Hum. Servs.*, 88 Fed. Cl. 706, 746 n.67 (2009) (“there is

nothing ... that mandates that the testimony of a treating physician is sacrosanct -- that it must be accepted in its entirety and cannot be rebutted”). As with expert testimony offered to establish a theory of causation, the opinions or diagnoses of treating physicians are only as trustworthy as the reasonableness of their suppositions or bases. The views of treating physicians should also be weighed against other, contrary evidence also present in the record -- including conflicting opinions among such individuals. *Hibbard v. Sec’y of Health & Hum. Servs.*, 100 Fed. Cl. 742, 749 (2011) (not arbitrary or capricious for special master to weigh competing treating physicians’ conclusions against each other), *aff’d*, 698 F.3d 1355 (Fed. Cir. 2012); *Caves v. Sec’y of Health & Hum. Servs.*, No. 06-522V 2011 WL 1935813 at \*17 (Fed. Cl. Spec. Mstr. Apr. 29, 2011), *mot. for review den’d*, 100 Fed. Cl. 344, 356 (2011), *aff’d without op.*, 475 Fed. App’x 765 (Fed. Cir. 2012).

The third *Althen* prong requires establishing a “proximate temporal relationship” between the vaccination and the injury alleged. *Althen*, 418 F.3d at 1281. That term has been equated to the phrase “medically-acceptable temporal relationship.” *Id.* A petitioner must offer “preponderant proof that the onset of symptoms occurred within a timeframe which, given the medical understanding of the disorder’s etiology, it is medically acceptable to infer causation.” *de Bazan v. Sec’y of Health & Hum. Servs.*, 539 F.3d 1347, 1352 (Fed. Cir. 2008). The explanation for what is a medically acceptable timeframe must also coincide with the theory of how the relevant vaccine can cause an injury (*Althen* prong one’s requirement). *Id.* at 1352; *Shapiro v. Sec’y of Health & Hum. Servs.*, 101 Fed. Cl. 532, 542 (2011), *recons. denied after remand on other grounds*, 105 Fed. Cl. 353 (2012), *aff’d without op.*, 503 F. App’x 952 (Fed. Cir. 2013). *Koehn v. Sec’y of Health & Hum. Servs.*, No. 11-355V, 2013 WL 3214877 (Fed. Cl. Spec. Mstr. May 30, 2013), *mot. for review den’d* (Fed. Cl. Dec. 3, 2013), *aff’d*, 773 F.3d 1239 (Fed. Cir. 2014).

## **B. Law Governing Analysis of Fact Evidence**

The process for making factual determinations in Vaccine Program cases begins with analyzing the medical records, which are required to be filed with the petition. Section 11(c)(2). The special master is required to consider “all [] relevant medical and scientific evidence contained in the record,” including “any diagnosis, conclusion, medical judgment, or autopsy or coroner’s report which is contained in the record regarding the nature, causation, and aggravation of the petitioner’s illness, disability, injury, condition, or death,” as well as the “results of any diagnostic or evaluative test which are contained in the record and the summaries and conclusions.” Section 13(b)(1)(A). The special master is then required to weigh the evidence presented, including contemporaneous medical records and testimony. *See Burns v. Sec’y of Health & Hum. Servs.*, 3 F.3d 413, 417 (Fed. Cir. 1993) (it is within the special master’s discretion to determine whether to afford greater weight to contemporaneous medical records than to other evidence, such as oral testimony surrounding the events in question that was given at a later date, provided that such determination is evidenced by a rational determination).

Medical records created contemporaneously with the events they describe are generally trustworthy because they “contain information supplied to or by health professionals to facilitate diagnosis and treatment of medical conditions,” where “accuracy has an extra premium.” *Kirby v. Sec’y of Health & Hum. Servs.*, 997 F.3d 1378 (Fed. Cir. 2021) citing *Cucuras*, 993 F.2d at 1528. This presumption is based on the linked proposition that (i) sick people visit medical professionals;

(ii) sick people honestly report their health problems to those professionals; and (iii) medical professionals record what they are told or observe when examining their patients in as accurate a manner as possible, so that they are aware of enough relevant facts to make appropriate treatment decisions. *Sanchez v. Sec’y of Health & Hum. Servs.*, No. 11-685V, 2013 WL 1880825 at \*2 (Fed. Cl. Spec. Mstr. Apr. 10, 2013) *mot. for rev. denied*, 142 Fed. Cl. 247, 251-52 (2019), *vacated on other grounds and remanded*, 809 Fed. Appx. 843 (Fed. Cir. Apr. 7, 2020).

Accordingly, if the medical records are clear, consistent, and complete, then they should be afforded substantial weight. *Lowrie v. Sec’y of Health & Hum. Servs.*, No. 03-1585V, 2005 WL 6117475 at \*20 (Fed. Cl. Spec. Mstr. Dec. 12, 2005). Indeed, contemporaneous medical records are generally found to be deserving of greater evidentiary weight than oral testimony -- especially where such testimony conflicts with the record evidence. *Cucuras*, 993 F.2d at 1528; see also *Murphy v. Sec’y of Health & Hum. Servs.*, 23 Cl. Ct. 726, 733 (1991), *aff’d per curiam*, 968 F.2d 1226 (Fed. Cir. 1992), *cert. den’d*, *Murphy v. Sullivan*, 506 U.S. 974 (1992) (citing *United States v. U.S. Gypsum Co.*, 333 U.S. 364, 396 (1947) (“[i]t has generally been held that oral testimony which is in conflict with contemporaneous documents is entitled to little evidentiary weight.”)).

However, there are situations in which compelling oral testimony may be more persuasive than written records, such as where records are deemed to be incomplete or inaccurate. *Campbell v. Sec’y of Health & Hum. Servs.*, 69 Fed. Cl. 775, 779 (2006) (“like any norm based upon common sense and experience, this rule should not be treated as an absolute and must yield where the factual predicates for its application are weak or lacking”); *Lowrie*, 2005 WL 6117475 at \*19 (“[w]ritten records which are, themselves, inconsistent, should be accorded less deference than those which are internally consistent”) (quoting *Murphy*, 23 Cl. Ct. at 733)). Ultimately, a determination regarding a witness’s credibility is needed when determining the weight that such testimony should be afforded. *Andreu*, 569 F.3d at 1379; *Bradley v. Sec’y of Health & Hum. Servs.*, 991 F.2d 1570, 1575 (Fed. Cir. 1993).

When witness testimony is offered to overcome the presumption of accuracy afforded to contemporaneous medical records, such testimony must be “consistent, clear, cogent and compelling.” *Sanchez*, 2013 WL 1880825 at \*3 (citing *Blutstein v. Sec’y of Health & Hum. Servs.*, No. 90-2808V, 1998 WL 408611 at \*5 (Fed. Cl. Spec. Mstr. June 30, 1998)). In determining the accuracy and completeness of medical records, the Court of Federal Claims has listed four possible explanations for inconsistencies between contemporaneously created medical records and later testimony: (1) a person’s failure to recount to the medical professional everything that happened during the relevant time period; (2) the medical professional’s failure to document everything reported to her or him; (3) a person’s faulty recollection of the events when presenting testimony; or (4) a person’s purposeful recounting of symptoms that did not exist. *LaLonde v. Sec’y of Health & Hum. Servs.*, 110 Fed. Cl. 184, 203-04 (2013), *aff’d*, 746 F.3d 1334 (Fed. Cir. 2014). In making a determination regarding whether to afford greater weight to contemporaneous medical records or other evidence, such as testimony at hearing, there must be evidence that this decision was the result of a rational determination. *Burns*, 3 F.3d at 417.

### C. Analysis of Expert Testimony

Establishing a sound and reliable medical theory connecting the vaccine to the injury often requires a petitioner to present expert testimony in support of his or her claim. *Lampe v. Sec’y of Health & Hum. Servs.*, 219 F.3d 1357, 1361 (Fed. Cir. 2000). Vaccine Program expert testimony is usually evaluated according to the factors for analyzing scientific reliability set forth in *Daubert v. Merrell Dow Pharm., Inc.*, 509 U.S. 579, 594-96 (1993). See *Cedillo v. Sec’y of Health & Hum. Servs.*, 617 F.3d 1328, 1339 (Fed. Cir. 2010) (citing *Terran v. Sec’y of Health & Hum. Servs.*, 195 F.3d 1302, 1316 (Fed. Cir. 1999)). “The *Daubert* factors for analyzing the reliability of testimony are: (1) whether a theory or technique can be (and has been) tested; (2) whether the theory or technique has been subjected to peer review and publication; (3) whether there is a known or potential rate of error and whether there are standards for controlling the error; and (4) whether the theory or technique enjoys general acceptance within a relevant scientific community.” *Terran*, 195 F.3d at 1316 n.2 (citing *Daubert*, 509 U.S. at 592-95).

The *Daubert* factors play a slightly different role in Vaccine Program cases than they do when applied in other federal judicial fora. *Daubert* factors are employed by judges to exclude evidence that is unreliable and potentially confusing to a jury. In Vaccine Program cases, these factors are used in the weighing of the reliability of scientific evidence. *Davis v. Sec’y of Health & Hum. Servs.*, 94 Fed. Cl. 53, 66-67 (2010) (“uniquely in this Circuit, the *Daubert* factors have been employed also as an acceptable evidentiary-gauging tool with respect to persuasiveness of expert testimony already admitted”). The flexible use of the *Daubert* factors to evaluate persuasiveness and reliability of expert testimony has routinely been upheld. See, e.g., *Snyder*, 88 Fed. Cl. at 743. In this matter, (as in numerous other Vaccine Program cases), *Daubert* has not been employed at the threshold, to determine what evidence should be admitted, but instead to determine whether expert testimony offered is reliable and/or persuasive.

Respondent frequently offers one or more experts of his own in order to rebut a petitioner’s case. Where both sides offer expert testimony, a special master’s decision may be “based on the credibility of the experts and the relative persuasiveness of their competing theories.” *Broekelschen v. Sec’y of Health & Hum. Servs.*, 618 F.3d 1339, 1347 (Fed. Cir. 2010) (citing *Lampe*, 219 F.3d at 1362). However, nothing requires the acceptance of an expert’s conclusion “connected to existing data only by the *ipse dixit* of the expert,” especially if “there is simply too great an analytical gap between the data and the opinion proffered.” *Snyder*, 88 Fed. Cl. at 743 (quoting *Gen. Elec. Co. v. Joiner*, 522 U.S. 136, 146 (1997)). A “special master is entitled to require some indicia of reliability to support the assertion of the expert witness.” *Moberly*, 592 F.3d at 1324. Weighing the relative persuasiveness of competing expert testimony, based on a particular expert’s credibility, is part of the overall reliability analysis to which special masters must subject expert testimony in Vaccine Program cases. *Id.* at 1325-26 (“[a]ssessments as to the reliability of expert testimony often turn on credibility determinations”); see also *Porter v. Sec’y of Health & Hum. Servs.*, 663 F.3d 1242, 1250 (Fed. Cir. 2011) (“this court has unambiguously explained that special masters are expected to consider the credibility of expert witnesses in evaluating petitions for compensation under the Vaccine Act”).

## D. Consideration of Medical Literature

Finally, although this decision discusses some but not all of the medical literature in detail, I have reviewed and considered all of the medical records and literature submitted in this matter. See *Moriarty v. Sec’y of Health & Hum. Servs.*, 844 F.3d 1322, 1328 (Fed. Cir. 2016) (“We generally presume that a special master considered the relevant record evidence even though [s]he does not explicitly reference such evidence in h[er] decision.”); *Simanski v. Sec’y of Health & Hum. Servs.*, 115 Fed. Cl. 407, 436 (2014) (“[A] Special Master is ‘not required to discuss every piece of evidence or testimony in her decision.’” (citation omitted)), *aff’d*, 601 F. App’x 982 (Fed. Cir. 2015).

## VI. Analysis

Petitioner’s causation theory is somewhat convoluted. Petitioner contends that she experienced a delayed-type hypersensitivity reaction as a result of her Tdap vaccine. This caused her to develop a subcutaneous nodule that progressed to a sterile abscess at the injection site. First Holzer Rep. at 1, 5. The sterile abscess caused pain and weakness due to nerve compression. Second Holzer Rep. at 7. The application of a blood pressure cuff resulted in an “acute nerve injury” and caused the sterile abscess to burst. *Id.* This nerve injury healed, but the pain caused Petitioner to guard her shoulder, resulting in a frozen shoulder.<sup>11</sup> *Id.* at 8.

### A. Applicable Terms and Diagnosis

A nodule is defined as a “firm papule[] or lesion[] that extend[s] into the dermis or subcutaneous tissue.” First Holzer Rep. at 3. An abscess is “an enclosed collection of liquefied tissues, that results from the body’s reaction to foreign material.” *Id.* at 4. A sterile abscess is an abscess “in which no infectious etiology c[an] be demonstrated.” Kohl et al., *Abscess at injection site: Case definition and guidelines for collection, analysis, and presentation of immunization safety data*, 25 VACCINE 5821-38, at 5822 (2007) (filed as Ex. 20) (hereinafter “Kohl”).

The Brighton Collaboration Local Reactions Working Group for Abscess at Injection Site proposed criteria for diagnosing abscesses at injection site after vaccine administration. Kohl lists the following two levels of diagnostic certainty.

#### Level 1 of diagnostic certainty

*Abscess at injection site* is a localized soft tissue collection of material, occurring at the site of immunization and is defined by:

#### B. Sterile abscess

---

<sup>11</sup> Dr. Holzer acknowledged that a frozen shoulder diagnosis may not be correct, but opined that Petitioner suffered from “nerve trauma and increased pain in her shoulder” as a result of the blood pressure cuff incident. Second Holzer Rep. at 8. Because this case does not turn on whether Petitioner suffered from a frozen shoulder, I have not analyzed this issue.

- Spontaneous<sup>12</sup> or surgical drainage of material from the mass;
- AND
- Material obtained from the mass prior to initiating antimicrobial therapy, but with negative evaluation for infectious etiology (which may include Gram stain, cultures or other tests).

### **Level 2 of diagnostic certainty**

In settings where laboratory evaluation for infectious etiology (Gram stain, cultures, or other technique) was either not performed, performed after starting antimicrobial therapy, or not reported.

#### **B. Sterile abscess**

- Spontaneous or surgical drainage of non-purulent material from the mass;
- OR
- Collection of material e.g., fluid diagnosed by imaging technique (e.g., sonogram, CT, MRI, or other modality) or fluctuance;<sup>13</sup>
- AND
- The absence of signs of local inflammation such as erythema, pain to light touch, and warm to touch at the injection site; OR
  - No resolution/improvement temporally related to antimicrobial therapy.

Kohl at 5823. Kohl notes that “There is no level three of diagnostic certainty because the Working Group agreed that any criteria less than those required for Level 2 would render the definition too unspecific to still qualify as an abscess.” *Id.*

Dr. Boos opined that Petitioner did not meet either the Brighton level 1 or level 2 criteria because there was neither spontaneous nor surgical drainage of the purported abscess, Petitioner did not have radiologic imaging, and fluctuance was never noted in her medical records. Boos Response to Questions at 3; *see also*, First Boos Rep. (noting “[t]he facts of this case do not support the alleged diagnoses of a subcutaneous nodule or sterile abscess as defined by Brighton Criteria”).

Dr. Holzer disagreed with Dr. Boos. He opined that

The blood pressure cuff is an external stimulus in this case but that does not preclude determining in [C.V.’s] case that the most likely identity of the nodule she detected clinically below the skin was a sterile abscess, a known complication of immunization and subcutaneous medication administration. These abscesses are fluid-filled “sacs” which expand with necrotic liquefied biomatter as the immune

---

<sup>12</sup> Spontaneous means “occurring without external influence.” *Spontaneous*, Dorland’s Online Med. Dictionary, <https://www.dorlandsonline.com/dorland/definition?id=46767&searchterm=spontaneous> (last accessed Aug. 30, 2022).

<sup>13</sup> Fluctuant is defined as “conveying the sensation of or exhibiting wavelike motion on palpation, owing to a liquid content.” *Fluctuant*, Dorland’s Online Med. Dictionary, <https://www.dorlandsonline.com/dorland/definition?id=18850> (last accessed Aug. 30, 2022).

response progresses. Spontaneous drainage occurs with rupture -- when the ambient pressure exceeds that which the abscess wall is able to withstand. ... This drainage can be spontaneous when the pressure proceeds to the point of causing what is perceived as a non-traumatic, spontaneous bursting or rupturing of the fluid-filled sac or an external blood pressure cuff can add pressure to force the “spontaneous” drainage.

Holzer Response to Questions at 3.

Ultimately, because Petitioner’s purported abscess did not drain spontaneously and was not collected surgically, it does not meet the plain language definition established by the Brighton Collaboration. Kohl et al. note that “although potentially applicable in a clinical setting, the levels of diagnostic certainty are intended for epidemiologic purposes and not as criteria for treatment.” Kohl at 5823. Accordingly, the fact that the lump Petitioner described does not meet either the Brighton level 1 or level 2 criteria does not end the analysis in this case.

## **B. *Althen* Prong One**

Under *Althen*’s first prong, the causation theory must relate to the alleged injury. Petitioner must provide a “reputable” medical or scientific explanation, demonstrating that the vaccines received can cause the type of injury alleged. *Pafford v. Sec’y of Health & Hum. Servs.*, 451 F.3d 1352, 1355-56 (Fed. Cir. 2006). The theory must be based on a “sound and reliable medical or scientific explanation.” *Knudsen v. Sec’y of Health & Hum. Servs.*, 35 F.3d 543, 548 (Fed. Cir. 1994). It must only be “legally probable, not medically or scientifically certain.” *Id.* at 549.

### 1. Vaccination Can Cause a Sterile Abscess to Develop at the Site of Vaccine Administration

Dr. Holzer opined that “[s]terile abscesses and subcutaneous nodules are commonly reported in the medical literature to occur after the administration of vaccines containing aluminum adjuvants.” First Holzer Rep. at 5. These abscesses can form due to a delayed-type hypersensitivity reaction. See Batista-Duharte et al., *An approach to local immunotoxicity induced by adjuvanted vaccines*, 17 INTERNATIONAL IMMUNOPHARMACOLOGY 526-36 (2013) (filed as Ex. 16) (hereinafter “Batista-Duharte”). Batista-Duharte also noted that vaccines can cause the formation of a sterile abscess. Batista-Duharte at 527.

Rothstein et al., presented the Brighton Collaboration Local Reactions Working Group guidelines for the clinical diagnosis of injection site nodules. Rothstein et al., *Nodule at injection site as an adverse event following immunization: case definition and guidelines for data collection, analysis, and presentation*, 22 VACCINE 575-85 (2004) (filed as Ex. 22) (hereinafter “Rothstein”). The Brighton Working Group noted that a nodule at the injection site may progress to a sterile abscess. Rothstein at 576.

Similarly, Kohl et al. stated that “[a]n abscess at an injection site involving a localized soft tissue collection of material at the site of immunization is a rare local reaction.” Kohl at 5821.

Klein et al., discussed two cases where children developed recurrent sterile abscesses after receipt of vaccines containing an aluminum adjuvant. Klein et al., *Recurrent sterile abscesses following aluminum adjuvant-containing vaccines*, BMJ CASE REP. (2009); doi: 10.1136/bcr.09.2008.0951 (filed as Ex. 19) (hereinafter “Klein”). The authors concluded that “these occurrences support an association between receipt of aluminum adjuvant and sterile abscesses in susceptible patients.” Klein at 1.

Lauren et al., stated that “[a]lthough mild vaccination site reactions are most commonly reported, persistence of erythema, sterile abscesses, or subcutaneous nodules weeks to months after vaccination can also occur.” Lauren et al., *Case Report of Subcutaneous Nodules and Sterile Abscesses Due to Delayed Type Hypersensitivity to Aluminum-Containing Vaccines*, 138 PEDIATRICS 4, 1-7, at 2 (2018) (filed as Ex. 21) (hereinafter “Lauren”). The authors continued, noting that “[i]ntramuscular injection of aluminum, a common adjuvant in inactivated vaccines and in allergen immunotherapy leaves a “depot” of antigen, prolonging exposure to antigen presenting cells and improving host immunologic response.” *Id.* at 3.

Dr. Boos agreed that subcutaneous nodules and sterile abscesses can occur after vaccination, although he noted they are “thought to be related to more superficial placement of the vaccine (subcutaneously rather than intramuscularly).” First Boos Rep. at 4.

The medical literature combined with Dr. Holzer’s opinion is persuasive on this point. Petitioner has presented preponderant evidence that the Tdap vaccine can cause a delayed-type hypersensitivity reaction, and that this DTH reaction can in turn cause a sterile abscess to develop.

## 2. A Sterile Abscess Can Result in Nerve Compression

Petitioner presented one piece of medical literature in support of the point that a sterile abscess can cause a nerve injury. Lifchez et al., is a case report discussing two cases involving the compression of the radial nerve by ganglion cysts. Lifchez et al., *Compression Neuropathy of the Radial Nerve Due to Ganglion Cysts*, 3 HAND 152-54 (2008) (filed as Ex. 28) (hereinafter “Lifchez”). Lifchez noted that “[a] ganglion can cause focal neurologic symptoms when the cyst wall compresses a nerve.” Lifchez at 152. Although this article involves cysts located near the elbow and not in the deltoid, the concept discussed in Lifchez is broadly applicable to the case at bar.

## 3. A Blood Pressure Cuff Can Cause a Nerve Injury

Petitioner presented the Elmatite article in support of the proposition that a blood pressure cuff can cause a nerve injury. This article discusses a patient who experienced injury to the radial, median, and ulnar nerves due to the inflation of the automatic noninvasive blood pressure (NIBP) cuff. Elmatite et al., *Perioperative Automated Noninvasive Blood Pressure- (NIBP-) Related Peripheral Nerve Injuries: An Anesthetist’s Dilemma—A Case Report and Review of the Literature*, CASE REPORTS IN ANESTHESIOLOGY (2020), <https://doi.org/10.1155/2020/5653481> (filed as Ex. 34) (hereinafter “Elmatite”). Elmatite noted other reports of blood pressure cuff-induced nerve injuries. Elmatite at 5, Table 2. The authors concluded “the exact mechanism of nerve injury is unknown, but may have resulted from mechanical compression at the lower edge

of the pressure cuff on relatively superficially located peripheral nerves in the lower part of the arm.” *Id.* This article provides some evidence that while unusual, a blood pressure cuff can cause an injury to a nerve as a result of mechanical compression.

4. Pain Can Cause Someone to Guard their Shoulder and Develop a Frozen Shoulder or Increased Pain/Stiffness

Dr. Holzer opined that pain can cause guarding of the shoulder, which can lead to stiffness. He described this in C.V.’s situation as follows: “As her acute nerve injury continued to heal, the pain began to subside; however, the guarding of her arm and shoulder due to pain was now causing other pain, one that was more of a diffuse throbbing pain that increased at night.” Second Holzer Rep. at 8. Although Petitioner did not present any literature to support this statement, I find that Dr. Holzer’s opinion on this uncontroverted point is sufficient to establish this portion of Petitioner’s theory.

Petitioner has presented preponderant evidence with respect to *Althen* prong one.<sup>14</sup>

**C. *Althen* Prong Two**

Under *Althen*’s second prong, a petitioner must “prove a logical sequence of cause and effect showing that the vaccination was the reason for the injury.” *Althen*, 418 F.3d at 1278. The sequence of cause and effect must be “logical’ and legally probable, not medically or scientifically certain.” *Id.* A petitioner is not required to show “epidemiologic studies, rechallenge, the presence of pathological markers or genetic disposition, or general acceptance in the scientific or medical communities to establish a logical sequence of cause and effect.” *Id.* (omitting internal citations). *Capizzano*, 440 F.3d at 1325. Instead, circumstantial evidence and reliable medical opinions may be sufficient to satisfy the second *Althen* prong.

I note at the outset that there is scant evidence supporting any of the components of Petitioner’s prong one theory. Dr. Boos noted that there is a “complete absence of any objective findings.” First Boos Rep. at 5. The first issue to resolve is whether Petitioner developed a golf ball-sized lump at the vaccine injection site, as her theory of the case depends on this fact. For the reasons discussed below, I find that the evidence does not support the existence of a lump in the deltoid that developed after vaccination.

1. There is not Preponderant Evidence that Petitioner Developed a Lump at the Injection Site which Burst after the Application of a Blood Pressure Cuff

In her affidavit, Petitioner contended that she experienced pain and redness at the injection site for approximately two weeks. Ex. 6 at 1. She further averred that “[b]y the third week, the pain

---

<sup>14</sup> I note that while Respondent argued that Petitioner did not meet her burden in establishing the first *Althen* prong, he did not contest the specific points of Petitioner’s prong one theory. See Respt’s Response to Pet’r’s Motion for a Ruling on the Record at 14-15. Dr. Boos’ discussion of Petitioner’s theory similarly focused on Petitioner’s deficiencies in her *Althen* prong two showing.

had not resolved and a lump developed under the skin near the injection site.” *Id.* Petitioner described the continuation of her shoulder pain as follows:

Over the next several months, the arm and shoulder pain kept growing in intensity and began affecting a larger part of my arm. I became unable to extend or lift my arm. I experienced pins and needles from the area of injection down towards my hand. I experienced loss of strength in the affected arm and hand.

...

By March, 2016, there was no relief from the pain in my arm and my mobility was worsening. There was a golf ball sized lump under my skin at the site of injection. I experienced stabbing pain when I would accidentally roll over or attempt to lift my arm. My husband urged me to go to the doctor, but our co-pay was very expensive and I wasn’t sure that anyone could do anything to make my pain subside.

...

In early May 2016, as I attempted to pull a baking dish of baked spaghetti out of the oven, I lost the feeling in my hand and almost dropped the dish to the floor. I managed to quickly save the dish with my other hand but experienced a burn on my right hand between the thumb and pointer finger. After that incident, I knew I could no longer avoid seeing the doctor.


*Id.* This affidavit provides context for Petitioner’s May 10, 2016 medical visit.

Petitioner visited Dr. Han, her PCP, on May 10, 2016. This visit is Petitioner’s first visit to her PCP after vaccination.<sup>15</sup> The reason for the visit was listed as “follow up.” Ex. 2 at 123. During this appointment, Petitioner discussed three matters: 1) her diabetes, 2) her prior shingles outbreak, and 3) the fact that she was experiencing difficulty swallowing medication. *Id.* at 129. There is no mention in these medical records that Petitioner experienced pain in her arm, pins and needles, or that she had a golf ball-sized lump at her vaccine injection site. There is no documentation of a burn on her hand, and no mention of the incident with the baking dish, which according to Petitioner, prompted her visit to see her PCP. Ex. 6 at 2 (“After that incident, I knew I could no longer avoid seeing the doctor.”).

Although the record does list “Adacel” “Severe arm pain” and “Myalgias” under the “review of patient’s allergies” section (Ex. 2 at 130), this note was added after the visit.

---

<sup>15</sup> Although there is no mention of shoulder pain when Petitioner visited her eye doctor two times after vaccination and before the May 10, 2016 medical appointment, I would not necessarily expect Petitioner to mention shoulder pain in the context of a follow up on her herpes zoster uveitis. Accordingly, the fact that she did not discuss shoulder pain or a lump in her shoulder during these visits does not weigh against her position in my analysis. *See* Ex. 5 at 47-48 (documenting December 12, 2015 appointment); Ex. 5 at 52-53 (documenting March 14, 2016 appointment).



Ex. 10 at 10. *See also* Ex. 3 at 11, noting the same allergy associated with the date 6/11/2016 (and not the date of the 5/10/2016 medical visit).

Accordingly, this record demonstrates that during her medical visit on May 10, 2016, Petitioner did not mention arm pain or any kind of reaction to her Tdap vaccine. She further did not mention a golf ball-sized lump in her arm, something that is arguably more significant than “[s]ome difficulty with swallowing meds.” Ex. 2 at 129. This is despite the fact that Petitioner contends that this lump existed as of March 2016, and that she was experiencing “no relief” from the pain in her arm and shoulder. *See* Ex. 6 at 1.

Later in this same medical record, Dr. Han conducted a physical exam of Petitioner where she documented that C.V. “[a]ppears healthy. Alert; in no acute distress. Pleasant.” Ex. 2 at 130. Dr. Han did not document the existence of a golf ball-sized lump in Petitioner’s deltoid. Dr. Han assessed Petitioner with uncontrolled diabetes mellitus and dysphagia.<sup>16</sup> *Id.* at 130-31. The fact that Dr. Han did not assess Petitioner with a lump in her arm is further evidence that this issue was not present or discussed during the visit.


I am cognizant that financial constraints can serve as a barrier to health care. Because of this, some petitioners may not visit the doctor due to cost of co-pays, lack of insurance, or their inability to miss work. In fact, Petitioner mentioned her high co-pay as one reason she did not go to the doctor sooner. Ex. 6 at 2. However, in this instance, Petitioner was already at a medical appointment to follow up on other conditions. It stands to reason that when Petitioner did spend the money to go see a doctor, she would mention all the symptoms she was experiencing, and not leave anything out. Given the severity of the symptoms, the impact on her daily life, and the concern with the cost of medical care, it seems unreasonable that Petitioner would not mention and/or discuss a serious medical problem involving her shoulder with her primary care doctor during her appointment on May 10, 2016. The fact that there is no documentation of a lump at the injection site noted in the medical records from May 10, 2016 is persuasive evidence that Petitioner was not experiencing an injection site lump at this time.

After her medical appointment on May 10, 2016, Petitioner messaged Dr. Han between 8:04-8:17 PM CDT on May 11, 2016:

<sup>16</sup> Dysphagia is “difficulty in swallowing.” *Dysphagia*, Dorland’s Online Med. Dictionary, <https://www.dorlandsonline.com/dorland/definition?id=15265> (last accessed Aug. 26, 2022).


I can't let yesterday's visit go without comment. That was quite possibly one of my worst office visits. When the technician took my blood pressure and informed me that the BP was high, I told her then that I required a larger cuff. She did nothing. At the end of the visit, she returned with a larger cuff per Dr request and an automatic BP machine. She hooked it up to my left arm because she had drawn blood from the right. She turned it on and let. It up 5 times, each time producing an error in the reading. Each time the cuff grew tighter. After the 5th time, my arm was turning reddish/blue, I was in tears and experiencing excruciating pain. I turned the thing off without obtaining (1)

[C.V.] to Jini H. Han, MD

 (2) a reading. I am left with two long red bruises on my arm and more pain than before because of her negligence. If she would have listened and fetched the larger cuff at the beginning of the appointment I wouldn't be sitting here with new injuries to the arm and whining in this message. I have never had a bad experience at North shore before. This one was a doozy. It may sound insignificant but I live with constant pain in that arm...I don't need more. If there was a place to complain on this website other than messaging the Dr., I would have done so. They only give email options for billing. 8:17 PM

Ex. 10 at 2, 4. Of note, although Petitioner indicated that she experienced prior left arm pain, she did not mention a lump at the injection site that burst as a result of the nurse's use of the automatic blood pressure machine. Dr. Han responded to her message, stating:

Han, Jini H., MD to [C.V.]

[C.V.], 7:57 PM 

I apologize this was such a bad and painful experience. I will bring it to my practice manager's attention and request she phone you; our staff should be more mindful about using the correct blood pressure cuffs.  
Please try to keep the arm elevated/on a pillow and apply ice.


Jini Han, MD

Last read by [C.V.] at 11:03 AM on 5/15/2016.

*Id.* Petitioner responded to Dr. Han on May 15, 2016.

May 15, 2016

[C.V.] to Jini H. Han, MD

 Thanks for the pills and ice pack suggestion. I am not taking the Lantus right now and can't do so at this time. I have had a pretty sedentary lifestyle for the past six months. I'm sure moving around would help. Tried to get on the exercycle but couldn't so my only recourse is to walk in place. I am coming in Tuesday evening for another appt. I need to discuss the vaccine injury further as I am going to pursue this. I'll need documentation. Don't worry, it won't have anything to do with you...I would never do anything that would hurt you. See you Tuesday.  
Thanks again,  
[C.V.] 11:08 AM

*Id.* It is clear that by May 15, 2016, Petitioner had made a decision to pursue a claim in the Vaccine Program.

Petitioner presented to Dr. Han on Tuesday May 17, 2016 at approximately 1835. Ex. 2 at 134. During this visit, the medical record documents that Petitioner presented for “left arm pain.” *Id.* at 137. The record details the following history:

Received Tdap left upper arm on 12/5/15 here; no severe pain during the injection. Subsequently, developed swelling at site of injection, no obvious redness. Resolved after a couple of weeks. Then the pain and a ping pong ball sized knot at site of the injection recurred. Has persisted since and bothers her a lot. Recently had BP taken in the left arm and this has exacerbated her arm pain. The prior swelling in the arm reportedly “popped” due to the BP cuff pressure and is no[] longer present although the pain is worse.

*Id.* Dr. Han conducted a physical exam and noted that Petitioner experienced mildly decreased abduction in her left shoulder. *Id.* at 141. She further noted that “no focal mass/induration/erythema appreciated.” *Id.* Dr. Han assessed Petitioner with pain of the left upper extremity of unclear etiology. *Id.*

The next morning, Petitioner messaged Dr. Han at 9:36AM requesting that her medical records be sent to attorneys who would presumably assist with her vaccine case.

Hi Dr. Han,  
As per our conversation last night, the secured fax number is 877-652-5042. Please fax to the attention of Brittany Shalla. There is no form to be completed. They just need the medical records pertaining to the left arm where I received the tetanus vaccination, mainly the first time I came to see you about it and any subsequent visits and any diagnosis.  
Thanks for your time!  
Have a great day!  
[C.V.]

Ex. 10 at 7.<sup>17</sup> Petitioner reiterated this request on May 20, 2016, noting that “[t]he attorney’s office says they didn’t receive any documentation from you.” *Id.* at 8.

In general, contemporaneous medical records are presumed to be accurate and complete. *Cucuras v. Sec’y of Health & Hum. Servs.*, 933 F.2d 1525, 1528 (Fed. Cir. 1993). There is a more than five month gap in time between Petitioner’s vaccination and when she next presented to her PCP, Dr. Han. In assessing whether Petitioner developed a golf ball-sized lump in her arm after vaccination, I have credited the medical records from May 10, 2016 over those

---

<sup>17</sup> I note that CM/ECF lists the fax number for the Maglio Firm as (941) 952-5042. Petitioner’s counsel worked at the Maglio Firm at the time this petition was filed.

from May 17, 2016.<sup>18</sup> Although there is just one week between these two visits, Petitioner began actively pursuing her vaccine claim after the May 10 appointment, and before the May 17 appointment. Because of this, I find the earlier records are more persuasive than the later ones as there is no indication they were created in anticipation of litigation. *See, e.g., Sheets v. Sec'y of Health & Hum. Servs.*, No. 16-1173V, 2019 WL 2296212 at \*19 (Fed. Cl. Spec. Mstr. Apr. 30, 2019) (later-in-time statements whether made to treaters or prepared for purposes of litigation do not suffice to contradict contemporaneous records).

I have also considered the *Kirby* case in arriving at my factual determination in the case at bar. In *Kirby*, a portion of the petitioner's medical records was silent regarding the persistence of her symptoms. The Federal Circuit held that medical records are not presumptively accurate and complete as to all [of a] patient's physical conditions. *Kirby v. Sec'y of Health & Hum. Servs.*, 997 F.3d 1378, 1382-83 (Fed. Cir. 2021). The Circuit held that a reasonable fact finder *could find* that petitioner's testimony of ongoing pain did not conflict with the records which were silent about either the existence or the nonexistence of such symptoms. *Id.* at 1383. The Circuit noted that the silence in the *Kirby* records could be explained by the fact that petitioner had "reached maximum medical improvement and thus exhausted all available treatment." *Id.* This final point is certainly a difference between the petitioner in *Kirby* and the petitioner in this case. C.V. had never sought treatment for the lump at the injection site.

Based on the particular facts of this case, I find that Petitioner's silence about the presence of a lump in her deltoid at the injection site raises substantial question about whether such a lump existed. Dr. Han's records from the May 10 visit were comprehensive. She noted the reasons for Petitioner's visit (which also included a less severe medical complaint – difficulty swallowing pills). There is no indication that Petitioner mentioned a lump in her shoulder to Dr. Han on May 10, 2016. Ex. 2 at 123-29. Further, Petitioner does not claim that she told Dr. Han about this condition and that Dr. Han failed to record her concern. The May 10, 2016 records further demonstrate that Dr. Han did not observe a lump during her physical examination. *Id.* at 132. Notably, when she complained to Dr. Han about the blood pressure cuff incident in a message on May 11, Petitioner did not mention that the cuff burst the lump in her arm. Ex. 10 at 2, 4.

Ultimately, for the reasons discussed in this decision, I find there is not preponderant evidence to support the existence of a lump in Petitioner's arm that burst when a blood pressure cuff was inflated on May 10, 2016.

## 2. Petitioner did not have Skin Changes Typically Associated with a Sterile Abscess that Ruptured

Even if I were to assume that preponderant evidence in the medical records supports the existence of a golf ball-sized lump at the injection site, several other factors suggest that Petitioner's theory of the case is not consistent with her medical history.

---

<sup>18</sup> I find the medical records documenting the September 29, 2016 visit to Dr. Taber to be unpersuasive for the same reason.

Dr. Boos persuasively opined that if a subcutaneous nodule in Petitioner's arm had developed due to a DTH reaction, he would have expected it to have "typical associated findings of these lesions ... pruritis, dermatitis, hyperpigmentation, lichenification, and hypertrichosis." First Boos Rep. at 4-5. He opined that "it would be extremely unlikely for a DTH reaction that originates in the subcutaneous tissues ... to present without any overlying skin changes." Boos Response to Questions at 4. Because Petitioner did not present with any of these skin changes, it is unlikely that she had a sterile abscess due to DTH reaction.

Dr. Boos noted that the Silcock article supports the point that a subcutaneous nodule can present after vaccination without symptoms. Silcock et al., state that "[c]linical signs and symptoms of a subcutaneous nodule may occur in overlap with the common injection site reactions. As swelling, induration and erythema resolve from the injection site, a firm lump becomes evident, with associated pruritus." Silcock et al., *Subcutaneous nodules: an important adverse event following immunization*, 18 EXPERT REVIEW OF VACCINES 4, 405-10 (2019) (filed as Ex. 36) (hereinafter "Silcock"). The same article goes on to state,

Subcutaneous nodules may be asymptomatic or be associated with pruritus, pain, overlying redness or erythema. Skin changes are commonly associated with subcutaneous nodules. Although these have been documented to occur, it is unclear if this is primarily related to the inflammatory response of the reaction or secondary to the itch-scratch cycle of chronic pruritus.

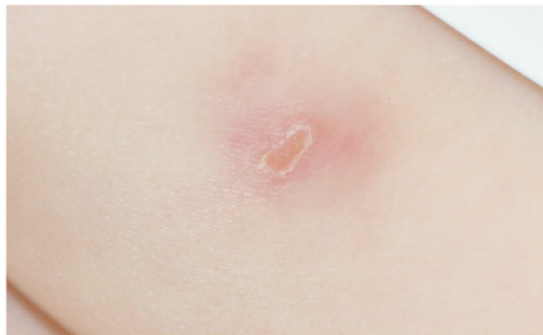*Id.* Based on this, Dr. Boos opined that it is possible but unlikely for a subcutaneous nodule to form without any skin changes. Boos Response to Questions at 4. This position is supported by the medical literature filed in this case.

For example, while the Avcin case report filed by Petitioner noted that a subcutaneous nodule can form as a result of a reaction to the aluminum in the vaccine's adjuvant, this report documented that "[a]luminum granuloma may be associated with pain, itching and local skin alterations, such as hypertrichosis, eczema, excoriation, and hyperpigmentation, and systemic symptoms, such as low-grade fever, sleep disturbances, and irritability." Avcin et al., *Subcutaneous nodule after vaccination with an aluminum-containing vaccine*, 17 ACTA DERMATOVEN APA 4, 182-84 (2008) (filed as Ex. 15) (hereinafter "Avcin"). In fact, in this particular case, the 10 year-old girl who was the subject of the case report presented with subcutaneous swelling on the outer side of the left upper arm that had been present for eight months. Avcin at 183.

Klein et al., described two cases where young children developed sterile abscesses after vaccination. In the first case, a two-month-old girl developed a sterile abscess approximately three weeks after several vaccinations; this abscess was accompanied by induration and discoloration in one thigh that spontaneously drained 15 ml of fluid. In the other case, a two month-old boy received several vaccinations in his legs and also developed a sterile abscess which similarly was indurated and "developed a 'purplish' discoloration." *Id.* at 2.

Lauren et al., discussed a seven month-old boy who developed subcutaneous nodules after vaccination. When he was examined at seven months, the authors included the following picture

in the case report which they labeled as “Representative nodule when the patient was 7 months of age at time of initial evaluation.”



Lauren at 2. The changes to the skin are apparent from the photograph, and are consistent with Dr. Boos’ opinion. Dr. Boos cited to other reports where skin changes were observed in the context of vaccine-induced nodules. *See e.g., Beveridge et al., Local Vaccine Site Reactions and Contact Allergy to Aluminum*, 29 PEDIATRIC DERMATOLOGY 1, 68-72 (2012) (filed as Ex. J); Gordon et al., *Delayed-type hypersensitivity to vaccine aluminum adjuvant causing subcutaneous leg mass and urticaria in a child*, 35 PEDIATRIC DERMATOLOGY 234-36 (2018) (filed as Ex. I).

Importantly, Dr. Boos also discussed the fact that Petitioner’s purported sterile abscess ruptured, noting that this point further decreases the likelihood that such a nodule could exist without some type of clinically visible proof of its existence.

**It is highly unlikely that an inflammatory nodule *with drainable contents* could acutely rupture under pressure and cause enough damage to adversely affect nerve function but not elicit a clinically evident inflammatory response in the subcutaneous tissue characterized by swelling, erythema and tenderness.**

Boos Response to Questions at 3 (emphasis in original). Petitioner’s medical records from May 17, 2016, one week after the blood pressure cuff purportedly ruptured the sterile abscess in her deltoid document “no focal mass/induration/erythema appreciated.” Ex. 2 at 141. While swelling and redness may have dissipated after one week, the fact is there is no objective support in the records that Petitioner had a sterile abscess that ruptured.

While the absence of skin change in Petitioner’s case does not eliminate the possibility that she had a DTH reaction to the vaccine that caused the formation of a sterile abscess, it does make this outcome much less likely.

3. There is not Preponderant Evidence that Petitioner Developed a Nerve Injury Due to a Lump in the Deltoid

Although it may be possible for a sterile abscess to cause a nerve injury, there is not preponderant evidence this happened in Petitioner’s case. Dr. Holzer opined that “[t]he presence

of the mass in her upper arm was causing increased pain and neurological weakness in a pattern indicating that she was experiencing compression of larger nerves.”<sup>19</sup> Second Holzer Rep. at 7.

Dr. Taber, Petitioner’s neurologist, did not associate the paresthesias in Petitioner’s left arm with the lump she described bursting after her blood pressure check. Dr. Taber noted that “the paresthesias in the left arm also raise the possibility of an underlying cervical radiculopathy.”<sup>20</sup> Ex. 3 at 23. A cervical radiculopathy involves nerve roots of the neck and is not consistent with a lump in the deltoid causing a compression nerve injury. Dr. Ring agreed, opining that Petitioner’s “symptoms of ‘tingling’ are not related to shoulder problems such as adhesive capsulitis or rotator cuff tendinopathy.” Ring Rep. at 2-3.

Dr. Boos remarked that there is no mention of “neurological sequelae following the development of subcutaneous nodules or sterile abscesses” in any of the medical literature filed by Petitioner. First Boos Rep. at 5. According to Dr. Boos, this suggests that “vaccine-induced subcutaneous nodules or hypersensitivity reactions do not commonly cause neurologic findings.” *Id.*

Also, left unexplained is why Petitioner still had pain and sensory symptoms after the purported sterile abscess burst. For example, patient 1 from the Lifchez article (the only piece of medical literature filed in the record which discusses the development of sensory symptoms due to cyst growth) experienced “rapid recovery” of radial nerve sensation after the lesion compressing his radial nerve was surgically excised. Lifchez at 153. After the purported lump in her deltoid burst on May 10, 2016, Petitioner described that her pain increased. She stated, “On May 17, 2016, I returned to my primary care doctor to complain about my arm pain, which had only become worse.” Ex. 6 at 2. She continued, stating, “Throughout the summer, I tried to do the exercises, but my level of pain was so great that many days it was impossible to move my arm at all.” *Id.* On September 29, 2016, Petitioner told Dr. Taber that she had been experiencing pins and needles in the hand and all her fingers starting in May “intermittent, unchanged since onset.” Ex. 3 at 19.

---

<sup>19</sup> I note that Dr. Holzer did not discuss which nerve Petitioner’s purported lump was compressing. It is not persuasive to describe nerve compression generally without linking Petitioner’s symptoms in this case with the compression of a specific nerve. *See e.g., Kirby v. Sec’y of Health & Hum. Servs.*, No. 16-185V, 2019 WL 6336026 at \*14-15 (Fed. Cl. Spec. Mstr. Nov. 1, 2019) (discussing the improper administration of a vaccine needle impacting the radial nerve which caused expected symptoms along the radial nerve distribution), *rev’d*, 148 Fed. Cl. 530, *rev’d*, 997 F.3d 1378 (Fed. Cir. 2021); *Small v. Sec’y of Health & Hum. Servs.*, No. 15-478V, 2019 WL 6463985 at \*9 (Fed. Cl. Spec. Mstr. Nov. 1, 2019) (describing Petitioner’s theory that the vaccine needle could strike the axillary nerve with resulting symptoms ending above the elbow), *mot. for review den’d*, 2020 WL 918799 (Fed. Cl. 2020). Dr. Holzer’s failure to discuss which nerve was impacted by Petitioner’s sterile abscess, and how her symptoms fit within the expected nerve distribution pattern further reduces the weight of his opinion concerning this issue.

<sup>20</sup> Cervical means “pertaining to the neck.” *Cervical*, Dorland’s Online Med. Dictionary, <https://www.dorlandsonline.com/dorland/definition?id=8793&searchterm=cervical> (last accessed Aug. 29, 2022). A radiculopathy is a “disease of the nerve roots, such as from inflammation or impingement by a tumor or a bony spur.” *Radiculopathy*, Dorland’s Online Med. Dictionary, <https://www.dorlandsonline.com/dorland/definition?id=42742&searchterm=radiculopathy> (last accessed Aug. 29, 2022).

Petitioner reported sensory changes which Dr. Holzer has attributed to the slow growth of a sterile abscess which caused a nerve injury. However, Petitioner's own reports of symptoms is not consistent with Dr. Holzer's theory.<sup>21</sup> She did not report the slow growth of the lump in her deltoid, and she did not report resolution of her symptoms after the lump burst in May of 2016.

4. There is not Preponderant Evidence that the Placement of a Blood Pressure Cuff on Petitioner's Arm Ruptured a Purported Lump in her Deltoid

I further note that Petitioner has not addressed how the placement of a blood pressure cuff on the arm would cause a sterile abscess at the site of vaccination, in the deltoid, to rupture.

Dr. Holzer noted that "excessive cuff pressure can cause adverse events including pain, skin discoloration, and acute nerve injury; however, injuries are generally mild and transient." Second Holzer Rep. at 7. He cited to the Elmatite article in support of this opinion. While Elmatite et al., described a case report where a patient presumably experienced a nerve injury due to inflation of the automatic blood pressure cuff, this article does not describe the bursting of a sterile abscess at a different location than where the cuff was applied. Dr. Holzer posited that "[C.V.] apparently suffered an acute nerve injury from the trauma caused by the tourniquet effect of an automatic blood pressure cuff compressing a subcutaneous nodule on her upper extremity at the injection site." *Id.* Dr. Holzer did not explain how pressure from a blood pressure cuff causes the rupture of a lump at a different location on the arm. None of the literature filed in this case addresses this issue.

Dr. Boos noted that a blood pressure cuff could rupture a lump in the arm "if [it] was placed directly over such a lump..." Boos Response to Questions at 3. However, he opined that "it is unlikely that a blood pressure cuff placed on her upper arm, distal to the site of vaccination, caused something to rupture at that site." *Id.* Dr. Boos' opinion is persuasive on this point.

5. Dr. Han's Opinion does not Provide Persuasive Evidence in Support of *Althen* Prong Two

In weighing evidence, special masters are expected to consider the views of treating doctors. *Capizzano*, 440 F.3d at 1326. The views of treating doctors about the appropriate diagnosis are often persuasive because the doctors have direct experience with the patient whom

---

<sup>21</sup> Dr. Holzer stated that "[C.V.] continued to experience increasing pain and reported that her symptoms began to include weakness and numbness, causing her to seek medical treatment. This is likely due to the slow growth of the subcutaneous nodule." First Holzer Rep. at 6. However, during her visit with Dr. Taber, Petitioner reported that after she received her Tdap vaccine, she "developed a lump the size of a golf ball which moved around for about six months" and then burst after a blood pressure cuff was applied. Ex. 3 at 19. This description does not support Dr. Holzer's theory that the development of the lump was slow. Petitioner received her Tdap vaccine on December 5, 2015. According to her, the golf ball sized lump moved around for six months until it burst on May 10, 2016. Although the gap between these dates is only five months, her statement to Dr. Taber indicates that the purported golf ball-sized lump developed close-in-time to her vaccination.

they are diagnosing. See *McCulloch v. Sec’y of Health & Hum. Servs.*, No. 09-293V, 2015 WL 3640610, at \*20 (Fed. Cl. Spec. Mstr. May 22, 2015).

Dr. Han wrote a letter on behalf of Petitioner. Her letter reads as follows:

[C.V.] is a patient under my medical care. She received the Tdap vaccine in the left upper arm 12/5/15 and had subsequent onset of left arm pain and paresthesias. She was seen in the office for this 5/17/16 and reported waiting because she assumed her symptoms would resolve on their own. [C.V.] is a reliable historian of her health and symptoms and there is warranted concern that her symptoms were related to the vaccination.

Ex. 11. Dr. Han’s statement that “there is a warranted concern” that Petitioner’s symptoms were related to her vaccination is some evidence that provides marginal support for Petitioner’s case. However, Dr. Han did not provide any additional information to support this statement. She did not conclude that the Tdap vaccine likely did cause Petitioner’s condition, and she did not articulate a theory of causation. Under these circumstances, although I have considered Dr. Han’s opinion, I have not given it great weight.

In sum, there is no direct evidence of any of the following components of Dr. Holzer’s theory in this case: that Petitioner experienced a hypersensitivity reaction to the aluminum component of her Tdap vaccine; that Petitioner developed a sterile abscess at the site of vaccination; that Petitioner’s sterile abscess sat on a large nerve causing her to sustain a nerve injury; or that the rupture of Petitioner’s sterile abscess caused additional nerve injury “mimicking the early stages of frozen shoulder.” Second Holzer Rep. at 7. Indeed, many of these pieces of Petitioner’s theory constitute pure conjecture. The Federal Circuit in *Capizzano* noted that “[t]he second prong of the Althen ... test is not without meaning.” *Capizzano*, 440 F.3d at 1327. For the reasons discussed in this decision, I find that Petitioner has failed to preponderantly demonstrate that her Tdap vaccine “did cause” her condition.

#### **D. *Althen* Prong Three**

The timing prong contains two parts. First, a petitioner must establish the “timeframe for which it is medically acceptable to infer causation” and second, she must demonstrate that the onset of the disease occurred in this period. *Shapiro v. Sec’y of Health & Hum. Servs.*, 101 Fed. Cl. 532, 542-43 (2011), *recons. denied after remand on other grounds*, 105 Fed. Cl. 353 (2012), *aff’d without op.*, 503 F. App’x 952 (Fed. Cir. 2013).

Petitioner’s theory of the case is premised on the fact that she developed a sterile abscess as a direct result of her Tdap vaccine. As discussed in this decision, I do not find there is preponderant evidence that Petitioner developed a vaccine-induced sterile abscess that burst after application of a blood pressure cuff. Because of this, I cannot conclude that the onset of Petitioner’s condition occurred during the “timeframe for which it is medically acceptable to infer causation.” Petitioner has not presented preponderant evidence with respect to the third *Althen* prong.

## VII. CONCLUSION

Upon careful evaluation of all the evidence submitted in this matter, including the medical records, medical literature, the affidavits, as well as the experts' opinions, I conclude that Petitioner has not shown by preponderant evidence that she is entitled to compensation under the Vaccine Act. **Her petition is therefore DISMISSED. The clerk shall enter judgment accordingly.**<sup>22</sup>

**IT IS SO ORDERED.**

**s/ Katherine E. Oler**  
Katherine E. Oler  
Special Master

---

<sup>22</sup> Pursuant to Vaccine Rule 11(a), the parties may expedite entry of judgment by each filing (either jointly or separately) a notice renouncing their right to seek review.