

In the United States Court of Federal Claims

OFFICE OF SPECIAL MASTERS

Filed: April 25, 2022

MARY M. SCHOELLER,

*

Unpublished

*

Petitioner,

*

No. 17-111V

*

v.

*

Special Master Gowen

*

SECRETARY OF HEALTH
AND HUMAN SERVICES,

*

Finding of Fact; Measles-Mumps-Rubella
(MMR); Vaccine Administration Method;
Onset of pain.

*

*

Respondent.

*

John F. McHugh, Law Office of John McHugh, New York, NY, for petitioner.

Tyler King, U.S. Dept. of Justice, Washington, D.C., for respondent.

FINDING OF FACT¹

On January 25, 2017, Mary M. Schoeller (“petitioner”) filed a petition for compensation in the National Vaccine Injury Compensation Program.² Petition (ECF No. 1). Petitioner alleges that as a result of receiving a measles-mumps-rubella (“MMR”) vaccine administered in her left arm on February 11, 2014, she developed pain and reduced range of motion which lasted for more than six months. Amended Petition at Preamble. The following findings of fact pertain to the administration of the MMR vaccine and the onset of petitioner’s pain.

¹ Pursuant to the E-Government Act of 2002, see 44 U.S.C. § 3501 note (2012), **because this opinion contains a reasoned explanation for the action in this case, I intend to post it on the website of the United States Court of Federal Claims.** The Court’s website is at <http://www.uscfc.uscourts.gov/aggregator/sources/7>. Before the opinion is posted on the Court’s website, each party has 14 days to file a motion requesting redaction “of any information furnished by that party: (1) that is a trade secret or commercial or financial in substance and is privileged or confidential; or (2) that includes medical files or similar files, the disclosure of which would constitute a clearly unwarranted invasion of privacy.” Vaccine Rule 18(b). An objecting party must provide the Court with a proposed redacted version of the opinion. *Id.* **If neither party files a motion for redaction within 14 days, the opinion will be posted on the Court’s website without any changes. *Id.***

² The National Vaccine Injury Compensation Program is set forth in Part 2 of the National Childhood Vaccine Injury Act of 1986, Pub. L. No. 99-660, 100 Stat. 3755, codified as amended, 42 U.S.C. §§ 300aa-10 to 34 (2012) (hereinafter “Vaccine Act” or “the Act”). Hereinafter, individual section references will be to 42 U.S.C. § 300aa of the Act.

I. Relevant Procedural History

This case was originally assigned to the Special Processing Unit (“SPU”), which is designed to quickly process and resolve cases. SPU Initial Order (ECF No. 5). Petitioner filed accompanying medical records on January 30, 2017. Petitioner (“Pet.”) Exhibits (“Exs.”) 1-7.

On June 22, 2017, respondent filed a status report stating that he intends to defend against petitioner’s claim. Respondent (“Resp.”) Status Report (ECF No. 12). On August 1, 2017, respondent filed the Rule 4(c) report. Resp. Report (“Rep’t.”) (ECF No. 17). Most relevant to this finding of fact, respondent stated that petitioner received the MMR vaccine, which is administered subcutaneously and not intramuscularly, therefore, her claim does not fit the SIRVA Table criteria. Resp. Rep’t. at 7. Respondent also argued that petitioner did not develop left shoulder pain within forty-eight hours of vaccine administration. *Id.* Respondent also argued that even if petitioner alleged a causation-in-fact claim, she has not met her burden by demonstrating the three prongs of the *Althen* test by preponderant evidence. *Id.* at 8.

After reviewing the respondent’s Rule 4(c) report, the Chief Special Master reassigned the case to my docket on August 4, 2017. Order Reassigning Case (ECF No. 18). I held an initial status conference with the parties on September 7, 2017, during which I ordered the parties to file medical expert reports. Scheduling Order (ECF No. 20).

Petitioner filed an expert report from Dr. Sohail Ahmed on November 14, 2017. Pet. Ex. 8 (ECF No. 23). On January 10, 2018, respondent filed an expert report from Dr. Neil Romberg. Resp. Ex. A (ECF No. 25). After a status conference on February 26, 2018, I directed petitioner to file a supplemental affidavit and a responsive expert report. Scheduling Order (ECF No. 26).

On April 24, 2018, petitioner filed her first supplemental affidavit. Pet. Ex. 11. Petitioner filed a third affidavit on September 11, 2018, and a supplemental expert report from Dr. Ahmed. Pet. Exs. 16 & 17 (ECF Nos. 33). Petitioner also submitted an affidavit from Ms. Carmen Woods, a colleague of petitioner. Pet. Ex. 18 (ECF No. 36).

After engaging in unfruitful settlement negotiations, respondent requested a hearing to be set for July 20, 2021. Hearing Order (ECF No. 55). Petitioner also filed an affidavit from Ms. Julia Skalmoski, another colleague of petitioner. (ECF No. 73). Both parties also filed pre-hearing briefs. *See* Pet. Brief (ECF No. 72); Resp. Brief (ECF No. 78).

A fact hearing was held via videoconference on July 20, 2021. The witnesses were petitioner, Mr. Michael Schoeller, Ms. Julia Skalmoski, and Ms. Jessica Anibas. At the end of the fact hearing, I concluded that petitioner’s onset of pain in the left shoulder began within forty-eight hours of receiving the MMR vaccination and that the vaccination was inadvertently mis-administered, resulting in petitioner’s shoulder pain. Tr. 47-54. After engaging in settlement negotiations, the parties requested I issue a written finding of fact regarding the administration of the vaccine at issue and onset of petitioner’s pain. Status Rept. (ECF No. 85).

II. Legal Standard

Pursuant to Vaccine Act § 13(a)(1)(A), a petitioner must prove, by a preponderance of the evidence, the matters required in the petition by Vaccine Act § 11(c)(1). A special master must consider, but is not bound by, any diagnosis, conclusion, judgment, test result, report, or summary concerning the nature, causation, and aggravation of petitioner's injury or illness that is contained in a medical record. § 13(b)(1). "Medical records, in general, warrant consideration as trustworthy evidence. The records contain information supplied to or by health professionals to facilitate diagnosis and treatment of medical conditions. With proper treatment hanging in the balance, accuracy has an extra premium. These records are also generally contemporaneous to the medical events." *Curcuras v. Sec'y of Health & Human Servs.*, 993 F.2d 1525, 1528 (Fed. Cir. 1993).

Accordingly, where medical records are clear, consistent, and complete, they should be afforded substantial weight. *Lowrie v. Sec'y of Health & Human Servs.*, No. 03-1585V, 2005 WL 6117475, at *20 (Fed. Cl. Spec. Mstr. Dec. 12, 2005). However, this rule does not always apply. In *Lowrie*, the special master wrote that "written records which are, themselves, inconsistent, should be accorded less deference than those which are internally consistent." *Lowrie*, at *19.

The United States Court of Federal Claims has recognized that "medical records may be incomplete or inaccurate." *Camery v. Sec'y of Health & Human Servs.*, 42 Fed. Cl. 381, 391 (1998). The Court later outlined four possible explanations for inconsistencies between contemporaneously created medical records and later testimony: (1) a person's failure to recount to the medical professional everything that happened during the relevant time period; (2) the medical professional's failure to document everything reported to her or him; (3) a person's faulty recollection of the events when presenting testimony; or (4) a person's purposeful recounting of symptoms that did not exist. *La Londe v. Sec'y of Health & Human Servs.*, 110 Fed. Cl. 184, 203-04 (2013), *aff'd*, 746 F.3d 1335 (Fed. Cir. 2014).

The Court has also said that medical records may be outweighed by testimony that is given later in time that is "consistent, clear, cogent, and compelling." *Camery*, 42 Fed. Cl. at 391 (citing *Blutstein v. Sec'y of Health & Human Servs.*, No. 90-2808, 1998 WL 408611, at *5 (Fed. Cl. Spec. Mstr. June 30, 1998)). The credibility of the individual offering such testimony must also be determined. *Andreu v. Sec'y of Health & Human Servs.*, 569 F.3d 1367, 1379 (Fed. Cir. 2009); *Bradley v. Sec'y of Health & Human Servs.*, 991 F.2d 1570, 1575 (Fed. Cir. 1993).

The special master is obligated to fully consider and compare the medical records, testimony, and all other "relevant and reliable evidence contained in the record." *La Londe*, 110 Fed. Cl. at 204 (citing § 12(d)(3); Vaccine Rule 8); *see also Burns v. Sec'y of Health & Human Servs.*, 3 F.3d 415, 417 (Fed. Cir. 1993) (holding that it is within the special master's discretion to determine whether to afford greater weight to medical records or to other evidence, such as oral testimony surrounding the events in question that was given at a later date, provided that such determination is rational).

III. Evidence Submitted

1. Medical records

On February 11, 2014, petitioner received an MMR vaccine from her employer. Pet. Ex. 2 at 4. The vaccine consent form for the MMR vaccine indicates that the vaccine was to be administered in petitioner's left arm "Sub Q." *Id.* at 3. The vaccine administrator was Ms. Jessica Anibas.³ *Id.* Ms. Anibas filled out the manufacturer name and lot number, along with the vaccine expiration date. *Id.*

On April 15, 2014, petitioner had an appointment with her family doctor, Gail Carels M.D. Pet. Ex. 3 at 5. Petitioner reported that she had an MMR vaccine in the left arm on February 11th and that she was experiencing arm and shoulder pain. *Id.* Petitioner stated that she had reported this to work, where she received the vaccination, and she denied any cervical strain or injury. *Id.* Dr. Carels recorded that ibuprofen has helped relieve some of the symptoms but applying heat does not help. *Id.* Dr. Carels wrote that petitioner had "shoulder point tenderness biceps insertion," and assessed petitioner with "shoulder strain, biceps tendonitis?" *Id.* at 5. Dr. Carels recommended that petitioner use non-steroid anti-inflammatory medication, exercise, and seek an orthopedist if her shoulder does not improve. *Id.*

On May 5, 2014, petitioner sent an electronic message to Dr. Carels and wrote, "It does seem somewhat better, but not totally gone...There are certain things that still bother it, and sometimes when I wake up it is sore-probably from sleeping on it." Pet. Ex. 3 at 42. Petitioner stated that she wanted to wait a few more weeks before seeing an orthopedist and asked if there were certain activities she should avoid, like picking up her son or doing kick boxing and karate on the Wii Fit. *Id.* Petitioner also asked if she should continue using Naproxen. *Id.* Dr. Carels responded that petitioner can continue Naproxen for another week and to avoid karate and boxing activities. *Id.*

On August 1, 2014, petitioner sent an electronic message to Dr. Carels, stating that she was "Still having issues with my shoulder that never resolved-probably about 90% better but still certain activities that make it hurt." Pet. Ex. 3 at 41. Petitioner reported that she started exercises again, but little had changed. She wondered if it was "time for an orthopedic referral." *Id.* Dr. Carels referred the petitioner to an orthopedist. *Id.* at 39.

Petitioner had an appointment with orthopedist, Dr. Rory Obama on August 8, 2014. Pet. Ex. 3 at 21. Under "History of Present Illness," Dr. Obama wrote, "[Petitioner] is a 47-year-old female who has had progressive left shoulder pain since she had an MMR vaccine done at work at St. Elizabeth's Hospital a few months ago. Pain is 4-5 out of 10, throbbing pain. She has been doing some home therapy and Naproxen." *Id.* During the physical exam, petitioner demonstrated a slight decrease in active forward flexion in her left shoulder compared to her right, but she had a "painful arc on the left, negative on the right." *Id.* Dr. Obama opined that petitioner, "Likely developed a mild adhesive capsulitis after this MMR injection and now has some inflammation there as well." *Id.* Dr. Obama recommended petitioner have physical therapy to improve range of motion and strength. *Id.*

³ At the time of vaccine administration, Ms. Anibas was using her maiden name, Ms. Jessica Ebsch. Tr. 31.

Petitioner had an initial physical therapy evaluation on August 19, 2014. Pet. Ex. 3 at 141. Under “Mechanism of Injury” it stated, “Onset of shoulder pain after [patient] had MMR vaccination in left arm.” *Id.* Petitioner complained that she had pain located in the lateral aspect of her left arm/shoulder and explained that she had difficulty reaching behind herself, throwing or hitting a ball, leaning on her left elbow, swimming, and sleeping on the left side. *Id.* The physical exam showed petitioner has a slight reduction in range of motion compared to her right arm in flexion, abduction, and external rotation. *Id.* at 142. Petitioner also had tenderness to palpation at the supraspinatus and infraspinatus insertion and her left shoulder strength was also slightly reduced. *Id.* She was assessed with “signs and symptoms consistent with decreased left shoulder mobility and supraspinatus strength.” *Id.* It was recommended that she participate in physical therapy twice a week for four weeks. *Id.* At a physical therapy appointment on September 8, 2014, petitioner stated that her shoulder was feeling a lot better with occasional twinges of pain with end range movements and she felt that her range of motion is improved. *Id.* at 155. On September 19, 2014, at another physical therapy appointment, petitioner reported she was still experiencing pain, but at its worst was a 2/10 and that her shoulder was “much improved from the start of PT.” *Id.* at 159.

Petitioner had a follow-up appointment with Dr. Obama on September 22, 2014, for “left shoulder pain.” Pet. Ex. 3 at 19. Under “History of Present Illness,” it was noted that petitioner’s left shoulder pain began after receiving an MMR vaccine. *Id.* Petitioner reported that she was 90-95% better, but still had some difficulty with abduction. *Id.* Petitioner rated her pain at a 3 to 4 out of 10. *Id.* In the physical exam, petitioner’s internal active shoulder rotation was to T10 on the right and to T7 on the left shoulder. Petitioner also had 5/5 rotator cuff strength bilaterally. *Id.* She was diagnosed with “resolving to resolved shoulder pain.” *Id.*

On August 12, 2015, petitioner sought treatment from orthopedist, Dr. Shawn Hennigan. Pet. Ex. 5 at 3. The date of injury was recorded as “2/11/2014.” *Id.* Petitioner reported that her left shoulder pain began in February 2014 after she received a subcutaneous MMR vaccine. *Id.* Petitioner stated that her shoulder was “tight and sore,” since the vaccination and the pain is centralized to the top of her shoulder. *Id.* During the physical exam of petitioner’s shoulders, petitioner had pain to palpation over the anterolateral acromion of the left shoulder and it was recorded that her “acromioclavicular joints are painful on the left.” *Id.* at 5. Petitioner also had positive Neers impingement and Hawkins tests. *Id.* Petitioner was diagnosed with “left shoulder pain following work required vaccination (MMR) left deltoid; A.C. joint symptoms, subacromial pain.” *Id.* Dr. Hennigan recommended petitioner have an MRI of her shoulder. *Id.*

On August 26, 2015, petitioner had an MRI of her left shoulder. Pet. Ex. 20. The MRI revealed petitioner had a mild increased T2 signal in the distal supraspinatus consistent with tendinopathy, but no rotator cuff tear; subtle increased T2 signal intensity in the superior labrum that was suspected intrasubstance degeneration or non-displaced tearing; and trace fluid was seen in the subacromial/subdeltoid space. *Id.* at 1-2.

Petitioner had an appointment with Dr. Hennigan on August 26, 2015, to review her MRI. Pet. Ex. 5 at 10. Dr. Hennigan wrote, “In reviewing the study, there is significant subdeltoid fluid in the bursa. There is a lateral acromion spur, small anterior inferior acromion

spur, marked A.C. joint arthrosis, supraspinatus tendinosis, but no significant tear, and probable displaced SLAP tear noted.” *Id.* Petitioner opted for a subacromial steroid injection and a physical therapy “refresher.” *Id.* at 10.

Petitioner re-started physical therapy on August 31, 2015. Pet. Ex. 6 at 4. Under “Description of Onset,” it was recorded that petitioner had an MMR injection on February 11, 2014, and that “in the next day or two shoulder was extremely sore,” and that petitioner had a hard time reaching overhead or backward. *Id.* Petitioner reported that her pain had been reduced with prior physical therapy and that her pain level was now at a 3 out of 10. *Id.* Petitioner had seven physical therapy appointments. *Id.* at 49. At her appointment on September 25, 2015, petitioner reported that her pain was a 2 out of 10 and it was noted that her active range of motion for her left shoulder was “within normal limits.” *Id.* The record indicated that petitioner had met her goals of physical therapy. *Id.* at 51.

2. Petitioner’s Affidavits and Testimony

In her first affidavit, petitioner stated that the vaccine was given “in the upper portion of my left shoulder. I remember feeling as if the vaccine was given higher up in my shoulder than usual.” Pet. Affidavit (“Aff.”) at ¶ 4. She stated that she was sitting in an office chair and the nurse, Ms. Jessica Anibas was standing/squatting next to me. *Id.* at ¶ 3. Petitioner stated that she did not recall the angle of vaccine administration, but thought it was “somewhat unusual given the fact that I was sitting in a shorter chair, and the nurse was standing/squatting next to me.” *Id.* at ¶ 6. Petitioner stated she the next day she was “experiencing much more pain than I should for an MMR vaccine.” *Id.* at ¶ 8. Petitioner also stated that she did not have any external symptoms, only an unusual amount of pain. *Id.* at ¶ 9. The pain remained constant throughout February and March, until she finally had her shoulder evaluated in April. *Id.* at ¶ 10.

In her supplemental affidavit, petitioner stated, “I remember that the vaccine was given higher up on my shoulder than normal, and not in my triceps. I do not remember the nurse squeezing or bunching the skin before the injection, but I do remember her placing her free hand on my arm/shoulder for support while giving the vaccination.” Pet. Supp. Affidavit (“Aff.”) at ¶ 3. Additionally, petitioner stated that she had a band-aid on her “left, upper shoulder/deltoid,” and that she noticed this band-aid in the bathroom mirror the following day. *Id.* at ¶ 4. During the hearing, petitioner explained that she remembered getting out of the shower and noticing the band-aid on the upper area of her left arm. Tr. 23.

Petitioner testified that she remembers receiving the MMR vaccine on February 11, 2014. Tr. 6. She testified that when it came time to administer the vaccine, the nurse, Ms. Anibas, approached her left side and “crouch[ed] down to administer the vaccine.” *Id.* Petitioner stated that she “felt it go into my left shoulder, and it pinched a little.” *Id.* She explained that the vaccine was given in her upper shoulder area, approximately one to two inches below the acromion. Tr. 17. Petitioner testified that her shot was given up higher than flu shots she received. Tr. 19. Petitioner also explained that she does not remember the nurse squeezing or bunching the skin prior to receiving the injection, but she also stated that she typically turns her head or closes her eyes when receiving the vaccination. Tr. 17, 21.

3. Testimony of Ms. Jessica Anibas

Ms. Anibas testified that she had been a registered nurse for thirteen years. Transcript (“Tr.”) 32. She testified that she had been trained by her employer on how to administer vaccines. Tr. 35. Ms. Anibas stated that she was instructed on the guidelines for administering vaccines and then observed to ensure that she was administering them correctly. *Id.* She explained, “An MMR vaccine is administered subcutaneously in the upper outer arm, and that was my practice.” Tr. 36. When asked to demonstrate where an MMR vaccine would be administered, she demonstrated that it would be “on the outer aspect-the fatty tissue in the outer aspect of the upper arm,” above the triceps. Tr. 36. Ms. Anibas testified that she stands above a patient, who is sitting, when administering a vaccine. *Id.* Further, Ms. Anibas testified that the MMR vaccine is administered subcutaneously, and it was her “custom and practice” to administer it subcutaneously. *Id.* at 37. Ms. Anibas testified that she would always use a 25-gauge needle that was 5/8” in length and that she “consistently” used this needle size for this type of administration. *Id.*

4. Testimony of Mr. Michael John Schoeller

Mr. Michael Schoeller, husband of petitioner, testified he remembered that in 2014, his wife had to get a vaccine for work. Tr. 40. He testified that the day after the vaccination she was complaining of pain in her arm and that the pain was going through her whole arm. *Id.* Additionally, he had to help her lift her laundry basket up the stairs because she was unable to lift it. *Id.* at 41. He also testified that the petitioner was unable to participate in the family swim event at the local YMCA because her arm hurt too much. *Id.*

5. Testimony of Ms. Julia Skalmoski

Ms. Julia Skalmoski testified that she was a co-worker of petitioner at the time of the vaccine at issue. Tr. 43. She testified that she and petitioner used to sit next to one another at work and that “they talked frequently.” *Id.* at 44. Ms. Skalmoski explained that she and the petitioner worked together for three years. *Id.* at 45. She recalled that the petitioner “mentioned after she received a vaccination at work that she was having quite a bit of arm and shoulder pain.” *Id.* at 44. Additionally, Ms. Skalmoski testified that she knew petitioner was “in a bit of pain,” because the petitioner “mentioned it frequently.” *Id.* Ms. Skalmoski recalled petitioner seeking medical attention and physical therapy for quite a period of time. *Id.*

6. Petitioner’s Expert Report: Dr. Sohail Ahmed

Petitioner submitted three expert reports by orthopedist, Dr. Sohail Ahmed. Pet. Ex. 8, 12 & 17. (ECF Nos. 23, 28, & 33). In his first report, Dr. Ahmed wrote, “Although the MMR vaccine received by petitioner was intended for subcutaneous injection, in my expert opinion it is very likely that it was administered intramuscularly.” Pet. Ex. 8 at 2. Dr. Ahmed stated, “There is very little distance separating the subcutaneous tissue layer from the underlying muscle layer and that is why it is very likely that the MMR vaccine may have been unintentionally administered intramuscularly.” *Id.* at 3. Dr. Ahmed also stated that the medical records confirm that petitioner’s pain occurred within 48 hours. *Id.* at 4. He acknowledged that petitioner waited

to seek treatment for her shoulder pain and wrote, “In my clinical experience, it is not unusual for patients who are experiencing musculoskeletal pain to wait to see if the pain subsides by itself or with conservatory measures before seeking medical attention.” *Id.* Dr. Ahmed noted that petitioner even sent an electronic message to her primary care physician which supported his point, where she wrote, “I think I would like to wait a couple more weeks before going to see an orthopedist.” *Id.* at 5; *see* Pet. Ex. 3 at 40.

In his second report and in response to the Court’s order, Dr. Ahmed stated, “Although the MMR vaccine received by the petitioner was intended for subcutaneous injection, in my expert opinion, it is very likely that it was administered intramuscularly.” Pet. Ex. 12 at 2. He identified five statements made by petitioner that he asserted supported his opinion:

1. MMR immunization was administered in the upper portion of her left shoulder- Petitioner recollects the vaccine as being given higher up in her shoulder than normal.
2. Petitioner noticed pain/pressure that felt to her more like a tetanus vaccination-tetanus vaccines are formulated to be administered intramuscularly.
3. Petitioner woke up the following morning experiencing more pain than the first MMR vaccine she received.
4. Unusual amount of pain noted by petitioner; and
5. Pain that remained constant throughout February and March with evaluation of her shoulder in April.

Id. Dr. Ahmed then cited to an article by Hirsch et al. which examined intramuscular risk for insulin injections, which are administered subcutaneously. Pet. Ex. 13.⁴ The authors measured the distance from the skin surface to muscle fascia by high-frequency ultrasound at certain injection sites. *Id.* at 2. The authors also estimated the risk of intramuscular injection for different length needles and injection angles at the different injection sites. *Id.* at 3. The authors found that with a 12.7 mm needle, the risk for intramuscular injection at a 90-degree angle at the arm was 55% and that at a 45-degree angle, the risk was substantially reduced to 27%, but still higher than any of the other smaller length needles. *Id.* at 3. Dr. Ahmed noted that petitioner’s injection was likely given using a 5/8” inch or 15.875 mm, and he stated that this needle length “further increases risk of intramuscular injection.” Pet. Ex. 12 at 3. During the hearing, Ms. Anibas confirmed that she usually used a 5/8 inch needle for the MMR vaccination

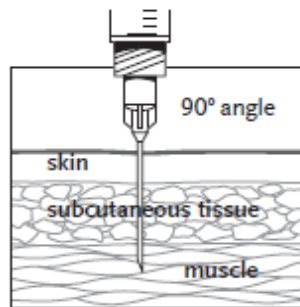
Dr. Ahmed also cited to a fact sheet that explains how to administer intramuscular and subcutaneous vaccine injections to adults. Pet. Ex. 10.⁵ The article explains that a medical provider can administer a vaccine intended for intramuscular route, such as the tetanus,

⁴ Hirsch, L. et al., *Intramuscular Risk at Insulin Injection Sites-Measurement of the Distance from Skin to Muscle and Rationale for Shorter-Length Needles for Subcutaneous Insulin Therapy*, 16 *Diabetes Technology & Therapeutics*, 867-873 (2014). [Pet. Ex. 13].

⁵ *How to Administer Intramuscular and Subcutaneous Vaccine Injections to Adults*, at www.immunize.org. Immunization Action Coalition. [Pet. Ex. 10]. The Centers for Disease Control and Prevention (CDC) “work[s] in concert and provide[s] financial support” to this coalition, which runs several websites. The website cited by respondent is intended as a “non-profit web-based resource” for healthcare professionals. *See* Immunization Action Coalition, *About Us*,

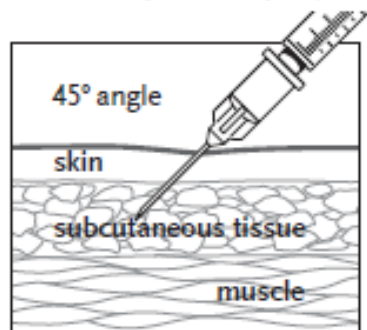
diphtheria with pertussis (“Tdap”) or the hepatitis A&B vaccines, “using a needle long enough to reach deep into the muscle; insert the needle at a 90-degree angle to the skin with a quick thrust; and that a 22-25 gauge needle is appropriate for administration. *Id.* at 1. The injection should be made into the deltoid muscle of the arm and should resemble the illustration below:

Intramuscular (IM) injection



Id. In contrast, a medical provider administering a *subcutaneous* (SQ) injection should use a 23-25-gauge needle. Pet. Ex. 10. The proper needle length is always 5/8”, regardless of the vaccinee’s weight or any other factors. *Id.* The injection should be made into the back of the arm, between the acromion and elbow, and should resemble the illustration below:

Subcutaneous (SubCut) injection



Pet. Ex. 10. Additionally, the needle should be inserted by pinching up on the tissue to prevent injection into the muscle, at a 45-degree angle to the skin. *Id.*

Dr. Ahmed wrote, “As can be seen in this exhibit, the 5/8” needle length can be used for either intramuscular or subcutaneous injections. What one can appreciate from this illustration is that there is the possibility for overlap between the recommended zones for where each injection is made. Also, one should appreciate the relationship of the skin, subcutaneous tissue and muscle layers to the entering needle. Whether an injection is intramuscular or subcutaneous is related to the angle that the very needle is injected at and also the depth that can vary in different people.” *Id.* at 3. He stated, “There is very little distance separating the subcutaneous tissue layer from the underlying muscle layer and is why it is very likely that the MMR vaccine may have unintentionally been administered intramuscularly to the petitioner.” *Id.*

In his third report, Dr. Ahmed reiterated that the needles used for subcutaneous vaccinations are also used for intramuscular injections. Pet. Ex. 17 at 1. He stated that the needles are made of the same material, come in different lengths, and different diameters (known as gauge).” *Id.* He stated that “the risk of accidental intramuscular injection ranged from 24% to 56.3% with a needle of 12.7 mm and still occurred with needles as short as 6 mm.” *Id.* He stated that “the 5/8” needle increases the risk of intramuscular injection beyond 56.3% seen with shorter needles.” *Id.* at 1-2. He opined, “A needle of 5/8” length could reach deep enough to be an intramuscular injection when given in the deltoid based on the angle of administration, the pressure exerted by the hand of the nurse administering the injection to the petitioner, and that the nurse did not “bunch up” the skin when injecting the needle into the deltoid.” *Id.* at 2.

6. Respondent’s Expert Report: Dr. Neil Romberg

Respondent submitted two expert reports from Dr. Neil Romberg. Resp. Ex. A & C (ECF Nos. 25 & 29). Dr. Romberg wrote that, “The records also indicate that the MMR vaccine was administered by a registered nurse to [petitioner’s] left side and into the subcutaneous space.” Resp. Ex. A at 2. Dr. Romberg stated that he “sees no evidence in the submitted records,” to support Dr. Ahmed’s opinion that the vaccine was administered intramuscularly. *Id.* at 4.

Referencing Petitioner’s Exhibit 10, Dr. Romberg observed that subcutaneous vaccines are given in the posterior triceps aspect of the upper arm because “the subcutaneous tissue overlying the triceps is supple enough to be pinched between the fingers, thereby eliminating the possibility of inadvertent intramuscular injection.” *Id.* at 3 (citing Pet. Ex. 10). He also stated that the posterior triceps aspect of the upper arm is located distant to any of the synovial spaces of the shoulder (bursa or joint).

Dr. Romberg acknowledged that petitioner did experience left shoulder pain in 2014 and 2015, however, he asserted that this pain was “unlikely secondary to a subcutaneously injected vaccine,” and that “alternative explanations may better explain her symptoms.” *Id.* at 4. He argued that petitioner had preceding orthopedic pain in her hip, neck and left knee and right foot, and that petitioner’s “left shoulder symptoms are clearly consistent with her extensive past medical history and are unlikely to be vaccine-related.” *Id.* He also posited that petitioner may have had reactive arthritis that was triggered by norovirus gastroenteritis, an illness that was documented to have occurred prior to petitioner’s flu vaccination. *Id.* Dr. Romberg concluded his first report, stating, “[Petitioner’s] vaccine was injected subcutaneously, and I find no reason why the administering nurse would deviate from using the preferred injection site—the posterior triceps aspect of the upper arm. If injected in the posterior triceps aspect of the upper arm, there is no plausible mechanism that would explain how a vaccine could affect the shoulder synovial space and cause SIRVA.” *Id.* at 4.

In his second report, Dr. Romberg asserted that some of the petitioner’s statements Dr. Ahmed relied upon were not in petitioner’s affidavit, cited as Exhibit 4. Resp. Ex. C. However, Dr. Ahmed was actually citing to petitioner’s second supplemental affidavit, Exhibit 11. In petitioner’s second affidavit, she stated, “The vaccine was given in the upper portion of my left shoulder. I remember feeling as if the vaccine was given higher up in my shoulder than usual.”

Pet. Ex. 11 at ¶ 4 (ECF No. 27). Dr. Romberg either selectively decided to ignore petitioner's second affidavit or was not made aware of the it.

Dr. Romberg also criticized Dr. Ahmed's reliance on the Hirsh et al. article, stating that the "preferred anatomic site for insulin injection of the arm is into the fat pad overlying the triceps muscle and not in the shoulder. Thus, all measurements listed in Hirsh et al. pertain to injection into the fat pad of the triceps muscle, not the shoulder [muscles]." Resp. Ex. C at 2. He stated that the observed risk of inadvertent intramuscular injection discussed in the Hirsh article was into the triceps muscle, not the deltoid muscle. *Id.* at 2-3. Dr. Romberg argued that the MMR vaccine, which is recommended to be given subcutaneously in the outer triceps area of the arm, was the likely site of petitioner's vaccination. *Id.* at 3. Further, Dr. Romberg states that Petitioner's Exhibit 10, makes it "very clear that even if the needle was 25 mm long and angled wildly, there is no imaginable scenario where it would enter the deltoid muscle or the shoulder's synovial space." *Id.* at 4.

Dr. Romberg concluded his second report by stating, "It is well-documented in the medical records that [petitioner's] MMR vaccine was injected subcutaneously, and I find no reason why the administering nurse would deviate from the preferred injection site-the fat pad overlying the posterior triceps aspect of the upper arm. Hence, there is no plausible mechanism to explain how a vaccine could affect the shoulder synovial space and cause SIRVA." *Id.*

IV. Discussion of Factual Issues

There are two issues of fact to be resolved. The first is whether petitioner's MMR vaccine was inadvertently or erroneously administered intramuscularly in the shoulder area as opposed to subcutaneously. The second issue is the onset of petitioner's shoulder pain and dysfunction.

A. Vaccine administration

Petitioner has presented preponderant evidence that the February 11, 2014, MMR vaccine was administered high on her left shoulder into and around her shoulder structure, instead of in the posterior aspect of her left arm.

Petitioner explained in her second affidavit that the MMR vaccine she received was "given in the upper portion of my left shoulder. I remember feeling as if the vaccine was given higher up in my shoulder than usual." Pet. Ex. 11 at ¶ 4. Additionally, she stated that she was seated, and the administering nurse was standing/squatting next to her, while administering the vaccine. *Id.* at ¶ 5. This is consistent with the testimony petitioner gave at the hearing, where she stated that the administering nurse, "proceeded to come around her desk and come to my left side and crouch down to administer the vaccine." Tr. 6. When asked if she could identify the location of where the vaccine was administered, petitioner pointed to her upper left shoulder, about an inch or two beneath the end of her acromion. Tr. 17. Petitioner explained that she remembered seeing a band-aid on the upper area of her left shoulder the next day. Tr. 24. Further, petitioner also testified that she does not remember the administering nurse squeezing or bunching the skin before the injection, but petitioner admitted that she did not watch the vaccine get administered into her arm. Tr. 21.

Ms. Anibas, the vaccine administrator, testified that she would administer the MMR vaccine in the “fatty tissue in the outer aspect of the upper arm,” and she demonstrated the area would be “right above her left triceps.” Tr. 36. She also testified that she would typically stand while the patient receiving the vaccine would be seated. *Id.* Further, Ms. Anibas stated that it was her custom and practice to administer the vaccine subcutaneously, using a 25-gauge needle that was 5/8” in length. Tr. 37.

Both petitioner and Ms. Anibas testified that petitioner was seated while she received the MMR vaccination. As discussed in the Atanasoff article, submitted by respondent, “the standing position of the provider administering the injection may also contribute to injecting inadvertently high into the deltoid.” Resp. Ex. A, Tab 2 at 4. When Ms. Anibas was asked how she would administer a subcutaneous vaccination, she did not specifically state that she would “bunch” or “pinch” the skin to administer a subcutaneous injection. Tr. 20. Further, petitioner stated that she did not remember if the vaccine administrator squeezed or bunched her skin prior to administering the vaccine. Pet. Ex 16 at ¶ 4. Instead, petitioner stated that she remembered Ms. Anibas placing her free hand on petitioner’s shoulder for support while giving the vaccination. *Id.* Petitioner’s statement regarding the placement of Ms. Anibas’ free hand makes it more likely that Ms. Anibas did not bunch or squeeze petitioner’s skin while administering the subcutaneous injection.

As it was noted in the fact sheet titled, “How to Administer Intramuscular and Subcutaneous Vaccine Injections to Adults,” it was recommended that the vaccine administrator, “Pinch up on the tissue to prevent injection into the muscle.” *See* Pet. Ex. 10. Further, the article by Hirsch indicated that bunching or pinching the skin can help reduce an inadvertent intramuscular injection. Pet. Ex. 13 at 5-6. Additionally, Dr. Ahmed opined that a needle of 5/8” length, which was the length use to administer the MMR vaccine to petitioner, could inadvertently be administered intramuscularly based on the angle of administration, pressure exerted on the needle, and if the administrator did not “bunch up” the skin when injecting the needle into the deltoid. Pet. Ex. 17 at 2. Thus, it appears more likely that petitioner’s skin was not bunched or folded makes an inadvertent injection into petitioner’s deltoid more likely.

Finally, petitioner’s MRI found fluid in the subacromial/subdeltoid space, which is consistent with other MRI findings documented in post-vaccination shoulder injury cases. The Atansoff article explained that fluid collection in the deep deltoid or fluid “greater than typically seen,” within the bursa were found on MRIs that were performed on some of the shoulder pain and dysfunction patients whose cases were identified in the VICP. Resp. Ex. A, Tab 2 at 3. While the MRI stated that petitioner had “trace” fluid in the subacromial/subdeltoid space, petitioner’s treating physician, Dr. Hennigan reviewed petitioner’s MRI and stated that, “there is significant subdeltoid fluid in the bursa.” Pet. Ex. 5 at 11. Dr. Hennigan apparently interpreted the amount of fluid in the subacromial bursa as a significant finding. Thus, petitioner’s MRI finding is also consistent with a post-vaccination shoulder injury.

As I stated during the hearing, “there is no reason to think that [Ms. Anibas] would have intentionally given the vaccination...the wrong way,” overall, however, the facts demonstrate by preponderant evidence that the MMR vaccine administer to petitioner on February 11, 2014, was

inadvertently administered into or around petitioner's subdeltoid bursa, causing pain and shoulder dysfunction.

B. Onset of petitioner's pain

Respondent argued that petitioner did not demonstrate that the onset of her shoulder pain occurred within forty-eight hours of vaccine administration. Resp. Brief at 11. Respondent argued that petitioner did not report her left shoulder pain "immediately," and waited two months before seeking treatment. *Id.*

After hearing the testimony of petitioner, her husband, and co-worker, in addition to the medical records consistently relating the onset of petitioner's pain and shoulder dysfunction to the February 11, 2014, MMR vaccine, I concluded that petitioner established that the onset of her pain began within 48 hours of receiving the vaccination. Tr. 47-48.

Petitioner testified that the morning following her MMR vaccination on February 11, 2014, her shoulder was "really sore," and that she had trouble moving. Tr. 8. She explained that she had trouble putting her jacket on. *Id.* She stated that her shoulder pain went on for a couple of months before seeking treatment. Tr. 9. In her supplemental affidavit, petitioner stated that "the pain remained constant throughout February, March and finally at the beginning of April 2014." Pet. Ex. 11 at ¶ 10.

Petitioner's former colleague, Ms. Skalmoski, testified that petitioner mentioned that she was "having quite a bit of arm and shoulder pain," after receiving a vaccination at work. Tr. 44. Ms. Skalmoski testified that petitioner's statements regarding her shoulder pain was "within a few days," of the vaccination. *Id.* When she was asked about how long petitioner complained about shoulder pain, Ms. Skalmoski testified that petitioner mentioned her shoulder pain "frequently," and that her pain "went on for quite a period of time." *Id.*

Additionally, petitioner's husband testified that petitioner began to complain of pain in her left shoulder the day following the vaccination. Tr. 41. He stated, "The day after, she was complaining of pain in her arm, and it was going through her whole arm." *Id.* at 40.

The petitioner's statements about the onset of her left shoulder pain were also consistent with the medical record. For example, when petitioner sought treatment on April 15, 2014, petitioner reported that her left arm and shoulder had been painful since the MMR vaccine she received on February 11, 2014. Pet. Ex. 3 at 6. Petitioner also indicated that she had tried using heat and Ibuprofen without much relief. *Id.* When petitioner had an orthopedic consultation with Dr. Obama on August 8, 2014, petitioner again reported that her shoulder pain began "after having an MMR vaccine." Pet. Ex. 3 at 20. Additionally, when petitioner had her first physical therapy appointment evaluation on August 19, 2014, petitioner's "Date of Injury" was recorded as "February 2014," and the "Mechanism of Injury" was documented as, "Onset of shoulder pain after [patient] had MMR vaccination in left arm." Pet. Ex. 3 at 141.

Even though petitioner's first medical appointment regarding her shoulder pain was made nearly eight weeks later, the record is trustworthy as a medical record made contemporaneous to

her treatment, having been created to facilitate a diagnosis and treatment for left shoulder pain. *See e.g. Cooper v. Sec’y of Health & Human Servs.*, No. 16-1378V, 2018 WL 1835179, at *6 (Fed. Cl. Spec. Mstr. Jan. 18, 2016); *see also Cucuras v. Sec’y of Health & Human Servs.*, 993 F.2d 1525, 1528 (Fed. Cir. 1993). Further, the delay in seeking treatment is not necessarily *per se* dispositive as to the onset of a petitioner’s symptoms within the appropriate timeframe. *See Lang v. Sec’y of Health & Human Servs.*, No. 17-995V, 2020 WL 7873272 (Fed. Cl. Spec. Mstr. Dec. 11, 2020). I have found in several post-vaccination shoulder injury cases that onset occurred within the specified timeframe, even with a delay in treatment. *See Sandoval v. Sec’y of Health & Human Servs.*, No. 16-304V, 2019 WL 3820075 (Fed. Cl. Spec. Mstr. July 12, 2019) (finding onset of shoulder pain within forty-eight hours, even though petitioner delayed treatment); *Yost v. Sec’y of Health & Human Servs.*, No. 18-288V, 2021 WL 2326403 (Fed. Cl. Spec. Mstr. May 6, 2021) (finding onset of petitioner’s shoulder pain began within forty-eight hours of the vaccination even though treatment was delayed four months). Petitioner’s expert, Dr. Ahmed, also explained that “it is not unusual for patients who are experiencing musculoskeletal pain to wait to see if the pain subsides by itself or with conservatory measures before seeking medical attention.” Pet. Ex. 8 at 5. He observed that this is what petitioner did in the present case, as petitioner stated in her first affidavit. *Id.*

Apart from petitioner’s initial delay in seeking treatment, respondent did not submit or reference any piece of evidence in the record that is inconsistent with the onset of petitioner’s shoulder pain occurring within forty-eight hours of vaccination.

Consistent with my finding from the hearing, petitioner has established by preponderant evidence that she developed shoulder pain within forty-eight hours of receiving the MMR vaccination on February 11, 2014.

V. Conclusion

A special master’s ruling on entitlement may be delivered from the bench, with no written opinion. *Doe/17 v. Sec’y of Health & Human Servs.*, 84 Fed. Cl. 691, 704 n.18 (2008). A published written decision memorializing a decision from the bench allows the public access to the reasoning underlying the bench decision. *See Heddens v. Sec’y of Health & Human Servs.*, No. 15-734, 2018 WL 5726991 (Fed. Cl. Spec. Mstr. Oct. 5, 2018) (rev. den., 143 Fed. Cl. 193, *Heddens v. Sec’y of Health & Human Servs.* (2019)); *Jaafar, on behalf of A.M. v. Sec’y of Health & Human Servs.*, No. 15-267, 2018 WL 4519066 (Fed. Cl. Spec. Mstr. Aug. 10, 2018). Further, issuing a written decision provides an abbreviated recitation for the basis of decision. *See Hebern v. U.S.*, 54 Fed. Cl. 548 (2002) (example of order affirming bench ruling).

This written finding of fact memorializes the findings that I made after the hearing held on July 20, 2021. Additionally, this written decision provides a recitation and further explanation for the findings I made following the hearing. Consistent with the findings made after the hearing on July 20, 2021, I find that petitioner established by preponderant evidence that the MMR vaccine was inadvertently administered incorrectly, and that petitioner’s shoulder pain began within forty-eight hours of receiving the MMR vaccination on February 11, 2014.

The parties are encouraged to resolve the remainder of this case informally. Therefore, in accordance with the above, the following is hereby **ORDERED**:

- 1) **Within thirty (30) days, by Wednesday, May 25, 2022**, the parties shall file a joint status report indicating if they can re-engage in settlement negotiations.

IT IS SO ORDERED.

s/Thomas L. Gowen
Thomas L. Gowen
Special Master