

In the United States Court of Federal Claims
OFFICE OF SPECIAL MASTERS

No. 16-1164V

Filed: January 3, 2023

* * * * *	*	
MARTIN COWLES,	*	To Be Published
	*	
Petitioner,	*	Dismissal; Ruling on the Record;
v.	*	Influenza (“Flu”) Vaccine; FluMist;
	*	Vestibular Neuritis; Vestibular Migraine.
SECRETARY OF HEALTH	*	
AND HUMAN SERVICES,	*	
	*	
Respondent.	*	
* * * * *	*	

Andrew Downing, Esq., Downing, Allison & Jorgenson, Phoenix, AZ, for petitioner.
Colleen Hartley, Esq., U.S. Department of Justice, Washington, DC, for respondent.

DECISION¹

Roth, Special Master:

On September 20, 2016, Martin Cowles (“Mr. Cowles” or “petitioner”) filed a petition for compensation pursuant to the National Vaccine Injury Compensation Program.² Petitioner alleges that he received a live nasal influenza (“FluMist”) vaccination on October 17, 2013, and thereafter suffered a “severe adverse reaction.”³ See Petition (“Pet.”), ECF No. 1. On December 16, 2019, petitioner filed a Motion for Ruling on the Record. ECF No. 65.

¹ This Decision has been designated “to be published,” which means I am directing it to be posted on the Court of Federal Claims’ website, in accordance with the E-Government Act of 2002, Pub. L. No. 107-347, 116 Stat. 2899, 2913 (codified as amended at 44 U.S.C. § 3501 note (2006)). **This means the Decision will be available to anyone with access to the internet.** However, the parties may object to the Decision’s inclusion of certain kinds of confidential information. Specifically, under Vaccine Rule 18(b), each party has fourteen days within which to request redaction “of any information furnished by that party: (1) that is a trade secret or commercial or financial in substance and is privileged or confidential; or (2) that includes medical files or similar files, the disclosure of which would constitute a clearly unwarranted invasion of privacy.” Vaccine Rule 18(b). Otherwise, the whole Decision will be available to the public. *Id.*

² National Childhood Vaccine Injury Act of 1986, Pub. L. No. 99-660, 100 Stat. 3755. Hereinafter, for ease of citation, all “§” references to the Vaccine Act will be to the pertinent subparagraph of 42 U.S.C. § 300aa (2012).

³ The petition describes petitioner’s alleged injury as an “adverse reaction” but does not specify a diagnosis. Rather, the petition notes that petitioner suffered from episodes of dizziness and at one point received a diagnosis of “possible viral labyrinthitis.” Pet. at 2. Petitioner’s medical records reflect that he was eventually diagnosed with vestibular migraine. See Pet. Ex. 4 at 122. One of petitioner’s experts opined that he suffers from vestibular neuritis. See Pet. Ex. 13, 69, 75.

Petitioner alleges that he suffered from vestibular neuritis as a result of the FluMist vaccine. However, after careful review of the record, the evidence demonstrates that petitioner suffers from vestibular migraines. Petitioner did not provide any support for vaccine-induced vestibular migraines and therefore is unable to show that the FluMist vaccine caused his injury. Thus, I find that petitioner has failed to carry his burden and the petition is accordingly dismissed.

I. Procedural History

The petition was filed on September 20, 2016. Petition, ECF No. 1. Petitioner filed an affidavit and medical records on September 27, 2016 and a Statement of Completion on October 18, 2016. Petitioner's Exhibits ("Pet. Ex.") 1-9, ECF No. 5; Statement of Completion, ECF No. 7. On February 2, 2017, respondent filed his Rule 4(c) Report, stating that this matter was not appropriate for compensation. ECF No. 9. Petitioner filed a supplemental affidavit on February 6, 2017 as Pet. Ex. 10. ECF No. 10.

Petitioner filed an expert report and CV from his expert immunologist, Dr. Vincent Tuohy, on May 15, 2017 and an expert report and CV from his expert otolaryngologist, Dr. George Hicks. Pet. Ex. 11-12, ECF No. 14; Pet. Ex. 13-14, ECF No. 15. Petitioner filed supporting medical literature from Dr. Hicks on July 26, 2017. Pet. Ex. 31-40, ECF No. 27; Pet. Ex. 41-50, ECF No. 28; Pet. Ex. 51-60, ECF No. 29; Pet. Ex. 61-67, ECF No. 30. Petitioner filed supporting medical literature from Dr. Tuohy on August 7, 2017. Pet. Ex. 15-24, ECF No. 31; Pet. Ex. 25-30, ECF No. 32.

Respondent filed expert reports, CVs, and supporting medical literature from his expert otorhinolaryngologist, Dr. Douglas Bigelow, and his expert immunologist, Dr. Kathleen Collins. Resp. Ex. A, Tabs 1-8, Resp. Ex. B, ECF No. 36; Resp. Ex. C, Tabs 1-9, ECF No. 37; Resp. Ex. C, Tabs 10-13, Resp. Ex. D, ECF No. 38.

The Rule 5 status conference was held on January 16, 2018. Scheduling Order, ECF No. 40. Petitioner was ordered to file supplemental expert reports addressing the issues raised by respondent's experts. *Id.* at 2.

Petitioner filed a supplemental report from Dr. Tuohy on March 19, 2018. Pet. Ex. 68, ECF No. 41. An Order was issued on March 20, 2018, noting that the report from Dr. Tuohy did not address the issues outlined by the Court's previous order. Scheduling Order, ECF No. 42. Petitioner was ordered to file a supplemental report from Dr. Tuohy and/or Dr. Hicks that was responsive to the issues raised, or a status report advising that neither of his experts would be answering the questions raised by the Court. *Id.* Petitioner filed a supplemental report from Dr. Hicks on March 26, 2018. Pet. Ex. 69, ECF No. 43. Petitioner filed supporting medical literature from Dr. Tuohy on July 9, 2018. Pet. Ex. 70-74, ECF No. 50.

On August 17, 2018, respondent filed supplemental reports and supporting medical literature from Dr. Collins and Dr. Bigelow. Resp. Ex. E, Tab 1, ECF No. 51; Resp. Ex. F, Tabs 1-8, ECF No. 52. Respondent filed additional literature from Dr. Bigelow on August 20, 2018. Resp. Ex. F, Tab 3, ECF No. 53. An Order was issued for petitioner to file either responsive

expert reports or a status report that the record was complete. Non-PDF Order, issued Aug. 20, 2018.

On November 9, 2018, petitioner filed a status report advising that he did not intend to file any additional expert reports and requesting a status conference to discuss next steps in this matter. ECF No. 54.

A status conference was held on March 21, 2019. Scheduling Order, ECF No. 55. During the conference, petitioner's counsel was asked to clarify an apparent conflict between petitioner's experts. *Id.* at 1. Petitioner's immunologist, Dr. Tuohy opined that the FluMist vaccine caused excessive inflammation in petitioner's sinuses that overwhelmed his ability to clear the flu virus and maintain equilibrium. *Id.* Petitioner's frequent congestion and severe attacks of vertigo could be explained as either a persistence of uncleared virus in the labyrinth and/or post-viral induction of autoimmune sequelae. *Id.* Petitioner's otolaryngologist, Dr. Hicks, opined that petitioner has vestibular neuritis, an autoimmune inner ear disease. *Id.* Petitioner's counsel explained that vestibular neuritis is an autoimmune inner ear disease that does not result in hearing loss and is different from Autoimmune Inner Ear Disease ("AEID"), which is characterized by sensorineural hearing loss. *Id.* It is Dr. Hicks's opinion that petitioner's vestibular neuritis was caused by reactivated HSV-1 and is submitted as an alternate theory, not intended to replace or conflict with Dr. Tuohy's theory that petitioner had an autoimmune reaction to the flu vaccine. *Id.* Petitioner's counsel agreed that his experts could better explain their opinions. *Id.* Petitioner was to file a short supplemental report clarifying his experts' opinions. He was also to address respondent's expert, Dr. Bigelow's opinion that petitioner had vestibular testing that was unremarkable and did not support a diagnosis of vestibular neuritis. *Id.* at 2.

Petitioner filed a status report on May 23, 2019, advising that he intended to file a supplemental report from Dr. Hicks, a supplemental affidavit of petitioner, and a status report confirming that a demand had been sent to respondent within 30 days. ECF No. 56. Petitioner was ordered to file these items by June 24, 2019. Non-PDF Order, issued May 23, 2019. Petitioner filed a supplemental report from Dr. Hicks on June 4, 2019. Pet. Ex. 75, ECF No. 57. Petitioner failed to file his affidavit and status report on time and filed a Motion for Extension of Time on June 27, 2019, which was granted. ECF No. 59, 60; Non-PDF Order, issued June 27, 2019. Petitioner filed a second supplemental affidavit on July 4, 2019. Pet. Ex. 76, ECF No. 61.

Respondent filed a status report on July 29, 2019, advising that he would continue to defend this matter. ECF No. 62. The parties were ordered to file a joint status report indicating whether they would proceed with a decision on the record or an entitlement hearing. Non-PDF Order, issued July 30, 2019.

On September 16, 2019, in a joint status report, petitioner advised that he would like to proceed with a ruling on the record. ECF No. 63. The filing of a Motion for Ruling on the Record was ordered. Non-PDF Order, issued Sept. 16, 2019.

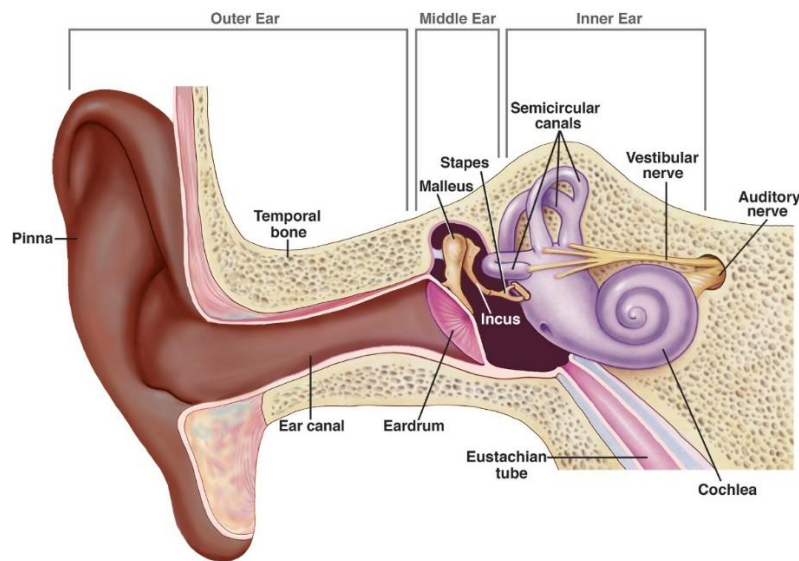
Petitioner filed a Motion for a Ruling on the Record on December 16, 2019. ECF No. 65. After requesting and receiving three extensions of time, respondent filed a response to

petitioner's motion on April 20, 2020. Motion, ECF No. 66; Non-PDF Order, issued Feb. 12, 2020; Motion, ECF No. 67; Non-PDF Order, issued Mar. 27, 2020; Motion, ECF No. 68; Non-PDF Order, issued Apr. 10, 2020; Response, ECF No. 69. After requesting and receiving an extension of time, petitioner filed updated medical records and a reply on May 26, 2020. Motion, ECF No. 70; Non-PDF Order, issued May 20, 2020; Pet. Ex. 77, ECF No. 71; Reply, ECF No. 72.

I have determined that the parties have had a full and fair opportunity to present their cases and that it is appropriate to resolve this issue without a hearing. *See* Vaccine Rule 8(d); Vaccine Rule 3(b)(2); *Kreizenbeck v. Sec'y of Health & Human Servs.*, 945 F.3d 1362, 1366 (Fed. Cir. 2020) (noting that "special masters must determine that the record is comprehensive and fully developed before ruling on the record."). Accordingly, this matter is now ripe for resolution.

II. Medical Definitions and Literature

This diagram⁴ of the anatomy of the ear is provided to aid in visualizing what the respective experts are describing in their opinions. The Eustachian tube⁵ on the bottom right-hand side of the diagram is connected to the nose and the proposed vehicle through which it is suggested that the intranasal vaccine entered the ear.



Vestibular neuritis is a common clinical syndrome characterized by the acute onset of prolonged severe rotatory vertigo, which is associated with spontaneous nystagmus⁶, a reduced

⁴ *Parts of the Ear*, NAT'L INST. ON DEAFNESS AND OTHER COMM. DISORDERS (last updated Mar. 16, 2022), <https://www.nidcd.nih.gov/news/multimedia/medical-illustration-parts-ear>.

⁵ The Eustachian or auditory tube is "a channel about 3.6 cm long, lined with mucous membrane, that establishes communication between the tympanic cavity and the nasopharynx and serves to adjust the pressure of gas in the cavity to the external pressure, as well as for mucociliary clearance of the middle ear. It comprises a bony part (pars ossea), located in the temporal bone, and a cartilaginous part (pars cartilaginea), ending in the nasopharynx." *Dorland's Illustrated Medical Dictionary* 1945. (33rd ed. 2019) [hereinafter "*Dorland's*"].

⁶ Nystagmus is "an involuntary, rapid, rhythmic movement of the eyeball, which may be horizontal, vertical,

or absent caloric response in one ear, postural imbalance, and nausea and vomiting, without cochlear or neurological findings. Pet. Ex. 65 at 2.⁷ If hearing is affected, then the condition is known as **labyrinthitis**. Pet. Ex. 71 at 4.⁸ Vestibular neuritis is thought to result from a selective inflammation of the vestibular nerve that is thought to be of a viral origin. Pet. Ex. 32 at 2; Resp. Ex. C, Tab 1 at 2.⁹ However, the cause of vestibular neuritis is not completely understood, and history of preceding illness is seen in less than one-half of patients. Resp. Ex. C, Tab 2 at 1.¹⁰ Patients with vestibular neuritis generally suffer severe symptoms for one to two days, followed by a gradual diminution of symptoms and a return to equilibrium. *Id.* While acute symptoms rarely last longer than a few days or weeks, residual imbalance and dizziness may persist for months. *Id.* There are no specific diagnostic tests for vestibular neuritis; diagnosis is based on clinical information. *Id.* at 3.

In the acute stage, vestibular neuritis may be treated with corticosteroids and antiviral medications, though both treatment methods are controversial because it is unclear whether corticosteroids support long-term recovery and the link between viral infection and vestibular neuritis/labyrinthitis is still theoretical. Pet. Ex. 71¹¹ at 4-5. However, vestibular rehabilitation and exercises are believed to help hasten recovery and improve patient symptoms. Resp. Ex. C, Tab 2¹² at 5.

“It is a well-established axiom of otolaryngology that when the inner ear is involved in disease, cochlear and vestibular elements are compromised, which leads to hearing loss and vertigo. [In vestibular neuritis] vertigo occurs in the absence of hearing loss, the inner ear is not involved, and the lesion lies in the vestibular neurons central to the labyrinth.” Resp. Ex. C, Tab 4¹³ at 2. Lesions are also limited to the vestibular nerve, with no involvement of the brain stem. It is unclear whether the disease is caused by direct infection, localized thrombosis, or an autoimmune reaction. *Id.* Association with preceding or concurrent infectious illnesses occur in 43-46% of cases. *Id.* at 3. Studies have demonstrated serological evidence of recent upper respiratory tract infections including influenza A and B, adenovirus, herpes simplex virus, cytomegalovirus, Epstein-Barr Virus, rubella virus, and parainfluenza virus. However, no virus has been isolated from the blood, respiratory tract, or cerebral spinal fluid of patients. *Id.*

Vestibular migraine is a term used to describe episodic vertigo in patients with a history of migraines or with other clinical features of migraines. Resp. Ex. C, Tab 5 at 1.¹⁴ Most patients

rotatory, or mixed, i.e., of two varieties.” *Dorland’s* 1289.

⁷ Avi Shupak et al., *Vestibular Neuronitis in Pilots: Follow-up Results and Implications for Flight Safety*, 113 LARYNGOSCOPE 316, 317 (2003), filed as “Pet. Ex. 65.”

⁸ Jason A. Beyea et al., *Recent advances in viral inner ear disorders*, 20 CURRENT OP. HEAD AND NECK SURGERY 404, 407-08 (2012), filed as “Pet. Ex. 71.”

⁹ Robert W. Baloh, *Vestibular Neuritis*, 348 NEW ENG. J. MED. 1027, 1028 (2003), filed as “Pet. Ex. 32” and “Resp. Ex. C, Tab 1.”

¹⁰ Joseph Furman, *Vestibular neuritis and labyrinthitis*, UPTODATE (July 29, 2017, 11:33 AM), <https://www.uptodate.com/contents/vestibular-neuritis-and-labyrinthitis>, filed as “Resp. Ex. C, Tab 2.”

¹¹ Beyea et al., *supra* note 8.

¹² Furman, *supra* note 10.

¹³ Jeffrey P. Staab, *Chronic Subjective Dizziness*, 18 CONTINUUM LIFELONG LEARNING NEUROLOGY 1118 (2012), filed as “Resp. Ex. A, Tab 4.”

¹⁴ Carrie Elizabeth Robertson, *Vestibular migraine*, UPTODATE (July 29, 2017, 11:35 AM), <https://www.uptodate.com/contents/vestibular-migraine>, filed as “Resp. Ex. C, Tab 5.”

with vestibular migraine will have migraine-type headache and vestibular symptoms without other neurologic symptoms. *Id.* at 5. Features of vestibular migraine include episodes of true vertigo (with symptoms of imbalance, visual vertigo, and dizziness or lightheadedness); though vertigo may occur with or without typical migraine headache. *Id.* at 5. The length of an episode of vestibular migraine varies, with most lasting several hours, though some last days, weeks, or only a few minutes, and episodes can occur as often as several times a day or only a few times per year. *Id.* at 5-6.

Cervicogenic vertigo is illusory motion deriving from a disturbance of the neck. Resp. Ex. A, Tab 3¹⁵ at 1. Vestibular testing serves to exclude inner ear disorders as an alternative cause of vertigo. Imaging studies detect structural injury to the neck, which increases the probability of cervicogenic vertigo, but does not establish cause. *Id.* at 4. Cervicogenic vertigo is a significant source of dizziness but currently referred to as “out of fashion”. There is a lack of a sensitive and specific testing to differentiate between the coincidence of neck injury and dizziness, and situations where the neck injury is the actual cause of dizziness. *Id.*

Autoimmune inner ear disease “is an enigmatic disorder characterized by recurring episodes of sudden or progressive sensorineural hearing loss.” Hearing loss may improve with timely use of corticosteroids, but only half of those treated respond and, for many, the response is lost over time. Pet. Ex. 22¹⁶ at 2. The role of the interleukin or IL-1 family as regulators of inflammation and immunity in early immune system reactions to pathogens dictate many of the later adaptive T-cell responses that perpetuate disease. However, the role of IL-1 beta, which causes inflammation and promotes the development of autoimmune disease if not regulated, is largely unknown in hearing disorders. *Id.*

Intranasal influenza vaccine, also referred to as live attenuated influenza vaccine (“LAIV”), is a live, attenuated flu vaccine that provides active immunization for prevention of influenza A and B viruses. It has been shown to be effective in healthy individuals 5-49 years old and serves as an alternative to intramuscular vaccines. Pet. Ex. 19¹⁷ at 7. LAIV is generally well-tolerated, with adverse events being of mild to moderate severity with runny nose and nasal congestion being the most common. LAIV does elicit mucosal IgA antibody responses and strong cell-mediated immunity responses. *Id.* at 2.

Herpes Simplex Virus (“HSV-1”) causes vesicular lesions of the oral mucosa commonly known as “cold sores” and clinical disease in other anatomical locations including the genitalia, liver, lung, eye, and central nervous system. Once HSV-1 infection has occurred, it lives in a latent state in nerve cell bodies in the ganglion and can reactivate. Frequency and reactivation are determined by many factors including immunodeficiency and stress. Precipitating factors for recurrence include exposure to sunlight, fever, menstruation, emotional stress, and trauma to the primary area of infection, such as trigeminal nerve manipulation in oral

¹⁵ Timothy C. Hain, *Cervicogenic causes of vertigo*, 28 CURRENT OP. NEUROLOGY 69 (2015), filed as “Resp. Ex. A, Tab 3.”

¹⁶ Shresh Pathak et al., *IL-1 β Is Overexpressed and Aberrantly Regulated in Corticosteroid Nonresponders with Autoimmune Inner Ear Disease*, 186 J. IMMUNOLOGY 1870 (2011), filed as “Pet. Ex. 22.”

¹⁷ Michelle W. McCarthy & Denise R. Kockler, *Trivalent Intranasal Influenza Vaccine, Live*, 38 ANNALS OF PHARMACOTHERAPY 2086 (2004), filed as “Pet. Ex. 19.”

infection or dental extractions. Vaccination has not been reported to cause recurrences of HSV. Resp. Ex. C at 4; Resp. Ex. C, Tab 9.¹⁸

Ramsey Hunt Syndrome is linked to reactivation of latent varicella zoster virus (VZV)¹⁹, which resides within the geniculate ganglion with subsequent spread of the inflammatory process to involve the eighth cranial nerve, resulting in auditory and vestibular disorders. VZV is thought to become latent after primary varicella infection, and reactivation likely precipitates Ramsey Hunt Syndrome. Antiviral therapy is usually prescribed. Resp. Ex. C at 4; Resp. Ex C, Tab 10.²⁰

III. Petitioner's Medical History and Other Evidence²¹

A. Petitioner's History Prior to the FluMist Vaccination

Petitioner was born on December 21, 1968. Pet. at 1; Pet. Ex. 4 at 2. His past medical history which includes but is not limited to allergic rhinitis, migraines, seborrheic eczema, irritable bowel syndrome, poor circulation, keratosis pillari, reactive "hypoglycaemia", and chronic fatigue syndrome. Pet. Ex. 4 at 53-54. He has a long history of upper respiratory infections with cough, sinusitis and gastrointestinal issues with reflux and burning sensation for which he takes Omeprazole. *Id.* at 1-23. He has had adverse reactions and sensitivity to a host of medications. *Id.* at 2. He has documented reactive arthritis in his feet which developed seven to ten days after a respiratory tract infection in 1998 with Erythromycin-induced dyspepsia and irritable bowel syndrome. *Id.* at 53, 56. He was and continues to be treated for benign moles, skin tags, cysts, and various skin conditions.²² *Id.* at 59, 60, 64, 66, 77, 84, 86. His family history includes migraines and mild arthritis in his mother and insulin dependent diabetes mellitus in his father. *Id.* at 53. He was involved a motor vehicle accident in 2000 and a motorcycle accident in 2004 in which he sustained left clavicle fracture requiring open reduction and bone graft. *Id.* at 5, 68-76. An April 16, 2014 record marks in error several diagnoses made in 1998 which include chronic fatigue syndrome, depressive disorder, and irritable bowel syndrome. How or why these diagnoses were determined to be in error is unclear. *Id.* at 25. The diagnoses of these conditions are contained in various unrelated specialist letters, including but not limited to Dr. Shattles, a rheumatologist who examined him in January 2000 for episodic flares of painful joints following

¹⁸ Robin S. Klein, *Clinical manifestations and diagnosis of herpes simplex virus type 1 infection*; UPTODATE (Aug. 5, 2017, 7:49 PM), <https://www.uptodate.com/>, filed as "Resp. Ex. C, Tab 9."

¹⁹ Varicella zoster virus, or human herpesvirus 3, is the etiologic agent of chickenpox and herpes zoster. *Dorland's* 843. In comparison, HSV-1 is another name for human herpesvirus 1, which is the etiologic agent of herpes simplex. *Id.* 842.

²⁰ Mary A. Albrecht, *Clinical manifestations of varicella-zoster virus infection: Herpes zoster*, UPTODATE (Aug. 5, 2017, 9:23 PM), <https://www.uptodate.com/contents/epidemiology-clinical-manifestations-and-diagnosis-of-herpes-zoster>, filed as "Resp. Ex. C, Tab 10."

²¹ Petitioner received most of his medical care in the United Kingdom and the majority of the records provided consist of reports exchanged between his medical providers rather than actual examination records. Most of petitioner's medical care appears to have been provided by physicians connected to his employment as a pilot. The records filed indicate that when approval could not be secured through his employment for a specialist, private insurance would then be used. The record also includes letters and certificates related to his ability to work/fly.

²² Petitioner consistently presented for dermatological care for skin issues as reflected throughout his medical records. *See generally* Pet. Ex. 4.

upper respiratory infections and again in June 2000 when he consulted Dr. Forsyth for ongoing gastrointestinal issues. *Id.* at 53-55, 56.

Though no medical records were filed for the following visits, petitioner affirmed that he presented to his primary care physician (“PCP”) on December 12, 2005 for head congestion and ear pain from a cold or sinus infection. Pet. Ex. 10 at 1; Pet. Ex. 76 at 1. He further affirmed that he returned to his PCP on July 7, 2006 with similar complaints and “a couple of episodes of mild dizziness.” *Id.* He was referred to an ENT. *Id.* Petitioner affirmed that he did not use the term “vertigo,” because as a pilot, the term “vertigo...implies a significant condition with symptoms of the room spinning, nausea or vomiting, and other symptoms that I did not have.” *Id.* Had he been experiencing “true vertigo,” he would not have been able to fly. *Id.*

On July 25, 2006, Dr. Warrington, the ENT documented petitioner’s visit in a letter to his PCP. Pet. Ex. 4 at 78. Dr. Warrington wrote that petitioner had three episodes of vertigo this year. The first occurred in January and lasted for about ten hours, the second occurred “a few months later” and lasted for about ten hours, and the third occurred in July 2006 and lasted for thirty-six hours. *Id.* Petitioner described the vertigo as “a sensation of spinning associated with nausea and it happens on moving.” *Id.* Dr. Warrington wrote, “It does not appear as if the vertigo is strictly positional although at the onset of the latest episode the vertigo first occurred when the patient got up from having been sitting in a chair.” *Id.* There was no hearing loss, tinnitus, or sensation of fullness in the ears and no other relevant symptoms of note; Dr. Warrington’s assessment was “central vertigo which is partially compensated.” *Id.* Dr. Warrington wrote that further investigation was needed and recommended an ENG (electronystagmography), the location of which would depend on petitioner’s insurance coverage. *Id.* at 79. Dr. Warrington assured petitioner that there did not “appear to be anything sinister behind his episodes of vertigo and that it is unlikely that the vertigo shall ever seriously interfere with his ability to fly.” *Id.* Dr. Warrington closed his letter to the PCP advising that he would be in touch after the ENG. *Id.* No record of an ENG being performed was filed and it is unknown if this testing was performed.

Petitioner developed severe back pain with left side sciatica in 2009 which affected his ability to work. Physical therapy provided little relief and he reported having to give up playing sports due to his symptoms. Pet. Ex. 4 at 15-21, 87. An MRI showed a minor disc bulge at L5/S1, and conservative treatment was expected to resolve the issue. *Id.* at 90. An epidural was done February 5, 2010. *Id.* at 95. However, petitioner returned to orthopedics in May 2010 with recurrence of significant pain and sciatic symptoms. Another epidural was scheduled and done on May 21, 2010. *Id.* at 92, 96. Petitioner returned in June 2010 with ongoing pain. Another MRI was ordered. *Id.* at 97. At a July 2010 visit his MRI results were discussed which included his disc protrusion to be slightly bigger with some compression on the nerve root. An L5/S1 discectomy was discussed. *Id.* at 98-99, 102-03. Petitioner underwent left L5/S1 lumbar decompression on September 10, 2010. *Id.* at 104-05.

On August 2, 2010, petitioner was prescribed 10 mg Amitriptyline tablets to be taken each night. Pet. Ex. 4 at 32.²³

²³ Amitriptyline is used to treat nerve pain, migraine attacks, and depression. Petitioner was prescribed Amitriptyline in 2015 to treat his vertigo. Pet. Ex. 4 at 33.

Petitioner presented on December 20, 2011 for “several issues,” reporting that he “had flu jab, then had uris sxs, back and forth from sinuses to chest and back, pounding HAs on descent, pain behind eyes, cough x 6/52, feeling wheezy and sl SOB; smoked many years ago-very lightly and not for years, hx of lingering coughs, used INH (inhaler) recently w/ some improvement, thinks he has inflammation rather than infxn, no fever”. Pet. Ex. 4 at 21. The diagnosis was sinusitis. *Id.* The “Plan” included “rx and incr fluid...; (employer letter given) and if 8 days w/o work, to ring fore Med3 – leave msg for me...Letter to Patients to Unknown...Letter Marked in Error: Wrong data entered (This item was never saved to the patient record)”. *Id.* The error in the record appears to have been referring to the content of the “Letter to Patients to Unknown” not the record of his symptoms and diagnosis as evidenced by petitioner return to the doctor on December 28, 2011. “...still having sinus sxs – HA worse over the past few days, cough has improved; taking Sudafed...has not returned to work, has leave from 1.1.12; first missed day 19.12.11...advised sxs may linger for weeks, but if ongoing beyond, pt may wish referral on his private insurance to ENT.” Pet. Ex. 4 at 21.

The next medical record was for a visit to his PCP on August 12, 2013, reporting swelling in the submental²⁴ area and pain over the right eye. He was diagnosed with lymphadenopathy. Pet. Ex. 4 at 23, 104-05.

At the time petitioner received the allegedly causal vaccination, he was employed as a pilot for EasyJet. Pet. Ex. 4 at 109; Pet. Ex. 1 at 1.

B. Petitioner’s History Following the FluMist Vaccination

Petitioner received a FluMist vaccination on October 17, 2013 at a Walgreens pharmacy in the United States. Pet. Ex. 2 at 3. Shortly thereafter, he “flew back to England in connection with [his] job as a pilot for EasyJet.” Pet. Ex. 1 at 1. According to petitioner, he began to experience dizziness and nausea “[w]ithin days of returning home.” *Id.* He recalled that the first episode of vertigo lasted “a little over a[n] hour” and he continued to have periods of dizziness “[o]ver the next two days.” *Id.*

On October 22, 2013, petitioner presented to his PCP reporting a recent flu vaccine in the USA and feeling unwell, with some flu like symptoms and feeling dizziness, but now improved from how he felt a few days ago. Pet. Ex. 4 at 23. He returned to the PCP on October 30, 2013 with “History: issues with vertigo and nausea-worse with brisk movemetns (sic)- Plan: ?? viral labyrnithis (sic)-...if bet5ter(sic) will need rtw cert before work on 3/11...” *Id.*

At a November 1, 2013 PCP visit, petitioner reported ongoing symptoms that were “becoming a little worse” with more nausea. Pet. Ex. 4 at 23. He was diagnosed with labyrinthitis, and benign paroxysmal positional vertigo. He was prescribed betahistine²⁵ and prochlorperazine.²⁶ *Id.*

²⁴ The submental area is the area inferior to the chin. *Dorland’s* 1762.

²⁵ Betahistine is “a histamine analogue used as a vasodilator to reduce the frequency of attacks of vertigo”. *Dorland’s* 208.

²⁶ Prochlorperazine is “a phenothiazine derivative used chiefly as an antiemetic.” *Dorland’s* 1497.

Petitioner's next documented medical visit was three months later, on February 11, 2014. Petitioner reported to the PCP that he was off work since October and needed a sick note from November 4, 2013 to February 10, 2014. He was also requesting a back to work certificate from today February 11, 2014. He reported that he "feels well, no dizziness, took medication for dizziness only for few days, no headache or dizziness last time he had symptoms was 23/12, only minor symptoms, feels well." Pet. Ex. 4 at 23. He reported a cough for a month and requested an x-ray which was normal and to be tested for STI. *Id.*

Petitioner presented to his PCP on April 11, 2014 and asked for a referral to an ENT. The record reads "2 episodes of labyrinthitis, civil aviation authorities have suspended his license, needs referral to ENT consultant asking for a letter." Pet. Ex. 4 at 24.

Petitioner was referred to Dr. Brookes, an otolaryngologist and surgeon who he presented to on April 15, 2014. Petitioner was noted to be a 45-year-old pilot who "started with a sudden onset of rotational vertigo some 3 days after flu vaccination in the States" in October 2013. He was ill for about 4 weeks with persistent symptoms of rotational vertigo and vomiting. Symptoms then eased and 2 months later were gone. Pet. Ex. 4 at 109. He was clear for a month and returned to work at EasyJet. He then caught an upper respiratory tract infection ("URI"), "following which he has had symptoms again, although intermittent and not as severe as when they first appeared. He gets nausea and a sensation of movement without any rotational vertigo." *Id.* On examination, his eyes, ears, and throat appeared normal. He "had no obvious localising signs in his central or peripheral nervous system." A hearing test was normal. *Id.* Vestibular testing was arranged with Dr. Low, an audiologist, and an MRI was ordered. *Id.* at 109; Pet. Ex. 5 at 22. Dr. Brookes wrote a letter to Dr. Low referring petitioner for rotational vertigo three days after flu vaccination with symptoms for a month that eased off over a two-month period without hearing change or tinnitus. He was symptom-free for two months, until he had an upper respiratory tract infection. Dr. Brookes wondered if petitioner had an episode of viral labyrinthitis with compensation followed by an episode of decompensation. Pet. Ex. 7 at 6.

Dr. Brookes also wrote a letter to petitioner's PCP documenting petitioner's history of sudden onset of rotational vertigo three days after a flu vaccination, illness for four weeks, symptoms easing over the next two months until they were gone and being clear of symptoms for a month with return to work. He then suffered an upper respiratory infection and developed symptoms again that were intermittent and not as severe. On examination, his ears, nose, and throat were normal with no obvious signs of central or peripheral nervous system issues. A hearing test was normal. Vestibular tests and an MRI were arranged. Pet. Ex. 7 at 8.

In a letter dated April 30, 2014, Dr. Brookes wrote that petitioner's MRI was "completely normal" and vestibular function testing implied hyperfunction, though he had not seen the report yet. Pet. Ex. 7 at 1. Once he read the report, he would "get Sam Khemani's opinion as this is most unusual" and thought "it fit best with a post viral damage and decompensation." *Id.*

Dr. Low authored a letter to Dr. Brookes dated May 1, 2014 with the results of petitioner's vestibular testing. Dr. Low detailed a history which included a flu vaccine after which petitioner awoke at around 5 pm that afternoon with rotatory vertigo when he lifted his head from the pillow. The vertigo was not in a single dimension but multi-planar and, across

time, simplified to just a horizontal plane with clear positional component. The initial event continued for an hour before reducing and was then continuous for two days before periods of relief. Dr. Low noted that saccadic eye movements²⁷ were accurate but did show undershoot dysmetria²⁸ in both directions. Examination was normal or failed to reach clinical significance but was observable and subjectively apparent. Pet. Ex. 7 at 12. The test results showed “no evidence of viral damage” and Dr. Low was “hesitant to speculate at any diagnosis”. Pet. Ex. 5 at 14.

Dr. Brookes referred petitioner to Dr. Khemani, an otolaryngologist. Pet. Ex. 8 at 50. Petitioner presented to Dr. Khemani on May 9, 2014. On examination, Dr. Khemani noted evidence of a trigger points on the right side of petitioner’s neck which caused some discomfort, normal tympanic membranes²⁹, and “reasonably unremarkable” balance testing. *Id.* at 51. His assessment was “an episode of viral neuronitis³⁰ which recovered fully,” and “episodes of decompensation which are likely to be triggered by a proprioceptive³¹ cause, particularly a cervicogenic³² cause.” MRI of the cervical spine was ordered. *Id.* Cervical MRI conducted on May 14, 2014 showed “minimal” disc bulge at the C3/4 level without impingement on the cord. *Id.* at 34. There was no other abnormality in the cervical region or the upper thoracic spine. *Id.* Petitioner was referred to a physical therapist with expertise in vestibular therapy. *Id.*

Petitioner returned to Dr. Khemani on June 9, 2014. Pet. Ex. 4 at 112. Dr. Khemani’s diagnosis at that time was cervicogenic vertigo, noting that a thorough investigation had been conducted with no abnormality found on vestibular testing. Cervical MRI showed evidence of a C3/C4 disc bulge which was likely affecting his vestibulospinal reflex.³³ *Id.* Petitioner admitted to having symptoms of paresthesia³⁴ in his fingertips from time to time, which would fit the diagnosis. He was dependent on his eyesight to correct any balance disturbance which implies either abnormality of the vestibular apparatus or proprioception. Testing of the vestibular apparatus was normal, therefore proprioceptive abnormalities were likely the cause of his symptoms. *Id.* He was attending physical therapy for his neck with some balance stabilizing exercises that have helped. *Id.* The importance of physical therapy, postural exercises, and massage were discussed and should continue. *Id.*

Mr. Cowles was evaluated by Dr. Rowlands, a psychiatrist, at the request of Dr. Khemani on September 1, 2014. He reported a motorcycle accident in 2005 with a head injury and metal plate insertion to his shoulder, neither affecting his ability to fly. He had back surgery in 2010. Pet. Ex. 4 at 115. He lives in the US and works in the UK part time. He had vestibular difficulty

²⁷ Saccadic movement refers to quick movement of the eye from one fixation point to another. *Dorland’s* 1167.

²⁸ Ocular dysmetria is “an error in ocular fixation consisting of overshooting the desired focus followed by oscillations of focus until fixation is achieved.” *Dorland’s* 572.

²⁹ The tympanic membrane is “the obliquely placed, thin membranous partition between the external acoustic meatus and the tympanic cavity.” *Dorland’s* 1112. The external acoustic meatus is the passage of the external ear leading to the tympanic membrane and the tympanic cavity is the major portion of the middle ear. *Id.* at 1101, 304.

³⁰ Neuritis and neuronitis are used interchangeably.

³¹ Proprioceptive means “capable of receiving stimuli originating in muscles, tendons, and other external tissues.” *Stedman’s Medical Dictionary* 728100, accessed via westlaw.com (last visited 2022) [hereinafter “*Stedman’s*”].

³² The term “cervicogenic” refers to something derived from a disturbance of the neck. *See* Resp. Ex. A, Tab 3 at 1.

³³ The vestibulospinal reflex refers to the influence of vestibular stimulation on body posture. *Stedman’s* 769750.

³⁴ Paresthesia is an abnormal touch sensation, such as burning, prickling, or formication, often in the absence of an external stimulus. *Dorland’s* 1362.

in October 2013 following a bout of flu. He awoke with the room “swimming” and “severe vertigo and nausea”. He did not fly the following day and went to the doctor, who diagnosed labyrinthitis. *Id.* He improved and his symptoms “reduced in intensity and duration.” *Id.* He needed to be symptom free for a month to have flying privileges. “In April of 2014 he had thirty days without symptoms.” *Id.* His license was reissued, and he returned home to the US, but had a further episode of dizziness and his license was withdrawn. *Id.* Petitioner reported “I feel woozy, not quite with it.” *Id.* He described his symptoms as intermittent in duration and variable in intensity, lasting from seconds to minutes. He was able to drive without difficulty and function on a day-to-day basis. He reported being on six months of full pay but will have a small loss if unable to fly beyond that time. *Id.* He was married but separated in 2012. Both he and his wife have new partners; his is in Chicago. He looks after a number of properties in the US. *Id.* at 115-16. He has had psychological stress with some of the unresolved separation issues and the vestibular disorder, which has interfered with his ability to fly. Petitioner intends to emigrate to the United States so psychological treatment would not be of benefit here. Mindful therapy could be helpful to deal with his anxiety, but from a psychiatric perspective he “is fit to fly”. *Id.* at 116.

Dr. Khemani referred petitioner back to Dr. Low for repeat vestibular testing on November 10, 2014. Pet. Ex. 5 at 10.

Petitioner presented with complaints of 3-4 months of gastrointestinal issues, worsening reflux, heartburn, stomach pain, and loose bowels in November of 2014. He had taken Omeprazole for a long time, which worked until now. He increased it and put himself on a lactose-free diet that helped. He worked for an airline but was grounded due to dizzy spells. Testing was ordered. Pet. Ex. 4 at 117. A colonoscopy was performed and was reassuring. *Id.* at 118, 120. He was referred to a dietician. *Id.* at 120.

In a letter to Dr. Khemani dated November 24, 2014, Dr. Low reported that petitioner had returned reporting initial improvement with physical therapy but now feels his disorientation and imbalance have worsened. “Apart from the initial event there has been no occasion of true rotatory vertigo and no new symptoms have emerged.” Pet. Ex. 5 at 6. Bithermal caloric irrigations³⁵ had an identical value of asymmetry, “being insignificant at 11%”. *Id.* Dr. Low noted an interesting change in vestibular sensitivity of 119.9° per second on the left, compared to 79.3° six months ago which was highly significant with hyperactivity of both vestibular organs. “Clearly the clinical decision is yours, but I would suspect that this represents a vestibular migraine. This would explain why the rehab has not proved successful and why there is no experience of true rotary vertigo, but simply disequilibrium.” Pet. Ex. 5 at 6.

At petitioner’s return visit with Dr. Khemani on November 27, 2014, he was advised that his recent testing “may be indicative of vestibular migraine.” Pet. Ex. 4 at 119. Repeat MRIs showed no changes to the C3/C4 disc bulge and “no abnormality within the brain or inner ears.” *Id.* Dr. Khemani recommended that petitioner continue with postural and positional exercises. He referred petitioner to Dr. Bronstein, a leading expert in balance disorders. Dr. Khemani’s diagnoses were probable vestibular migraine, cervicogenic cause of imbalance based on the

³⁵ A bithermal caloric test is “a test of vestibular function in which each ear canal is alternately or simultaneously irrigated with water at 7°C higher or lower than body temperature; the nystagmus produced may be monitored for direction, amplitude, speed of the slow component, and duration.” *Stedman’s* 904140.

C3/C4 disc bulge, very minor anxiety overlay, no evidence of vestibular asymmetry on previous testing, and normal MRI scan of internal acoustic inner ear and brain. *Id.* at 119.

In a letter dated December 8, 2014, Dr. Khemani wrote to Dr. Bronstein including his diagnoses of probable migrainous vertigo, C3/C4 disc bulge on MRI of cervical spine, minor anxiety overlay, and vestibular hypersensitivity in the left ear on caloric investigations. Pet. Ex. 4 at 121. He included a history of true rotatory vertigo two days after a flu vaccine that was multi-planar in nature, not just in a horizontal plane, two days of symptoms that subsided somewhat, formal vestibular testing with no significant vestibular asymmetry found, some hypersensitivity in the left ear on warm caloric, and the remainder of both balance and vestibular investigation as unremarkable. *Id.* His symptoms were more in keeping with disequilibrium. MRI of the internal acoustic meati³⁶ and brain were “entirely normal.” He had physical therapy and some vestibular rehabilitation. Most symptoms resolved, but he had ongoing symptoms of disorientation. He is a pilot and grounded because of his symptoms. *Id.* at 121. Repeat vestibular testing suggested underlying vestibular migraine, though there is “very little in the way of migraine history other than a family history on his maternal side.” *Id.* at 122.

Petitioner presented to Dr. Bronstein on February 5, 2015. Pet. Ex. 3 at 1; Pet Ex. 4 at 123.³⁷ He reported receipt of a nasal flu vaccine in the US and two to three days later, after a long flight, he developed intense vertigo and vomiting described as a tumbling sensation with things moving in a vertical plane. He went back to bed and focused on the ceiling to suppress the vertigo. The following day, he still felt dizzy, but the strong rotational component had largely subsided. Since then, he has had some component of disorientation and occasional nausea. He can feel strange and slightly clumsy with certain head movements, particularly in the vertical plane. He had recovered 80 to 90% when compared to his acute vertigo. His current symptoms were between 15 and 25% of the original sensation. Petitioner reported an increase in feelings of disorientation or dizziness in elevators, in planes if they tilt, and in cars and trains somewhat. On specific questioning, he denied formal migraines but described sinus-related headaches, sometimes of only one orbit, and a family history of migraine in his mother. *Id.* Dr. Bronstein ordered a video head impulse test (“vHIT”) which showed “abnormal responses from the left posterior canal with a gain of 0.33.” Dr. Bronstein was “still a little suspicious about unexpected findings in this test.” He also ordered cervical vestibular evoked myogenic potential (“cVEMP”) tests, which were normal. *Id.* at 124.

Dr. Bronstein agreed with the possibility that migraines were a contributory factor but saw “two parallel possible interpretation[s].” Pet. Ex. 3 at 2; Pet. Ex. 4 at 124. The first interpretation was that petitioner “did have a vestibular neuritis at the very beginning of this which has left residual symptoms perhaps not fully compensated because of the presence of migraine.” *Id.* The sensitivity to movements of the head in the vertical plane and his description of his initial vertigo as a vertical tumbling of images, in addition to the finding of an abnormal left posterior canal by vHIT, made Dr. Bronstein wonder if petitioner had an inferior vestibular nerve neuritis, though the cVEMP did not confirm this, it “remains a possibility.” *Id.* The second interpretation was that “it is all due to a form of migraine with a vestibular flavor.” *Id.* Dr.

³⁶ The internal acoustic meatus is the passage in the petrous portion of the temporal bone through which the facial and vestibulocochlear nerves and the labyrinthine artery pass. *Dorland’s* 1101.

³⁷ Dr. Bronstein’s records are also filed as Pet. Ex. 5.

Bronstein prescribed 10 mg of Amitriptyline for two weeks and instructed petitioner to increase to 20-25 mg if there was no improvement after that period. *Id.*

Petitioner returned to Dr. Khemani on February 9, 2015 who noted Dr. Bronstein's findings and agreed with his assessment. Pet. Ex. 8 at 14. Petitioner was to continue with vestibular rehabilitation exercises and return in three months. *Id.*

A March 6, 2015 entry notes that petitioner is taking Amitriptyline for migrainous vertigo and Omeprazole for gastrointestinal issues. Pet. Ex. 4 at 28.

At a return visit to Dr. Bronstein on June 11, 2015, he reported 60 to 70% improvement in his symptoms with Amitriptyline and advised that his symptoms "are a bit more prolonged" if he stops or forgets to take Amitriptyline for a day. His current symptoms include "a form of slight spatial disorientation or motion sickness type sensation." Pet. Ex. 3 at 3; Pet Ex. 4 at 128. Petitioner's examination and six canal vHIT test were normal, though Dr. Bronstein noted that the test was new and his "confidence in [his] interpretation was limited." *Id.* Dr. Bronstein noted a recent migraine episode with left retro-orbital pain. His assessment was that petitioner was doing well but needed "further specific rehabilitation" and referred him to a balance and hearing therapist. *Id.* He also suggested that petitioner take 25 mg of Amitriptyline due to his recent migraine, but instructed petitioner to eventually taper over four to six weeks when his symptoms eventually improve. *Id.* Dr. Bronstein wrote to the hearing and balance therapist requesting assistance with balance therapy. Pet. Ex. 4 at 130.

Petitioner returned to Dr. Khemani on June 15, 2015, reporting that he felt 75% better overall taking 25 mg of Amitriptyline each night, but stopping the medication causes a "very severe recurrence of his symptoms." Pet. Ex. 4 at 131; Pet. Ex. 8 at 9. Dr. Khemani documented petitioner's complaint of neck discomfort and that he regularly performed neck exercises because "[E]xcessive rotation of his neck can trigger some of his vestibular symptoms". *Id.* Dr. Khemani agreed with Dr. Bronstein that individuals with vestibular migraines sometimes do not fully recover, and he may need to seek out an alternative career if his symptoms are still present after six months. Pet. Ex. 8 at 9. Dr. Khemani's diagnosis was migrainous vertigo and C3/C4 disc bulge possibly contributing to vestibular symptoms. *Id.* at 6.

On June 23, 2015, petitioner was noted to have vestibular issues that were ongoing and has impacted his flying. He was taking Amitriptyline and Omeprazole. Pet. Ex. 4 at 28.

Petitioner attended one appointment every day for a week with balance and hearing specialist Jane McCall in September 2015. Pet. Ex. 6. Ms. McCall reported some good improvement with sitting in darkness to looking at complex moving patterns and with standing to jogging with some reduction of symptoms. *Id.* She emphasized the importance of general wellness, fitness, and relaxation as well as the need for additional sessions. *Id.*

Petitioner returned to Dr. Khemani for a follow-up on September 17, 2015. Pet. Ex. 4 at 133; Pet. Ex. 8 at 4. He continued to report 60-70% improvement with Amitriptyline and was undergoing intensive therapy at Imperial College. *Id.* Dr. Khemani suggested that petitioner take an additional three months off work, stating that the vestibular therapy he was receiving is

“really the last ditch attempt” to improve his symptoms, and it is unlikely he could return to his current career as a pilot if the therapy did not further improve his symptoms. *Id.*

Petitioner sought chiropractic care on November 17, 2015, reporting dizzy spells after a nasal flu vaccination two years prior, digestive issues for several years, and lethargy. He reported receiving physical therapy but had not tried chiropractic or acupuncture yet. He stayed active but had general muscle tightness in his shoulders and upper back, occasional headaches when his neck is bad, and left pinky finger tingling. Pet. Ex. 77 at 28. Petitioner completed a form on that date listing “vestibular migraines/dizzy spells” as his major complaint. *Id.* at 31. Petitioner continued with chiropractic treatment, mostly for digestive issues, and nutritional guidance through April 2016. *See* Pet. Ex. 77.

The last record filed was a follow-up with Dr. Khemani on January 13, 2016. Pet. Ex. 8 at 2. Dr. Khemani documented that since September he had undergone a course of vestibular therapy with no substantial improvement in symptoms and was still experiencing three to four episodes of dizziness per week, even while taking Amitriptyline. *Id.* Dr. Khemani wrote because petitioner had failed to improve at this point, he “very much doubt[s] whether there will be any ongoing improvement in the future” and that there is “no further role for any other treatments other than ongoing use of Amitriptyline.” *Id.* He explained, “we have exhausted all medical options that I am of aware of” and recommended that petitioner continue taking Amitriptyline at the current dose until his symptoms stabilize, at which point it may be possible to wean off. *Id.*

C. Petitioner’s Affidavits

1. Petitioner’s First Affidavit

In his first affidavit dated September 16, 2016, petitioner affirmed receipt of a nasal influenza vaccine in the United States on October 17, 2013 and returning to England and his job as a pilot for EasyJet shortly thereafter. Pet. Ex. 1 at 1. Several days later he experienced dizziness and nausea, with “the first episode of vertigo lasting a little over an hour.” He had periods of dizziness and relief over the next two days. Pet. Ex. 1 at 1.

According to petitioner, he visited his primary care physician on October 22, 2013. His dizziness had lessened, but he was still experiencing flu-like symptoms and wanted to “insure that [his] condition had resolved” and he was fit to work as a pilot. Pet. Ex. 1 at 1. He returned to his doctor on October 30, 2013 due to continued episodes of dizziness and nausea, was diagnosed with viral labyrinthitis and pronounced unfit for work. *Id.*

Petitioner affirmed that he began to “feel a little better” by early February 2014 and returned to his primary care physician on February 11, 2014 to request clearance to return to work. Pet. Ex. 1 at 2. He received a letter from the Civil Aviation Authority on February 20, 2014 for his return to work but was required to complete several weeks of training due to the passage of time. *Id.* However, before he was fully reinstated, the dizziness and nausea returned, “although the symptoms were not quite as severe as before,” and his flying license was suspended again. *Id.*

Petitioner then saw Dr. Brookes on April 15, 2014, who arranged vestibular testing and an MRI and referred him to Dr. Khemani. Pet. Ex. 1 at 2. Dr. Khemani informed him he had “an episode of viral neuritis but then [] suffered episodes of relapse.” *Id.*

Petitioner recalled that an MRI of the spine on May 19, 2014 showed a bulge at the C3/C4 level that could be the possible cause of his condition and was diagnosed with cervicogenic vertigo. Pet. Ex. 1 at 2.

Petitioner affirmed that by the end of 2014, his treating physicians described his condition as vestibular migraines. Pet. Ex. 1 at 2. Dr. Bronstein told him he had vestibular neuritis shortly after his receipt of the flu vaccine with residual symptoms that were being masked by migraines. Dr. Bronstein further advised that he had inferior vestibular nerve neuritis referred to as a “migraine with a vestibular flavor” which was the cause of his symptoms. *Id.* Petitioner began taking Amitriptyline and attending physical therapy. *Id.*

According to petitioner the Amitriptyline did not help, and he was experiencing three to four episodes of dizziness per week in January 2016. Pet. Ex. 1 at 2. Dr. Khemani advised him that all medical options for treatment were exhausted and instructed him to wean off Amitriptyline over the next two months. *Id.* When he relocated to the United States, he began seeing a chiropractor/homeopathic doctor, but has yet to see improvements with his dizziness. *Id.* at 3. He also made changes to his lifestyle via diet and exercise but continues to experience symptoms. *Id.*

2. Petitioner’s Second Affidavit

Petitioner filed a second affidavit dated February 3, 2017, to address the 2006 medical records. Pet. Ex. 10 at 1. Petitioner affirmed seeing his primary care physician on July 7, 2006 for head congestion and ear pain and having similar complaints on December 12, 2005.³⁸ *Id.* He was referred to an ENT, who he saw on July 20, 2006. *Id.* However, he “never would have told [the ENT] that I was experiencing ‘vertigo’” because, as a pilot, the term implies “a significant condition with symptoms of room spinning, nausea or vomiting” with other symptoms which he did not have, and had he experienced “true ‘vertigo’” he would not have been able to fly. *Id.* The ENT told him there was nothing wrong medically. After his head cold or sinus infection cleared up, he did not experience any further dizziness or sinus congestion and did not return to his primary care physician for additional care. *Id.*

Petitioner denied any symptoms of vertigo or mild dizziness between 2006 and 2013. The first symptoms of vertigo he experienced were in the days following his receipt of the nasal flu vaccine on October 17, 2013. Pet. Ex. 10 at 2.

3. Petitioner’s Third Affidavit

In a third affidavit dated July 2, 2019, petitioner affirmed that he “had never experienced vertigo prior to my flu vaccination in 2013.” Pet. Ex. 76 at 1. He restated the events regarding his ENT visit in July 2006 as described in his second affidavit. *Id.*

³⁸ There were no records filed for these visits.

According to petitioner after he received the vaccination on October 17, 2013, he began experiencing “extreme dizziness, nausea, and [his] first bout of vertigo, which lasted over an hour.” Pet. Ex. 76 at 2. By October 20, 2013, he was diagnosed with possible viral labyrinthitis and unable to fly. *Id.*

Petitioner affirmed that he had some improvement in his symptoms but denied his condition resolved by December 2013. Pet. Ex. 76 at 2. He affirmed that his vertigo was less intense and frequent by February 2014, but he was at risk of his pilot’s license being revoked after two months of being unable to fly and returned to his PCP on February 11, 2014 to obtain clearance to fly, although he was not symptom-free. *Id.* He affirmed that it would take an estimated 4-6 weeks to retrain and recertify and believed that would be “ample time to make a full recovery.” *Id.* He admitted in hindsight, this was “a little presumptuous and even desperate” but he wanted to alleviate his employer’s concerns about his flight medical status. *Id.*

However, while attending ground school and before being fully reinstated to fly, his symptoms then worsened. Pet. Ex. 76 at 2. He affirmed that he had “the same symptoms of nausea and dizziness, with a feeling of spinning that I had experienced a few days after my flu shot,” which had “never fully gone away.” *Id.* He informed his physician and the Civil Aviation Authority of his condition, and his license was suspended again for medical reasons.³⁹ *Id.*

IV. The Experts

A. Petitioner’s Experts

1. Dr. Vincent Tuohy

i. Qualifications

Dr. Tuohy obtained a Ph.D. in pathology from SUNY Downstate Medical Center and completed a postdoctoral fellowship in autoimmunity at Eunice Kennedy Shriver Center. He is not a medical doctor. Pet. Ex. 12 at 1. Since 1989, Dr. Tuohy has served in various roles at the Cleveland Clinic, first as staff in the immunology department and, since 2004, as a professor in the department of molecular medicine. *Id.* at 2. Petitioner filed two expert reports from his expert immunologist, Dr. Vincent Tuohy. *See* Pet. Ex. 11, 68.

ii. Dr. Tuohy’s First Report

In Dr. Tuohy’s opinion, petitioner’s condition “occurred as an unfortunate autoimmune sequelae” of receipt of the FluMist vaccine. Pet. Ex. 11 at 4.

Dr. Tuohy explained that FluMist vaccine contains live attenuated viruses while intramuscular flu vaccine contains inactivated viruses, and it is well known that the “...broadest immunity to influenza occurs following infection with live virus.” Pet. Ex. 11 at 2.

³⁹ Petitioner failed to mention that he suffered from an upper respiratory infection prior to his symptoms returning. *See* Pet. Ex. 4 at 109.

According to Dr. Tuohy, the FluMist vaccine provides cross-protective immunity mediated by B cells and CD8+ T cells, with the T cells primed to epitopes of proteins common to many flu strains. Pet. Ex. 11 at 2. FluMist vaccine “is known to induce substantial mucosal IgA antibody responses and strong T cell-mediated immunity.” *Id.* Dr. Tuohy’s theory includes a vaccine induced reactivation of latent memory T cells and B cells specific for cross-protective antigens that were initially primed either from a prior wild type flu virus or prior influenza vaccinations. *Id.* at 2-3. The 2–3-day onset of vertigo and nausea in this case is consistent with re-exposure rather than introduction of a new antigen priming response which typically takes 5 days to manifest and longer to reach complete maturity. Memory response causes rapid clonal expansion of previously primed lymphocytes and “produce[s] a rapid and vigorous production of inflammatory cytokines in the nasal mucosa.” *Id.* at 3. Dr. Tuohy proposes that following receipt of the intranasal flu vaccine, inflammatory cytokines produced by the adaptive memory and innate immune responses (which typically involves the production of IL-1 beta, tumor necrosis factor alpha (TNF α), and a variety of chemokines for priming naive T cells and B cells against newly engaged influenza antigens found in the multivalent FluMist inoculum) rapidly entered blood circulation through the mucosal blood vessels of the nasal sinuses. Due to the close anatomic proximity of the nasal sinuses and inner ear tissues, the “potent cytokine gradient that developed would preferentially affect nearby tissues” and likely induce inner ear damage due to the “extremely high sensitivity” of the inner ear tissues to the effects of inflammatory cytokines. *Id.* at 3.

Dr. Tuohy relied on the *Rose* study to demonstrate the relationship between acute viral infection and subsequent development of immune responsiveness to self-proteins and autoimmune disease by showing that local production of TNF α and IL-1beta promote the induction of post-infectious autoimmune disease. Pet. Ex. 11 at 4; Pet. Ex. 25.⁴⁰ Viral infection provides the new priming of an infiltrating immune system to locally expressed self-proteins resulting in a new round of disease symptoms, and the new repertoire of primed T cells and B cells induces another wave of inflammation that facilitates recognition of additional self-proteins and clonal expansion. Pet. Ex. 11 at 4. This relapsing, remitting pattern keeps repeating leading to chronicity as a result of cascading wave F neautoactivity and incomplete recoveries and is referred to as “epitope spreading.” *Id.*

Dr. Tuohy presented two possible explanations for the persistence of petitioner’s symptoms: “inadequate viral clearance and repeated reactivation of influenza or other latent viruses capable of maintaining periodic surges in immune-induced cytokine production,” or “induction of postinfectious autoimmune inner ear disease leading to exacerbating-remitting symptoms and eventual progression to chronicity.” Pet. Ex. 11 at 3. In Dr. Tuohy’s opinion, the “autoimmune-based explanation seems more reasonable” because the periodic viral reactivation explanation involves individuals who are immunosuppressed or immunocompromised, which petitioner is not. *Id.*

iii. Dr. Tuohy’s Second Report

⁴⁰ Noel R. Rose et al., *Autoimmune myocarditis: a paradigm of post-infection autoimmune disease*, 9 IMMUNOLOGY TODAY 117 (1988), filed as “Pet. Ex. 25.”

In a second report, Dr. Tuohy took issue with petitioner's 2006 medical record. Dr. Tuohy disagreed that petitioner had three separate occasions of vertigo because if he had it would have affected his ability to fly. He added that Dr. Warrington assured petitioner there was nothing "sinister" involved in his complaints, and it was unlikely that his symptoms would "ever seriously interfere with his ability to fly." Pet. Ex. 68 at 1. Dr. Tuohy argued that several errors existed in petitioner's medical records including diagnoses of chronic fatigue syndrome, depressive disorder, and irritable bowel syndrome that were either redacted or "marked in error." The 2006 vertigo diagnosis was another misdiagnosis. *Id.* Dr. Tuohy proposed that mild dizziness due to sinus congestion is qualitatively distinguishable from the more serious vertigo symptoms of room-spinning and nausea that petitioner experienced a few days after receiving the FluMist vaccine. *Id.* Dr. Tuohy maintained that petitioner suffered true vertigo symptoms after the FluMist vaccine with recurring symptoms thereafter that cannot be mistaken for "benign dizziness associated with [petitioner's] complaints of repeated colds, ear pain, and sinus congestion in 2006." *Id.*

Further, Dr. Tuohy claimed that Dr. Khemani misdiagnosed petitioner with migrainous vertigo 14 months after the FluMist vaccination, based on "very little in the way of migraine history" to support this diagnosis. Pet. Ex. 68 at 2. It is "untenable that respondents have embraced the validity of a migrainous vertigo diagnosis to explain [petitioner's] current condition." *Id.*

Dr. Tuohy again opined that the debilitating series of repeated vertigo symptoms experienced by petitioner are directly related to the live multivalent nasal vaccination which induced severe acute inflammation of the nasal sinuses. Pet. Ex. 68 at 2. More specifically,

[t]he live virus and the storm-like release of inflammatory cytokines as a result of the memory immune response to previously encountered antigens provided by the multivalent design of the FluMist vaccine likely entered the local, collateral, and systemic circulation, and found their way to the labyrinth easily irritating the delicate tissues of this inner ear organ.

Pet. Ex. 68 at 2. Dr. Tuohy relied on *Djupesland* which showed that nasal drug delivery can lead to a breach in the blood brain barrier. *Id.*; Pet. Ex. 70.^{41, 42} Additionally, experimental viral labyrinthitis studies in animals have shown a correlation between viral labyrinthine infection and histopathologic and electrophysiologic changes, demonstrating the selective vulnerability of the inner ear cells to different viruses. Pet. Ex. 68 at 2. His own work has shown that an immune response to a cochlear-specific protein could cause damage to the cochlea, with hearing loss similar to what occurs in autoimmune sensorineural hearing loss, and he has "every reason to believe" that post-viral autoimmune-induced tissue damage could chronically affect the labyrinth

⁴¹ Per Gisle Djupesland, *Nasal drug delivery devices: characteristics and performance in a clinical perspective – a review*, 3 DRUG DELIVERY & TRANSLATIONAL RES. 42 (2012), filed as "Pet. Ex. 70."

⁴² *Djupesland* discussed in detail the factors of nasal anatomy, physiology, and aerodynamics that severely limit the potential for effective drug and vaccine delivery due to the nasal mucosal and filtration system. Further, substances absorbed from the nasal cavity are more likely to drain via veins that travel to the sinus cavernous, where the venous blood comes in contact with the walls of the carotid artery and will be outside the blood-brain barrier. Pet. Ex. 70 at 1, 4.

and occur following nasal vaccination with live virus.⁴³ *Id.* Petitioner’s history of “severe lingering upper respiratory infections and frequent symptoms of nasal congestion” made it likely that the introduction of a live virus intranasally provided an excessive inflammatory condition that overwhelmed his ability to clear the virus. *Id.* Whether the mechanism for petitioner’s chronic vertigo was viral persistence in the labyrinth or post-viral autoimmune sequelae, the acute onset and chronic nature of his symptoms are “clearly related” to the nasal vaccination with live virus. Pet. Ex. 68 at 2.

Dr. Tuohy agreed with Dr. Brookes that petitioner suffered post-viral labyrinthitis in 2014. He disagreed that petitioner had “non-existent migraine headaches” that caused chronic vertigo symptoms or that the treatment with corticosteroids was unsuccessful against his autoimmune-related vertigo. Pet. Ex. 68 at 2.

Dr Tuohy concluded that petitioner had an acute onset of true vertigo two to three days after the FluMist vaccine which was directly related to the nasal vaccine and the chronicity of petitioner’s vertigo symptoms was due to “persistence of virus in the labyrinth and/or post-viral autoimmune sequelae.” Pet. Ex. 68 at 3.

2. Dr. George Hicks

i. Qualifications

Petitioner filed three expert reports from his expert otolaryngologist, Dr. George Hicks. *See* Pet. Ex. 13, 69, 75. Dr. Hicks obtained his medical degree from St. Louis University School of Medicine. Pet. Ex. 14 at 1. He completed a general surgery residency at U.S. Public Health Service Hospital, an otolaryngology residency at Indiana University School of Medicine, and a preceptorship in neurotology at Wright Institute of Otolaryngology. *Id.* He is board certified in head and neck surgery by the American Board of Otolaryngology. *Id.* From 1996 to 2014, Dr. Hicks was the president of the Midwest Ear Institute. *Id.* Since 2014, he has served as an otologist and neurotologist at the Veterans Administration Hospital in Indianapolis. *Id.*

ii. Dr. Hicks’s First Report

In Dr. Hicks’s opinion, petitioner suffered from vestibular neuritis, commonly due to viral infection such as influenza or latent herpes simplex virus-1 (“HSV-1”) within the vestibular ganglion. Pet. Ex. 13 at 5. The diagnosis of and treatment for vestibular neuritis is a “diagnostic and therapeutic challenge” requiring a specialist with advanced training and interest in hearing and balance disorders. The petitioner was not seen by such a specialist until he was evaluated by Dr. Bronstein a year and a half after his symptoms began. Petitioner’s medical record is therefore “bloated with a multitude of contradictions, reversals, and improvisational diagnoses, and erroneous statements”, which reflect an inadequate understanding of vestibular disorders. *Id.* at 5-6, 19.

⁴³ Dr. Tuohy’s work involves murine experimental autoimmune encephalomyelitis (EAE) and human multiple sclerosis (MS). *See* Pet. Ex. 27.

According to Dr. Hicks, it is well-established that the inner ear can be selectively damaged by viruses, such as mumps, rubeola, herpes simplex, and influenza. Pet. Ex. 13 at 15. He agreed with Dr. Tuohy that the presence of memory cells from past vaccinations combined with the live attenuated FluMist vaccine could overwhelm and dismantle the balance between the level of attenuation and the level of immunogenicity, explaining petitioner's quick onset of symptoms within a few days of vaccination. *Id.* at 9.

Dr. Hicks deferred to Dr. Tuohy for the immunological explanation for how FluMist can cause vestibular neuritis, noting that damage to the cochlea and vestibule has been demonstrated following intranasal vaccine with influenza B viruses in ferrets. Pet. Ex. 13 at 15 (citing Pet. Ex. 45⁴⁴). Dr. Hicks also submitted an alternative explanation for petitioner's vestibular neuritis which involves the herpes group of viruses (HSV-1), well-known to remain latent in the ganglion cells after primary infection waiting for reactivation because the body cannot clear them. Pet. Ex. 13 at 15.

Dr. Hicks submitted two pathways that exist which "more likely led to petitioner's disease": 1) the intranasal vaccine initiated both a humeral and vigorous cellular response in pathologic ratios superimposed on a pre-existing HSV-1 memory cell population, prior influenza exposure, or both; 2) the intranasal vaccine resulted in a fulminant infection which compromised the immune system and reactivated latent HSV-1. Pet. Ex. 13 at 16. Dr. Hicks submitted that the FluMist virus was absorbed by the nasal membranes, which are rich in blood vessels, leading to rapid spread to the inner ear via branches of the maxillary artery and anterior vestibular artery. Either way, the intranasal vaccine reactivated latent HSV-1 in the ear with spread to the vestibular ganglion due to inflammatory response or marked stress response in the vestibular ganglion as a result of co-infection. *Id.*

According to Dr. Hicks, petitioner was in "excellent health" and as a pilot, had "exquisite spatial orientation," more so than the average person. He had no prior adverse effects from previous flu vaccinations with inactivated virus. Pet. Ex. 13 at 19. Petitioner received the live attenuated intranasal vaccine on October 17, 2013, and within a few days manifested mild symptoms which preceded the more classic signs and symptoms of vestibular neuritis, including vertigo, vomiting, nausea, and imbalance. *Id.*

In summary, the live attenuated nasal vaccine received by petitioner caused a stronger, more vigorous immune response than an intramuscular flu vaccine, which was then enhanced by a memory cell population from prior infection with HSV-1, prior influenza vaccines as suggested by Dr. Tuohy, or both. This triggered inflammation within the vestibular system resulting in a stress response. The stress response reactivated latent HSV-1 within the vestibular ganglion, spreading centrally and peripherally, causing damage to the vestibular system. The other biologically plausible explanation was provided by Dr. Tuohy. Either explanation adequately explains why the FluMist is responsible for petitioner's vestibular complaints and resulting damage. Pet. Ex. 13 at 19.

iii. Dr. Hicks's Second Report

⁴⁴ Kyle E. Rarey et al., *Inner Ear Changes in the Ferret Model for Reye's Syndrome*, 5 AM. J. OTOLARYNGOLOGY 191 (1984), filed as "Pet. Ex. 45."

In his second report, Dr. Hicks addressed the opinions of respondent's experts, Drs. Collins and Bigelow while maintaining his opinion that petitioner suffered from vestibular neuritis with sudden onset of vertigo, nausea, vomiting, disequilibrium, imbalance, and visual difficulties, with no associated hearing loss. Pet. Ex. 69 at 1. Dr. Hicks disagreed that petitioner's vestibular issues were caused by migraines or that he responded to migraine medication. Pet. Ex. 69 at 1.

Dr. Hicks disagreed that petitioner had labyrinthitis because labyrinthitis includes hearing loss, which petitioner did not have. Pet. Ex. 69 at 1. He claimed that Dr. Collins confused vestibular neuritis with Autoimmune Inner Ear Disease ("AIED") which is characterized by vestibular symptoms and sensorineural hearing loss which petitioner did not have. Further, Dr. Collins discussed varicella zoster virus ("VZV") and Ramsay Hunt Syndrome⁴⁵, which is irrelevant to his discussion of HSV-1 because petitioner does not have Ramsay-Hunt Syndrome. *Id.* Still further, Dr. Collins's discussion of Meniere's disease was inapplicable because Meniere's disease involves vestibular and auditory symptoms and petitioner did not have auditory symptoms. *Id.*

Dr. Hicks defended his theory of HSV-1 reactivation from the FluMist vaccine from Dr. Collins's opinion that no proof exists of HSV-1 reactivation and the literature relied on "do[es] not shed light on whether herpes virus infection causes vestibular neuritis." Pet. Ex. 69 at 5. In response, Dr. Hicks submitted that reactivation of latent HSV-1 can occur from "relatively innocuous genotoxic stresses," such as sunlight, fever, common cold, and physical or emotional distress which leads to tolerable symptoms, but when reactivation is in the inner ear, it leads to "debilitating symptoms." Pet. Ex. 69 at 5. The literature he submitted reported three patients with chronic recurrent vestibular neuritis who had evidence of inflammation in the temporal bone postmortem, even though they did not have vertigo at the time of death. *Id.* (citing Pet. Ex. 50⁴⁶). This is because when HSV-1 is reactivated, the inflammation/swelling of the superior vestibular and facial nerves which are located in narrow, long, bony channels, causes the symptoms experienced in both vestibular neuritis and Bell's palsy. Pet. Ex. 69 at 6. In its acute onset stage, vestibular neuritis is treated with corticosteroids, not antivirals, which target the inflammatory response of the vestibular nerve. Dr. Hicks agreed that there are no antiviral treatments for latent HSV-1. *Id.* However, he postured even without "direct proof", vestibular neuritis has an incidence of 3.5 per 100,000 and is the second most common cause of vertigo, with reactivation of latent HSV-1 believed to be the most likely cause due to its presence in 60-90% of the world population and detected in the DNA and RNA in human vestibular ganglion.⁴⁷ *Id.* He added that the inner ear is inviolate, it cannot be biopsied, "needled", or have tissue samples extracted during ongoing active inner ear disease without causing permanent loss of hearing and balance function. Pet. Ex. 69 at 6-7. He added that there is not always a scientific explanation for certain diseases and symptoms. *Id.*

⁴⁵ Ramsay Hunt Syndrome is "herpes zoster involving the facial and vestibulocochlear nerves, often associated with transitory ipsilateral facial paralysis and herpetic vesicles of the external ear or tympanic membrane; there may or may not be tinnitus, vertigo, and hearing disorders." *Dorland's* 1815.

⁴⁶ Akira Ishiyama et al., *Histopathology of Idiopathic Chronic Recurrent Vertigo*, 106 LARYNGOSCOPE 1340 (1996), filed as "Pet. Ex. 35."

⁴⁷ Dr. Hicks did not provide a citation in his report for either of these statistics.

In response to Dr. Bigelow's opinion that the FluMist vaccine could not access the inner ear or reactivate HSV-1, Dr. Hicks argued that intranasal application of medications enter systemic circulation via a rich vascular plexus in the nasal mucosa, passing the blood brain barrier into the central nervous system. Pet. Ex. 69 at 2, 8. The membranes of the nose, sinuses, meatuses, septum, and the highly vascularized nasal turbinates are supplied by branches of the ophthalmic, maxillary, and superior branch of the facial arteries, which enables bypassing of the blood brain barrier to the central nervous system and the brain. *Id.* at 8. This is desirable for drugs intended for local action and systemic absorption like vaccines. *Id.* It is therefore, "not unreasonable" that the FluMist vaccine traveled from the nasopharynx up the Eustachian tube to the middle ear, then passed into the inner ear via the round or oval windows and caused a stress response that reactivated latent HSV-1 in the geniculate and vestibular ganglion. *Id.* at 8-9.

Dr. Hicks further disagreed that petitioner would have experienced hearing loss or tinnitus due to damage caused to the cochlea if there was reactivated HSV-1 in the inner ear arguing just as reactivated HSV-1 can cause sensorineural hearing loss in the cochlea without vestibular symptoms, it can also cause vestibular symptoms without hearing loss or tinnitus. Pet. Ex. 69 at 9.

Dr. Hicks acknowledged that petitioner could have suffered from an ear infection from the spread of a viral infection in the middle ear during his upper respiratory infection, but his medical records do not show any ear examination until six months after vaccination and petitioner never mentioned otologic symptoms. Pet. Ex. 69 at 9. Therefore, the FluMist vaccine was the "precipitating factor which reactivated HSV-1 with subsequent vestibular symptoms." *Id.*

Further, Dr. Hicks submitted that vestibular neuritis should initially be treated with steroids to reduce the inflammatory response within the vestibular nerve and vestibular suppressants to control nausea and vomiting. It is "axiomatic" that vestibular suppressants should not be given past the first week of acute symptoms because they may "compromise/decrease the central nervous system's ability to adjust, compensate, and heal the vestibular injury." Pet. Ex. 69 at 9. Petitioner received no medical treatment for the first two weeks after onset of his symptoms and was then prescribed twice the normal dose of Betahistamine and Prochlorperazine for one month. *Id.* at 10. The use of these medications most likely reduced petitioner's symptoms temporarily but interfered with long-term resolution and recovery of his central nervous system. This explains the vestibular testing results, which Dr. Bigelow claimed showed no evidence of vestibular dysfunction. It also explains why physical therapy did not resolve petitioner's symptoms, the subsequent exacerbations, and the persistence of petitioner's balance problems. *Id.* at 9-10.

Dr. Hicks agreed migraine is a possible diagnosis and could have contributed to petitioner's symptoms, but in his opinion, petitioner's treating physicians accepted migraine as "a diagnosis of convenience" without any proof. Pet. Ex. 69 at 10. Further, other than Amitriptyline which was "ineffective", no alternative medications, dietary measures, or a neurology consultation were considered to treat petitioner's migraines. *Id.*

Dr. Hicks disagreed that *Greco* concluded that HSV-1 infection “is the most likely cause of vestibular neuritis, not the flu virus” arguing that FluMist acts as “stress” causing HSV-1 reactivation. Pet. Ex. 38.⁴⁸ Dr. Hicks opined that *Greco* supports his opinions that “HSV-1 has been detected...in human vestibular ganglion”; that latent HSV-1 in the geniculate and vestibular ganglions can spread; and that “the lesion lies in the vestibular nerve, specifically the superior vestibular nerve, without auditory or neurologic findings”. Pet. Ex. 69 at 11. Further, *Greco* notes the similarity between vestibular neuritis and Bell’s palsy, as both nerves are confined in bony channels and both have HSV-1 etiology. *Greco* also states vestibular suppressants should only be used during the acute phase so as not to impede central vestibular compensation. *Id.*

Dr. Hicks disagreed that petitioner’s symptoms were triggered by an upper respiratory infection 4-5 months after vaccination, stating that is “ignoring the obvious initial precipitating factor and timeline involved.” Pet. Ex. 69 at 11. Dr. Hicks conceded he had never seen any case of dizziness or migraine associated with intranasal vaccination, but believed petitioner experienced “unanticipated sequelae” from the FluMist with systemic spread. *Id.*

Dr. Hicks maintained that the medical records demonstrate the vaccine “was not only a ‘but for’ cause of the injury, but a substantial factor in precipitating” petitioner’s vestibular neuritis, an inner ear disease without hearing loss. Pet. Ex. 69 at 12. He added that expert opinions can be based on circumstantial evidence rather than peer-reviewed scientific literature to prove causation, and the instant matter provides a link between the vaccine and inner ear symptoms, “a sequence hitherto unproven in medicine.” *Id.* Dr. Hicks then restated his theory and opinions in this case as detailed in his first report. *Id.* at 13-18.

iv. Dr. Hicks’s Third Report

In his third report, Dr. Hicks explained that his and Dr. Tuohy’s theories coexist. Pet. Ex. 75 at 2. Dr. Tuohy’s theory involves FluMist as the “trigger” of an autoimmune reaction, leading to a stress response that, as explained by Dr. Hicks, can reactivate latent HSV-1 in the geniculate and vestibular ganglion causing an inflammatory response of the superior vestibular nerve leading to petitioner’s symptoms. *Id.* Vestibular neuritis is “an inner ear disorder reflecting inflammation of the vestibular nerve of the inner ear and its connection to the brain,” which could be caused by a “continuum of the seamless cascade of events initiated by the intranasal vaccination as identified by Dr. Tuohy.” *Id.* There is “no clear boundary” between the vaccine and petitioner’s symptoms. Even if respondent’s experts’ opinions are accepted and petitioner’s symptoms are determined to be related to migraines, “trigger identification is the mainstay of migraine treatment,” and the vaccine is the only possible trigger in this case. *Id.*

Dr. Hicks disagreed that petitioner’s vestibular testing was unremarkable or unresponsive of vestibular neuritis because the testing was not reliable. Pet. Ex. 75 at 2. He noted that the testing included a head impulse test that was within normal limits without Frenzel lenses, a video head impulse test (“vHIT”) which showed “abnormal response from the left posterior canal”, and a cVEMP test which was normal. *Id.* But that Dr. Bronstein was “a little suspicious about the unexpected findings” of the cVEMP test and even though the six canal vHIT test was normal,

⁴⁸ A. Greco et al., *Is Vestibular Neuritis an Immune Related Vestibular Neuropathy Inducing Vertigo?*, J. IMMUNOLOGY RES. (2014), filed as “Pet. Ex. 38” and “Resp. Ex. C, Tab 4.”

Dr. Bronstein commented that it was “a new test and confidence in my interpretation was limited.” *Id.* Dr. Hicks added that other vestibular tests had variable results and posturography testing, recommended twice, was not performed and could have identified deficiency in the vestibular system or if malingering was a factor. *Id.*

Dr. Hicks further disagreed with Dr. Bigelow that if flu vaccine passed the blood brain barrier there would have been symptoms of viral encephalitis, because there are other mechanisms for viral dissemination to the inner ear that do not involve encephalitis. Pet. Ex. 75 at 3. He highlighted references relied on by Dr. Bigelow that document peripheral injury without cochlear hearing loss despite his assertion that the virus could not enter the inner ear without hearing loss or tinnitus. *Id.* (referencing Resp. Ex. F, Tab 5⁴⁹, Tab 6⁵⁰, and Tab 7⁵¹).

Dr. Hicks restated his opinion that petitioner’s delayed treatment during the acute stage of injury could have interfered with normal compensation. Pet. Ex. 75 at 3. Conceding that some patients never fully recover from vestibular neuritis, Dr. Hicks maintained that the etiology here is “quite clear”: petitioner’s initial vestibular neuritis never completely resolved, and his recurring symptoms are due to “uncompensated vestibular neuritis on the ipsilateral side.” *Id.* at 4.

Dr. Hicks agreed that petitioner’s medical records lack detailed medical history and physical information but claimed that Dr. Bigelow relied on the records to “validate his diagnosis of vestibular migraine” even though Dr. Bronstein’s record mentions that “vestibular neuritis [is] not fully compensated” and “presence of migraine.” Pet. Ex. 75 at 4. Dr. Hicks maintained that the prescribed medication for migraine was ineffective. *Id.* Further, petitioner was initially diagnosed with labyrinthitis. No physical examination was done until May 9, 2014 after his vestibular neuritis had “fully resolved”, and then he was diagnosed with cervicogenic dizziness. Pet. Ex. 75 at 4. In November 2014, after an audiologist suggested possible vestibular migraines, Dr. Khemani “adopted” the diagnosis, which was “solidified” by the time petitioner presented to Dr. Bronstein in early 2015. *Id.*

In Dr. Hicks’s opinion, the FluMist played a role in petitioner’s “cascade of events.” Pet. Ex. 75 at 4. Vestibular migraine is “a symptom complex with no test, no clear evidence-based establishing mechanism, and no clear diagnostic findings which distinguishes it from recurrent, uncompensated vestibular neuritis.” *Id.* Petitioner did not have any of the common symptoms of migraine and did not experience any dizziness between 2006 and 2013 until he received the FluMist. *Id.* The family history of migraine attributed to petitioner’s mother shows “no documentation whether this was a ‘self or medical’ diagnosis.” *Id.* Finally, there is no evidence in the record that identifies any migraine triggers or avoidance, and it does not appear that petitioner’s symptoms fulfill the International Headache Society’s diagnostic criteria for migraine. *Id.* at 4, 6.

⁴⁹ Harold F. Schuknecht & Ken Kitamura, *Vestibular Neuritis*, 90 ANNALS OTOLOGY, RHINOLOGY, & LARYNGOLOGY 1 (1981), filed as “Resp. Ex. F, Tab 5.”

⁵⁰ Robert. W Baloh et al., *Vestibular neuritis: clinical-pathologic correlation*, 114 OTOLARYNGOLOGY HEAD NECK SURGERY 586 (1996), filed as “Resp. Ex. F, Tab 6.”

⁵¹ Céline Richard & Fred H. Linthicum Jr., *Vestibular Neuritis: The Vertigo Disappears, the Histological Traces Remain*, 33 OTOLOGY & NEUROTOLOGY e59 (2012), filed as “Resp. Ex. F, Tab 7” and “Pet. Ex. 43.”

While conceding that diagnoses of vestibular neuritis and vestibular migraine are based on clinical information with no diagnostic testing available, Dr. Hicks declared it “indisputable” that petitioner’s symptoms were “initiated (vestibular neuritis) or exacerbated (vestibular migraine)” by his vaccine in October 2013. Pet. Ex. 75 at 5. Dr. Tuohy’s and his opinions are complementary in explaining the sequence of events and role of the vaccine as a but-for cause of petitioner’s illness. *Id.*

Succinctly, Dr. Hicks claimed that the medical records show that migraine medication was ineffective in treating petitioner’s symptoms. Pet. Ex. 75 at 6. Dr. Collins does “not grasp the role of the ‘stressor’ effect of the reactivated latent HSV-1.” *Id.* Dr. Hicks’s references⁵² support the role of corticosteroids for anti-inflammatory effects and treatment in the acute stage of vestibular neuritis, but petitioner never received corticosteroids or a thorough neurologic exam and was “mis-diagnosed” with labyrinthitis until May 2014. *Id.*; Pet. Ex. 36.⁵³ Finally, antivirals are ineffective for HSV-1 infections like Bell’s palsy, vestibular neuritis, and sudden sensorineural hearing loss because when a vaccine is the trigger of the symptomatic inflammatory response the response is to corticosteroids, not antivirals. Pet. Ex. 75 at 6.

According to Dr. Hicks, the diagnosis of vestibular neuritis depends on “an appropriate history and physical,” which is not reflected in petitioner’s records. Clinical experience demonstrates that early intervention such as the use of corticosteroids in the acute period is beneficial. Pet. Ex. 75 at 7. Dr. Hicks clarified that his references to VZV reactivation, Ramsay-Hunt Syndrome, and AIED were to emphasize that vestibular neuritis is not the same as any of those conditions. *Id.*

Dr. Hicks argued that two references relied on by Dr. Collins “basically support” his position that “vestibular neuritis is believed to be an acute viral or post-viral inflammatory disorder of the vestibular portion of the eighth cranial nerve.” Pet. Ex. 75 at 7. Further, Dr. Collins dismissed those portions of his references related to the additional susceptibility of the superior vestibular nerve to inflammatory effects and discussion of the inflammatory response to the stressor—in this case, the vaccine. *Id.* Dr. Hicks maintained that vestibular neuritis is “a clinical problem with a clinical solution.” *Id.*

B. Respondent’s Experts

1. Dr. Douglas Bigelow

i. Qualifications

Respondent filed two expert reports from his expert otorhinolaryngologist, Dr. Douglas Bigelow. *See* Resp. Ex. A, F. Dr. Bigelow has a medical degree from the University of Minnesota School of Medicine. Resp. Ex. B at 1. He completed a residency in otolaryngology and head and neck surgery at Washington University in St. Louis and received postgraduate training in otology, neurotology, and cranial base surgery at Midwest Otologic Group and the

⁵² Dr. Hicks cited his references 13-16, but reference 13 was the only one of those referenced actually filed.

⁵³ Michael Strupp et. al., *Methylprednisolone, Valacyclovir, or the Combination for Vestibular Neuritis*, 351 NEW ENG. J. MED. 354 (2004), filed as “Pet. Ex. 36.”

University of Zurich. *Id.* He is board certified in otolaryngology and neurotology. *Id.* at 2. Since 2001, Dr. Bigelow has been an associate professor of otolaryngology and head and neck surgery at the University of Pennsylvania School of Medicine. *Id.* Since 2002, he has served as the director of the division of otology and neurotology at the University of Pennsylvania Medical Center. *Id.*

ii. Dr. Bigelow's First Report

Dr. Bigelow noted that the medical records “do not provide much detail or information,” being mostly in the form of letters between petitioner’s physicians. Resp. Ex. A at 11. However, while the cause of petitioner’s initial symptoms was unknown, petitioner clearly had an illness with dizziness and nausea that began 2-3 days after his receipt of the flu vaccine. *Id.* at 14. There was no mention of hearing problems or tinnitus at that time. *Id.* Dizziness and nausea without hearing loss can have many etiologies, including inner ear problems, neurologic conditions, cardiac conditions, psychiatric issues, and gastrointestinal problems, of which petitioner had a long history. *Id.*

Dr. Bigelow pointed out that petitioner was given many possible diagnoses but never a “single unifying diagnosis” throughout the duration of his illness. Resp. Ex. A at 14-15. According to his records, petitioner recovered from his initial symptoms in December 2013. His chronic and persistent symptoms began after an upper respiratory infection he developed between February 11, 2014 when he presented to his PCP and April 11, 2014 when he saw Dr. Brookes. Thereafter, the most referenced diagnosis was vestibular migraine. *Id.* at 15. The upper respiratory infection in February 2014 precipitated the onset of chronic symptoms and is too remote in time to be associated with the flu vaccine in October 2013. Petitioner had a well-documented history of recurrent upper respiratory infections prior to his receipt of the subject vaccine. *Id.* Further, his treating physicians in 2013 were not made aware of his history of episodes of recurrent dizziness in 2006. Although petitioner denies that he had vertigo, his records show very detailed episodes of dizziness in 2006, and it is unlikely that his physician would fabricate such a detailed description of his symptoms. *Id.*

According to Dr. Bigelow, the literature relied on does not support Dr. Tuohy’s theory that petitioner developed a persistent inner ear inflammatory disease due to “vaccine-induced reactivation of latent memory T cells and B cells specific for cross-protective antigens” initially primed through either prior infection with influenza or prior influenza vaccination. Resp. Ex. A at 15. *Carter*⁵⁴ reported that the incidence of solicited and non-solicited reactogenicity events from live attenuated influenza vaccine appeared to be numerically lower after the second vaccine dose in year 1 or after revaccination in year 2, than after the first vaccine dose in year 1, and ear disorders and lower respiratory tract illnesses occurred in significantly fewer live attenuated influenza vaccine recipients after the second dose. *Id.* *Diez-Domingo* reported that the rate of any solicited adverse events was lower after the second vaccine dose than the first dose. These studies “suggest that the risk of development of an adverse event in live human patients is less with reactivation than with initial vaccination.” *Id.*; Resp. Ex. A, Tab 1⁵⁵ at 4.

⁵⁴ Natalie J. Carter & Monique P. Curran, *Live Attenuated Influenza Vaccine (FluMist®; Fluenz™)*, 71 DRUGS 1591 (2011), filed as “Pet. Ex. 20.”

⁵⁵ Javier Diez-Domingo et al., *Safety and tolerability of cell culture-derived and egg-derived trivalent influenza*

Further, Dr. Bigelow argued, Dr. Tuohy's theory is flawed because it does not fit the anatomy of the ear. Although the nose and ear are both located in the head and within close anatomic proximity, the blood supply to the inner ear is not connected to the nasal mucosa and sinuses. Resp. Ex. A at 16. The labyrinthine artery provides the blood supply to the cochlea and vestibular end organs in the inner ear. It is a branch of the anterior inferior cerebellar artery, which supplies blood to part of the cerebellum, and originates from the basilar artery, which is the main blood vessel forming posterior circulation for the brain. *Id.* The labyrinthine artery is not connected to the nasal vasculature. *Id.* Therefore, if the influenza vaccine caused inflammatory cytokines that circulated to the inner ear systemically via the labyrinthine artery, petitioner would have been expected to have experienced hearing loss or tinnitus, because the labyrinthine artery supplies blood to both the vestibular end organs and the cochlea. This would have affected sensory systems of hearing and balance. *Id.* Petitioner had no hearing loss or tinnitus. *Id.*

Further, Dr. Tuohy's theory that the chronicity of petitioner's symptoms was due to induction of post-infectious autoimmune inner ear disease is also flawed, because if the flu vaccine had caused a post-infectious inner ear disease, there would have been rapid onset of bilateral sensorineural hearing loss. Resp. Ex. A at 16. Rather, petitioner's chronic symptoms were described as "intermittent disequilibrium," with no hearing loss and normal audiogram, all inconsistent with an autoimmune inner ear disease. *Id.*

Dr. Bigelow agreed that it is well-known that measles and mumps infections can be associated with sensorineural hearing loss, but evidence is lacking that influenza vaccine can cause inner ear disease. Resp. Ex. A at 16. The *Rarey* study relied on by Dr. Hicks does not support this case. *Id.*; Pet. Ex. 45.⁵⁶

Dr. Bigelow pointed to several problems with Dr. Hicks's theory of HSV-1 reactivation. Resp. Ex. A at 17. First, it is extremely unlikely that a vaccine would cause enough stress to stimulate reactivation of latent HSV-1 causing secondary ear injury. No studies associating flu vaccine or any other vaccine with reactivation of latent HSV-1 were cited. *Id.* Second, Dr. Hicks proposed that the FluMist enters the rich vascular plexus of the nasal membranes, leading to rapid hematogenous spread to the inner ear via branches of the maxillary artery. *Id.* Again, the labyrinthine artery, which supplies blood to the inner ear, is not connected to the nasal vasculature or the maxillary artery, so the FluMist would not enter the ear via the maxillary artery. *Id.* Dr. Bigelow agreed that it was feasible that a virus could enter the inner ear circulation via the anterior vestibular artery, which is a branch of the labyrinthine artery that provides circulation to the cochlea. However, if this occurred and caused damage to the vestibular system, it would also cause damage to the cochlea since the viral load would be distributed there as well. *Id.* at 17-18. There is no evidence of damage to the cochlea in petitioner's case. *Id.* at 18.

Dr. Bigelow also agreed that the Eustachian tube connects the nasopharynx to the middle ear and could spread virus into the inner ear via the round or oval windows. Resp. Ex. A at 18. However, if this occurred, petitioner would have been expected to have a middle ear infection or

vaccines in 3 to <18 year-old children and adolescents at risk of influenza-related complications, 49 INT'L J. INFECTIOUS DISEASE 171 (2016), filed as "Resp. Ex. A, Tab 1."

⁵⁶ Rarey et al., *supra* note 44.

inflammation with symptoms of fluid in the ear and hearing loss. There were no such symptoms reported, and this theory is therefore unsupported by the medical records. *Id.*

Further, if there was significant injury to the vestibular system from a virus or some other source, vestibular testing would be abnormal. Petitioner's vestibular testing in April 2014 and again in November 2014 failed to identify significant vestibular asymmetry or pathology other than Dr. Low's conclusion that the testing was consistent with vestibular migraine. Resp. Ex. A at 18.

Dr. Bigelow opined that no objective evidence exists to support Drs. Hicks and Tuohy's opinions that petitioner's symptoms are related to inner ear vestibular pathology resulting from the influenza vaccine. Three different treating physicians identified petitioner's symptoms as vestibular migraines. Resp. Ex. A at 18. Dr. Bigelow acknowledged that it is difficult to differentiate inner ear disorders from migraine, but over time, migraine symptoms tend to be more persistent, commonly associated with movement intolerance, and tend to have longer periods of consistent symptoms. *Id.* Dr. Bronstein's records reflect that petitioner suffered from intermittent migrainous-type headaches with pain behind the eyes and left retro-orbital pain; he had migraines in the past, a family history of migraines, and symptoms of motion and movement intolerance, disequilibrium, and disorientation. *Id.* at 19. Dr. Bigelow explained that vestibular migraines do not always have a headache component, and dizziness without headache can be due to migrainous etiology. *Id.*

Further, Dr. Bigelow noted that petitioner also had cervical spine pathology, with C3/C4 disc bulge and paresthesia of the fingertips noted by Dr. Khemani as a potential contributing factor to his persisting symptoms. Cervical spine pathology and injuries are known to be associated with dizziness. Resp. Ex. A at 19.

Dr. Bigelow agreed that, though the evidence is circumstantial, the most popular theory for the pathogenesis of vestibular neuritis is viral infection, and HSV-1 is the most likely cause, not the influenza virus. Resp. Ex. A at 20. Further, the literature discusses a lesion on the vestibular nerve, not involvement of inflammation in the inner ear as the cause. Therefore, if petitioner's initial episode of dizziness in October was due to vestibular neuritis, it would have been because of a lesion in the vestibular nerve, not inner ear inflammation as opined by Drs. Tuohy and Hicks. *Id.*

Dr. Bigelow concluded he has never seen any cases of dizziness or migraine associated with flu vaccine, and temporal association alone does not provide proof of causation. Resp. Ex. A at 20-21. Therefore, he concluded that petitioner's symptoms were unrelated to the intranasal influenza vaccine he received in October 2013. The onset of his recurring symptoms appears to have been triggered by an upper respiratory infection sometime after February 11, 2014 and before he saw Dr. Brookes months after the FluMist vaccine. Neither the records nor the theories offered by Drs. Tuohy and Hicks establish the vaccine as the cause of petitioner's dizziness and persistent symptoms. *Id.* at 21.

iii. Dr. Bigelow's Second Report

In his second report, Dr. Bigelow submitted that Dr. Tuohy's opinion that petitioner's "benign dizziness" from repeated URIs in 2006 could "never be mistaken" for the true vertigo symptoms he experienced after the October 2013 vaccination was unsupported in the medical record. Resp. Ex. F at 1. The medical records document petitioner's presenting to Dr. Warrington in July 2006 for evaluation of dizziness following three episodes of recurrent true vertigo in 2006, lasting 10 to 36 hours each and "consist[ing] of a sensation of spinning associated with nausea and it happens on moving. It does not appear as if the vertigo is strictly positional" and there was no hearing loss, tinnitus, or aural fullness. *Id.* at 2 (citing Pet. Ex. 4 at 78). Audiogram was normal except for a slight drop at 4000 Hz. *Id.* Dr. Bigelow concluded that despite petitioner's affirmation to the contrary, the medical record clearly details petitioner describing his dizziness as a spinning sensation which is, by definition, vertigo, and it is "quite unlikely that [petitioner's] physician would have "fabricated such a detailed description." Resp. Ex. F at 2.

Dr. Bigelow also pointed out that petitioner's medical history documented his history of recurrent upper respiratory infections prior to the vaccine at issue and the associated recurrent episodes of vertigo in 2006 which began with upper respiratory symptoms "quite similar" to what occurred after an upper respiratory infection in February 2014. Resp. Ex. F at 2. The medical records further document that petitioner had full recovery in December 2013 following an illness post the October 2013 vaccine and after taking medication for dizziness for "only for a few days." Petitioner then reported feeling well, without dizziness, and requested a return-to-work certificate. *Id.* Dr. Brookes' medical record for April 15, 2014 documented petitioner's persistent and recurrent symptoms that began after an upper respiratory infection he suffered in February 2014. The upper respiratory infection in February of 2014 was the onset of petitioner's chronic and persistent symptoms which was "not even remotely associated" with his October 17, 2013 influenza vaccine. *Id.*

Further, Dr. Bigelow pointed to three of petitioner's treating physicians, Drs. Low, Khemani, and Bronstein who attributed petitioner's ongoing symptoms to vestibular migraine. Dr. Tuohy argued that this was a misdiagnosis, and that petitioner had no history of migraine in his records. Resp. Ex. F at 2. However, petitioner's medical records document a history of migraine and a family history of migraine in his mother. *Id.* Dr. Bigelow opined that it is well-known that vestibular migraines can present as dizziness without headache, but if headache is present it can manifest as peri- or retro-orbital in nature. Petitioner's medical records document headache and pain above the right eye in 2011 and in August 2013 two months prior to vaccination. *Id.* at 3. Dr. Bigelow concluded based on petitioner's medical records, petitioner had a documented prior history of migraines, a family history of migraines, and recurrent peri- and retro-orbital pain which is common with migraines, headaches, and symptoms that were "significantly worse" when he was not taking amitriptyline, a medication that can be used for migraine management. *Id.*

Dr. Bigelow explained that vestibular migraines can be difficult to treat as patients often do not respond or only partially respond to specific medication. Here, only one medication was used, though it is common to try a series of medications to find one that works for the individual. However, it would be an "error in medical judgment" to conclude that petitioner did not have vestibular migraine because he only had partial or 60-75% improvement rather than a complete response to the amitriptyline. Resp. Ex. F at 3. Dr. Bigelow concluded, based on petitioner's

medical record, vestibular migraine was the cause of his persistent symptoms of dizziness. Dr. Tuohy's opinions to the contrary are not supported by petitioner's medical record and demonstrate a lack of understanding of vestibular migraine, because he focuses on migraine headaches rather than the vestibular effects that can be caused by a migrainous condition. *Id.*

As to Dr. Hicks, Dr. Bigelow noted his agreement that migraines could be a potential diagnosis though he argued that the medical records did not document issues with motion intolerance. Dr. Bigelow pointed to Dr. Bronstein's medical records documenting motion issues as "dizzy or disorientation feelings can increase in elevators, in aeroplanes if they tilt... and to some extent in a car or in trains or tubes." Resp. Ex. F at 3-4. Further, the medical records reflect that petitioner did have significant partial improvement of symptoms with amitriptyline rather than no improvement as suggested. *Id.* at 4.

Dr. Bigelow again addressed Dr. Hick's theory that the FluMist passed through the blood brain barrier into the central nervous system, noting that he was unaware of any evidence that demonstrates this theory, and petitioner did not suffer from or have evidence of viral encephalitis which would likely have occurred had the vaccine passed the blood brain barrier into the central nervous system. Resp. Ex. F at 4. Dr. Bigelow pointed out that *Djupesland* relied on by Dr. Hicks discussed Midazolam, a drug designed to easily pass the blood brain barrier but did not discuss influenza vaccine. *Id.*; Pet. Ex. 70.⁵⁷ In contrast, *Planty*, examined the question of possible blood brain barrier penetration of influenza vaccine in animals and did not find any such evidence. Resp. Ex. F at 4; Resp. Ex. F, Tab 1.⁵⁸

Dr. Bigelow noted that initially Dr. Hicks attributed petitioner's symptoms to injury of the inner ear, but in his second report, attributed the symptoms to vestibular neuritis resulting from reactivation of latent HSV-1. Resp. Ex. F at 5. Dr. Bigelow was unable to find any support for influenza vaccine reactivating latent HSV-1 virus in the geniculate and vestibular ganglion causing an inflammatory response of the superior vestibular nerve. *Id.* He did, however, find articles demonstrating successful treatment of active herpes virus infections with the influenza vaccine. He added that Dr. Hicks provided no proof other than his own belief that the influenza virus reactivated latent HSV-1. *Id.* Dr. Bigelow challenged Dr. Hicks's claim that the infection may involve the vestibular nuclei in the brain if symptoms persist longer than six months, stating that the *Arbusow* study Dr. Hicks relied on for this proposition neither states nor infers a correlation between length of symptoms and involvement of vestibular nuclei in the brain with HSV-1. *Id.*; Pet. Ex. 33.⁵⁹

Dr. Bigelow explained that patients with vestibular neuritis typically have severe injury to the vestibular nerve on the affected side or unilaterally. Resp. Ex. F at 5. If petitioner experienced persistent symptoms from an active HSV-1 infection in the superior vestibular nerve or persistent inflammation of that nerve, vestibular testing would show abnormalities. *Id.* Dr.

⁵⁷ *Djupesland*, *supra* note 41.

⁵⁸ Camille Planty et al., *Evaluation of the potential effects of AS03-adjuvanted A(H1N1)pdm09 vaccine administration on the central nervous system of non-primed and A(H1N1)pdm09-primed rats*, 13 HUMAN VACCINES & IMMUNOTHERAPEUTICS 90 (2017), filed as "Resp. Ex. F, Tab 1."

⁵⁹ V. Arbusow et al., *Detection of herpes simplex virus type 1 in human vestibular nuclei*, 55 NEUROLOGY 880 (2000), filed as "Pet. Ex. 33."

Bigelow submitted several histopathologic autopsy studies confirming this.⁶⁰ *Id.* Vestibular testing performed on petitioner by Dr. Bronstein on multiple occasions were unremarkable and showed no vestibular deficit, which suggests no permanent or active vestibular injury or abnormality. *Id.*

Finally, Dr. Bigelow submitted the suggestion that the prescribed Betahistine and Prochlorperazine interfered in the long-term resolution and recovery of petitioner's central nervous system compensation is unsupported in the medical records. Resp. Ex. F at 6. According to Dr. Bigelow, the "vast majority" of patients with vestibular neuritis will recover over time and become asymptomatic, even if they have permanent vestibular deficit, because they will compensate for that deficit. *Id.* Further, a small number of patients with vestibular neuritis will have persistent symptoms that never resolve, and the etiology for that is often unclear, but petitioner was not documented as having a vestibular deficit and he fully recovered from his initial illness following the vaccination. *Id.* A study by *Huppert* concluded that vestibular neuritis has an "extremely low" recurrence rate at 1.9%, and in cases of recurrence, the vestibular neuritis affects the contralateral or opposite side. *Id.*; Resp. Ex. F, Tab 8.⁶¹ Based on petitioner's clinical history, it is extremely unlikely that petitioner's ongoing symptoms were caused by vestibular neuritis followed by recurrent vestibular neuritis on the same side, or that his symptoms were related to the October 2013 influenza vaccination. *Id.*

2. Dr. Kathleen Collins

i. Qualifications

Respondent filed two reports from Dr. Kathleen Collins. *See* Resp. Ex. C, E. Dr. Collins has a medical degree and a Ph.D. from Johns Hopkins University School of Medicine. Resp. Ex. D at 1. She completed a residency in internal medicine at Brigham and Women's Hospital. *Id.* Dr. Collins also completed a clinical fellowship in infectious disease rotating through several Boston hospitals, a research fellowship in medicine at Harvard University, and a postdoctoral fellowship at Massachusetts Institute of Technology. *Id.* She is board certified in internal medicine and infectious disease. *Id.* at 6. She has been a professor of virology at the University of Michigan School of Medicine for the past 15 years. Resp. Ex. C at 1. Since 1998, Dr. Collins has been a staff physician at both the University of Michigan Hospital and Ann Arbor Veterans Administration Hospital. Resp. Ex. D at 2.

ii. Dr. Collins's First Report

In her first report, Dr. Collins described vestibular neuritis, vestibular migraine, autoimmune disease, live attenuated influenza virus vaccine (LAIV), HSV-1, and Ramsey Hunt Syndrome. Resp. Ex. C at 4; Resp. Ex. C, Tab 1-10. These terms have been defined previously in this decision.

⁶⁰ Schuknecht & Kitamura, *supra* note 49; Baloh et al., *supra* note 50; Richard & Linthicum, *supra* note 51.

⁶¹ D. Huppert et al., *Low recurrence rate of vestibular neuritis: A long-term follow-up*, 67 NEUROLOGY 1870 (2006), filed as "Resp. Ex. F, Tab 8."

Dr. Collins added that LAIV is temperature-sensitive, a property that limits the replication of the vaccine viruses at body temperature and restricts LAIV from replicating in the human lower airways. Resp. Ex. C at 4; Resp. Ex. C, Tab 8.⁶² HSV-1 causes vesicular lesions of the oral mucosa commonly known as “cold sores” and clinical disease in other anatomical locations including the genitalia, liver, lung, eye, and central nervous system. Once HSV-1 infection has occurred, it lives in a latent state in nerve cell bodies in the ganglion and can reactivate. Frequency and reactivation are determined by many factors including immunodeficiency and stress. Precipitating factors for recurrence include exposure to sunlight, fever, menstruation, emotional stress, and trauma to the primary area of infection, such as trigeminal nerve manipulation in oral infection or dental extractions. Vaccination has not been reported to cause recurrences of HSV. Resp. Ex. C at 4; Resp. Ex. C, Tab 9.⁶³ Ramsey Hunt Syndrome is linked to reactivation of latent varicella zoster virus (VZV)⁶⁴, which resides within the geniculate ganglion with subsequent spread of the inflammatory process to involve the eighth nerve, resulting in auditory and vestibular disorders. VZV is thought to become latent after primary varicella infection, and reactivation likely precipitates Ramsey Hunt Syndrome. Antiviral therapy is usually prescribed. Resp. Ex. C at 4; Resp. Ex. C, Tab 10.⁶⁵

Dr. Collins addressed Dr. Tuohy’s “hypothesis” that the FluMist caused inflammatory cytokines produced by both the adaptive and innate immune system to rapidly enter blood circulation through the mucosal blood vessels of the nasal sinuses. Due to the close anatomic proximity of the nose and ear, the potent cytokine gradient that developed affected nearby tissues and likely induced damage to nearby inner ear tissue, which is extremely sensitive to the effects of inflammatory cytokines. Resp. Ex. C at 5; Pet. Ex. 11 at 3. Dr. Tuohy relied on studies by *Vambutas* and *Pathak*, which discuss autoimmune inner ear disease (AIED) as responsive to steroids and other anti-inflammatory medication to show that the inner is especially sensitive to cytokines. Resp. Ex. C at 5; Pet. Ex. 21⁶⁶; Pet. Ex. 22⁶⁷; Pet. Ex. 23⁶⁸; Pet. Ex. 24.⁶⁹ Dr. Collins submits that these references are not relevant. AIED includes a sudden decline in hearing which petitioner did not have. *Id.* In addition, the IOM concluded there was no evidence found that directly or indirectly supports oversecretion of cytokines as an operative mechanism. *Id.*; Resp. Ex. C, Tab 11.⁷⁰

⁶² Scott A. Harper et al., *Using Live, Attenuated Influenza Vaccine for Prevention and Control of Influenza*, CENTERS FOR DISEASE CONTROL (Sept. 26, 2003), <https://www.cdc.gov/mmwr/preview/mmwrhtml/rr5213a1.htm>, filed as “Resp. Ex. C, Tab 8.”

⁶³ Robin S. Klein, *Clinical manifestations and diagnosis of herpes simplex virus type 1 infection*; UPTODATE (Aug. 5, 2017, 7:49 PM), <https://www.uptodate.com/>, filed as “Resp. Ex. C, Tab 9.”

⁶⁴ Varicella zoster virus, or human herpesvirus 3, is the etiologic agent of chickenpox and herpes zoster. *Dorland’s* 843. In comparison, HSV-1 is another name for human herpesvirus 1, which is the etiologic agent of herpes simplex. *Id.* 842.

⁶⁵ Mary A. Albrecht, *Clinical manifestations of varicella-zoster virus infection: Herpes zoster*, UPTODATE (Aug. 5, 2017, 9:23 PM), <https://www.uptodate.com/contents/epidemiology-clinical-manifestations-and-diagnosis-of-herpes-zoster>, filed as “Resp. Ex. C, Tab 10.”

⁶⁶ Andrea Vambutas et al., *Alternate Splicing of Interleukin-1 Receptor Type II (IL1R2) In Vitro Correlates with Clinical Glucocorticoid Responsiveness in Patients with AIED*, 4 PLOS ONE e5293 (2009), filed as “Pet. Ex. 21.”

⁶⁷ Pathak et al., *supra* note 16.

⁶⁸ Andrea Vambutas et al., *Early efficacy trial of anakinra in corticosteroid-resistant autoimmune inner ear disease*, 124 J. CLINICAL INVESTIGATION 4115 (2014), filed as “Pet. Ex. 23.”

⁶⁹ Shresh Pathak et al., *N-acetylcysteine attenuates tumor necrosis factor-alpha levels in autoimmune inner ear disease patients*, 63 IMMUNOLOGIC RES. 236 (2015), filed as “Pet. Ex. 24.”

⁷⁰ INST. OF MED., *ADVERSE EFFECTS OF VACCINES EVIDENCE AND CAUSALITY* (2012), filed as “Resp. Ex. C, Tab

Dr. Collins noted that while admitting that the effects of live attenuated influenza vaccine would be transient, Dr. Tuohy then submitted that petitioner's chronic symptoms were the result of epitope spreading or the substantial power of inflammatory cytokine surges that result from the activation of innate and adaptive memory responses to infection with live viruses. Resp. Ex. C at 5; Pet. Ex. 11, ref. 11,⁷¹ 12,⁷² 15,⁷³ 16.⁷⁴ Dr. Tuohy relied on *Rose* and *Lane*, which discuss coxsackie B virus infection causing inflammation to the muscle wall of the heart by inducing an autoimmune response in mice with a certain genetic background within 9-15 days after injection and could be reproduced by injecting mice with cardiac myosin protein. Resp. Ex. C at 5; Pet. Ex. 25⁷⁵; Pet. Ex. 26.⁷⁶ Dr. Collins submitted that this is dissimilar to petitioner, who received an attenuated vaccine and experienced symptoms within 2-3 days. Further, the *Rose* and *Lane* studies do not provide any evidence that the influenza vaccine could produce petitioner's vestibular symptoms. *Id.* (referencing Pet. Ex. 29-30).

Next, Dr. Collins discussed Dr. Tuohy's reliance on his own study which discussed epitope spreading in experimental autoimmune encephalomyelitis (EAE) and multiple sclerosis (MS). Resp. Ex. C at 6; Pet. Ex. 27.⁷⁷ *Tuohy* involved injecting myelin basic protein (MBP), which forms the sheath around the nerves, into mice to force an autoimmune reaction which then damages the myelin and causes neurological symptoms due to demyelination. Epitope spreading was supported by showing that injection of short myelin peptide led to immune responses directed against other sections of myelin protein within 2-3 weeks of injection and within 14 days of injection where there were already memory cells directed against peptides. Resp. Ex. C at 6. Dr. Collins submitted that the timing and characteristics of EAE are not similar to the vestibular symptoms experienced by petitioner within 2-3 days after the FluMist vaccine and provided no evidence that influenza could produce petitioner's vestibular symptoms.

Further, the *Miller* study relied on by Dr. Tuohy discussed epitope spreading in Theiler's virus infection of the central nervous system believed to be similar to MS. Resp. Ex. C at 6; Pet. Ex. 28.⁷⁸ The study viewed viral mediated damage to the myelin sheath and the development of an immune response to exposed myelin 30-35 days after infection. The study does not mention attenuated influenza vaccine or provide any evidence that influenza vaccine could produce petitioner's vestibular symptoms 2-3 days after vaccination. Resp. Ex. C at 6.

Dr. Collins agreed that coxsackie B virus and Theiler's virus persist in target organs, with Theiler's virus persisting for the lifetime of the infected host. Persistent infection leads to

11.”

⁷¹ Rose et al., *supra* note 40.

⁷² J.R. Lane et al., *Role of IL-1 and tumor necrosis factor in coxsackie virus-induced autoimmune myocarditis*, 151 J. IMMUNOLOGY 1682 (1993), filed as “Pet. Ex. 26.”

⁷³ Ami Schattner, *Consequence or coincidence? The occurrence, pathogenesis and significance of autoimmune manifestations after viral vaccines*, 23 VACCINE 3876 (2005), filed as “Pet. Ex. 29.”

⁷⁴ Hedi Orbach et al., *Vaccines and autoimmune diseases of the adult*, 9 DISCOVERY MED. 90-7 (2010), filed as “Pet. Ex. 30.”

⁷⁵ Rose et al., *supra* note 40.

⁷⁶ Lane et al., *supra* note 72.

⁷⁷ Vincent K. Tuohy et al., *The epitope spreading cascade during progression of experimental autoimmune encephalomyelitis and multiple sclerosis*, 164 IMMUNOLOGICAL REV. 93 (1998), filed as “Pet. Ex. 27.”

⁷⁸ Stephen D. Miller et al., *Virus-Induced Autoimmunity: Epitope Spreading to Myelin Epitopes in Theiler's Virus Infection of the Central Nervous System*, 56 ADVANCES IN VIRUS RESEARCH 199 (2001), filed as “Pet. Ex. 28.”

persistent damage and stimulation of the immune system. The FluMist does not persist in the body and is cleared by an anti-influenza immune response in humans with normal immune systems like petitioner. Resp Ex. C at 6.

Dr. Collins discussed *Schattner*, an article that conducted Medline searches of all relevant publications from 1966 to 2004 involving autoimmune reactions and vaccination relied on by Dr. Tuohy to describe specific organ damage, but none showed damage to the vestibular system. Resp. Ex. C at 6; Pet. Ex. 29.⁷⁹ Most showed symptoms developing after a latent period of about two weeks and were self-limited, reflective of the transient nature of the inflammatory response to vaccination. *Id.* Similarly, the *Orbach* study relied on by Dr. Tuohy was a review article on vaccines and autoimmune disease and did not include vaccine-induced vestibular disease similar to what petitioner suffered. Resp. C at 6; Pet. Ex. 30.⁸⁰

Dr. Collins addressed Dr. Hicks's "hypothesis" that, when combined with memory cells from prior influenza vaccine or viral infection, the FluMist overwhelmed and dismantled the balance between the level of attenuation and the level of immunogenicity, causing onset of symptoms within a few days. Resp. Ex. C at 6. According to Dr. Hicks, the reference relied on states that onset of antigenic immunoblasts may take 3 days or more but a secondary response by memory lymphocytes has a shorter lag time.⁸¹ *Id.*

Dr. Collins discussed Dr. Hicks's opinion that viruses, including influenza, can damage the inner ear. Reviewing Dr. Hicks's references 24-35 (Pet. Ex. 40-50), Dr. Collins noted that none of these articles provide "evidence that vaccination with live attenuated influenza virus could cause [petitioner's] symptoms." Resp. Ex. C at 7. *Davis* involved wild influenza virus which infected inner ear structures of newborn hamsters when injected directly into the brain, but not when injected elsewhere. *Id.*; Pet. Ex. 40.⁸² A second study by *Davis* discussed infection of inner ear structures from various viruses including HSV in guinea pigs and wild type influenza virus in ferrets but concluded "firm proof" was lacking in humans. Resp. Ex. C at 7; Pet. Ex. 41.⁸³ *Matsuo* discussed increased protein in cerebral spinal fluid, "which bathes the central nervous system" in those with vestibular neuritis and provides nothing relevant to this case. *Id.* at 7; Pet. Ex. 42.⁸⁴ *Richard* discussed a woman who had two episodes of vertigo during her life with complete recovery after each who had a smaller ganglion in the right superior vestibular nerve. This has no relevance to Dr. Hick's theory in this case. *Id.* at 7; Pet. Ex. 43.⁸⁵

Richard, *Rarey*, and *Arbusow* were studies that tested for HSV DNA in vestibular tissue dissected randomly on autopsy, showing it to be commonly found in vestibular tissue. The studies did not discuss whether HSV DNA caused vestibular neuritis but found the frequency at

⁷⁹ *Schattner*, *supra* note 73.

⁸⁰ *Orbach et al.*, *supra* note 74.

⁸¹ This reference relied upon by Dr. Hicks was not filed.

⁸² Larry E. Davis & Richard T. Johnson, *Experimental Viral Infections of the Inner Ear, I. Acute Infections of the Newborn Hamster Labyrinth*, 34 LAB. INVESTIGATION 349 (1976), filed as "Pet. Ex. 40."

⁸³ Larry E. Davis, *Comparative Experimental Viral Labyrinthitis*, 11 AM. J. OTOLARYNGOLOGY 382 (1990), filed as "Pet. Ex. 41."

⁸⁴ Takaaki Matsuo, *Vestibular Neuronitis—Serum and CSF Virus Antibody Titer*, 13 AURIS NASUS LARYNX 11 (1986), filed as "Pet. Ex. 42."

⁸⁵ *Richard & Linthicum*, *supra* note 51.

which HSV DNA was present in vestibular tissue was higher than the frequency of vestibular neuritis. Resp. Ex. C at 7; Pet. Ex. 43⁸⁶; Pet. Ex. 44⁸⁷; Pet. Ex. 45⁸⁸; Pet. Ex. 46.⁸⁹ Dr. Collins added that studies show HSV infection is successfully treated with anti-viral medication such as acyclovir or Valacyclovir, which has no benefit in treating those with vestibular neuritis. Resp. Ex. C at 7. Resp. Ex. C, Tab 1. *Welling*⁹⁰ showed no HSV DNA detected on surgical specimens from patients with vertigo due to Meniere's disease. *Id.* *Rarey* involved ferrets infected with wild influenza B and given aspirin and an arginine-deficient diet who developed histological changes but showed no inflammation in the vestibular system. Resp. Ex. C at 7-8. *Ishiyama* examined the temporal bone of three people with chronic recurrent vestibular neuritis and inflammation, even when not suffering from vertigo at the time of death, leading to speculation that post-viral infection was a possible cause of the inflammation. Resp. Ex. C at 8; Pet. Ex. 50.⁹¹ The authors referenced one case of vestibular neuritis after influenza vaccine. Dr. Collins noted that the IOM cautions that, while useful in describing concerns and for the generation of hypotheses, case reports generally have uncorroborated data and are insufficient for causality. Resp. Ex. C at 8. Dr. Collins concluded that the references relied on do not provide support for Dr. Hick's theory that live attenuated influenza vaccination caused petitioner's vestibular problems.

Dr. Collins then addressed Dr. Hicks's theory that reactivated HSV can cause Bell's palsy, idiopathic sensorineural hearing loss, and vestibular neuritis, commenting on the literature he relied on. Resp. Ex. C at 8 (citing Pet. Ex. 13, ref. 36-37). *Veltri* studied the serology or the presence of a virus by measuring detection of immune response against the virus, including wild type influenza virus in cases in which sensorineural hearing loss occurred. In Dr. Collins's opinion, the article is irrelevant because petitioner did not have hearing loss. Resp. Ex. C at 8; Pet. Ex. 51.⁹² *Falser* studied pseudorabies virus found in the vestibular system of mice and swine causing damage also not relevant to petitioner. Resp. Ex. C at 8; Pet. Ex. 52.⁹³

Dr. Collins addressed Dr. Hicks's reliance on his references 38-47 in support of his opinion that the superior vestibular nerve is more susceptible to inflammatory effects than the inferior vestibular nerve, comparing it to the facial nerve affected in Bell's palsy. According to Dr. Collins, these references are not relevant to whether the FluMist caused petitioner's chronic vestibular symptoms. Resp. Ex. C at 8 (referencing Pet. Ex. 53;⁹⁴ Pet. Ex. 54;⁹⁵ Pet. Ex. 55;⁹⁶ Pet. Ex. 56;⁹⁷ Pet. Ex. 57;⁹⁸ Pet. Ex. 58;⁹⁹ Pet. Ex. 59;¹⁰⁰ Pet. Ex. 60;¹⁰¹ Pet. Ex. 61;¹⁰² Pet. Ex. 62¹⁰³).

⁸⁶ *Id.*

⁸⁷ Viktor Arbusow et al., *HSV-1 Not Only in Human Vestibular Ganglia but Also in the Vestibular Labyrinth*, 6 *AUDIOLOGY & NEUROLOGY* 259 (2001), filed as "Pet. Ex. 44."

⁸⁸ Rarey et al., *supra* note 44.

⁸⁹ V. Arbusow et al., *Distribution of Herpes Simplex Virus Type 1 in Human Geniculate and Vestibular Ganglia: Implications for Vestibular Neuritis*, 38 *AM. NEUROLOGICAL ASS'N* 416 (1999), filed as "Pet. Ex. 46."

⁹⁰ D. Bradley Welling et al., *Detection of Viral DNA in Vestibular Ganglia Tissue From Patients With Meniere's Disease*, 18 *AM. J. OTOLOGY* 734 (1997), filed as "Pet. Ex. 49."

⁹¹ Akira Ishiyama et al., *Histopathology of Idiopathic Chronic Recurrent Vertigo*, 106 *LARYNGOSCOPE* 1340 (1996), filed as "Pet. Ex. 50."

⁹² Robert W. Veltri et al., *The Implication of Viruses in Idiopathic Sudden Hearing Loss: Primary Infection or Reactivation of Latent Viruses?*, 89 *OTOLARYNGOLOGY HEAD NECK SURGERY* 137 (1981), filed as "Pet. Ex. 51."

⁹³ N. Falser et al., *The Role of Acute and Latent Virus Infections in the Pathogenesis of Inner Ear Disturbances*, 8 *AM. J. OTOLOGY* 136 (1987), filed as "Pet. Ex. 52."

⁹⁴ H.J. Milionis et al., *Lipoprotein (a) and acute-phase response in patients with vestibular neuritis*, 33 *EUR. J. CLINICAL INVESTIGATION* 1045 (2003), filed as "Pet. Ex. 53."

Dr. Collins summarized Dr. Hicks's hypotheses as, one, the FluMist vaccination resulted in fulminate influenza virus infection, which compromised the immune system and caused reactivation of HSV-1 causing vestibular injury and/or two, the FluMist vaccine induced an immune response causing a "stress response" that reactivated HSV-1 and caused vestibular injury. Resp. Ex. C at 8.

Dr. Collins pointed out that petitioner's medical records do not contain any reports that petitioner suffered from a fulminant influenza infection which includes fever, chills, headache, and congestion. Dr. Collins agreed that HSV DNA in vestibular tissue has been shown on autopsy slides, but whether HSV-1 causes vestibular neuritis is controversial. Antivirals that should be effective against HSV-1 are ineffective in those suffering from vestibular neuritis and vaccination has not been shown to induce HSV-1 reactivation. Resp. Ex. C at 9.

Dr. Collins discussed Ramsey Hunt Syndrome well recognized as caused by reactivation of latent varicella zoster virus (VZV) in the geniculate ganglion. Resp. Ex. C at 9; Resp. Ex. C, Tabs 1¹⁰⁴ and 3.¹⁰⁵ Ramsey Hunt Syndrome includes acute vertigo and/or hearing loss, facial paralysis, ear pain, and vesicles in the auditory canal and auricle. Petitioner did not have symptoms of Ramsey Hunt Syndrome and there is no evidence that vaccines can reactivate latent VZV. Resp. Ex. C at 9.

As to timing, Dr. Collins submitted that autoimmune response to self-proteins following virological damage to tissue takes two weeks for symptoms to develop, not 2-3 days. Resp. Ex. C at 9.

Dr. Collins submitted that Drs. Tuohy and Hicks's theories are inconsistent with findings of large-scale studies on FluMist, which have shown the adverse effects of pneumonia, bronchitis, bronchiolitis, or central nervous system events were similar in recipients of the vaccine and of the placebo. Resp. Ex. C at 9; Resp. Ex. C, Tab 8.¹⁰⁶

⁹⁵ S.T. Aw et al., *Individual semicircular canal function in superior and inferior vestibular neuritis*, 57 NEUROLOGY 768 (2001), filed as "Pet. Ex. 54."

⁹⁶ Ji-Soo Kim & Hyo Jung Kim, *Inferior vestibular neuritis*, 259 J. NEUROLOGY 1553 (2012), filed as "Pet. Ex. 55."

⁹⁷ Stefan S. Kassner et al., *Proinflammatory Activation of Peripheral Blood Mononuclear Cells in Patients with Vestibular Neuritis*, 16 AUDIOLOGY & NEUROLOGY 242 (2011), filed as "Pet. Ex. 56."

⁹⁸ Sherrie Divito et al., *A Triple Entente: Virus, Neurons, and CD8⁺ T Cells Maintain HSV-1 Latency*, 36 IMMUNOLOGIC RES. 119 (2006), filed as "Pet. Ex. 57."

⁹⁹ Richard J. Whitley, *Herpes Simplex Virus Infections of the Central Nervous System*, 85 AM. J. MED. 61 (1988), filed as "Pet. Ex. 58."

¹⁰⁰ Lawrence T. Feldman, *Spontaneous molecular reactivation of herpes simplex virus type 1 latency in mice*, 99 PNAS 978 (2002), filed as "Pet. Ex. 59."

¹⁰¹ Joel A. Goebel et al., *Anatomic Considerations in Vestibular Neuritis*, 22 OTOLGY & NEUROLOGY 512 (2001), filed as "Pet. Ex. 60."

¹⁰² G.M. Halmagyi et al., *Inferior Vestibular Neuritis*, 956 ANN. N.Y. ACAD. SCI. 306 (2002), filed as "Pet. Ex. 61."

¹⁰³ Takaaki Matsuo & Toru Sekitani, *Vestibular Neuritis: Neurotological Findings and Progress*, 47 ORL 199 (1985), filed as "Pet. Ex. 62."

¹⁰⁴ Baloh, *supra* note 9.

¹⁰⁵ Joseph M. Furman, *Causes of vertigo*, UPTODATE (July 29, 2017, 11:33 AM), <https://www.uptodate.com/contents/causes-of-vertigo>, filed as "Resp. Ex. C, Tab 3."

¹⁰⁶ Harper et al., *supra* note 62.

Dr. Collins submitted vestibular migraine as an alternative explanation for petitioner's condition based on his personal and family history of migraine headaches, prior history of vertigo, and response to medication effective in treating migraines. Further, Drs. Khemani and Bronstein opined that petitioner had underlying migraine, though unclear whether he suffered pure migraines or had an episode of inferior vestibular nerve neuritis with delayed compensation secondary to migraine. Resp. Ex. C at 9.

Dr. Collins concluded that the onset of petitioner's symptoms following receipt of the FluMist vaccination was too rapid to be autoimmune mediated, his chronic symptoms inconsistent with the mechanisms proposed, and there is no evidence that FluMist can cause vestibular neuritis, reactivate HSV-1, or that reactivation of HSV is an indirect cause of vestibular neuritis. Therefore, there is no support for the FluMist causing petitioner's chronic symptoms. Resp. Ex. C at 9-10.

iii. Dr. Collins' Second Report

In her second report, Dr. Collins addressed Drs. Tuohy and Hicks's responses to her initial report. Resp. Ex. E.

In response to Dr. Tuohy, Dr. Collins pointed to petitioner's multiple URIs and related complaints in 2006 that were similar to what he suffered in October 2013, concluding that however one chooses to describe the symptoms, petitioner had a predisposition to vertigo. Resp. Ex. E at 1.

Dr. Collins clarified, she did not raise AIED, Dr. Tuohy did with his reliance on references 7-10 submitted to show that inner ear tissue is sensitive to cytokines and AIED is responsive to steroids and anti-inflammatory mediators. Resp. Ex. E at 1; Pet. Ex. 21;¹⁰⁷ Pet. Ex. 22;¹⁰⁸ Pet. Ex. 23;¹⁰⁹ Pet. Ex. 24.¹¹⁰ Dr. Collins agreed with Dr. Hicks that AIED and vestibular neuritis are different in their effect on hearing, and that petitioner did not have symptoms of AIED, which includes a sudden decline in hearing. Petitioner had intermittent vertigo and dizziness. Resp. Ex. at 1-2.

Despite petitioner's experts' assertions to the contrary, Dr. Collins pointed to petitioner's medical records that documented a personal and family history of migraines, and a prior history of vertigo and vestibular symptoms. These entries were not marked as "in error" as suggested. Resp. Ex. E at 2; Pet. Ex. 4 at 25, 53, 78; Pet. Ex. 8 at 7, 11. Further, she highlighted Dr. Bronstein's record that documented petitioner's report of a 60-70% improvement in migraines with medication, specifically amitriptyline with all objective testing being normal. Resp. Ex. E at 2; Pet. Ex. 3 at 3; Pet. Ex. 8 at 7. Further, Dr. Bronstein's conclusion that petitioner's symptoms appeared to be related to underlying migraines, whether pure migraine or an episode of inferior vestibular nerve neuritis with delayed compensation secondary to migraine, is supported by petitioner's history. Resp. Ex. E at 2; Pet. Ex. 8 at 14. Relying on the Harvard

¹⁰⁷ Vambutas et al., *supra* note 66.

¹⁰⁸ Pathak et al., *supra* note 16.

¹⁰⁹ Vambutas et al., *supra* note 68.

¹¹⁰ Pathak et al., *supra* note 69.

Medical School online textbook UpToDate, Dr. Collins submitted that patients with vestibular migraine do not have other neurological symptoms and may not have headaches with their attacks of vertigo. Resp. Ex. E at 2; Resp. Ex. C, Tab 5.¹¹¹ Even though petitioner did not describe his past headaches as migraines, he reported sinus headaches that sometimes occurred over one eye. Resp. Ex. E at 2; Pet. Ex. 4 at 123.

Dr. Collins addressed Dr. Tuohy's hypotheses including that: the FluMist caused inflammation and oversecretion of cytokines into local, collateral, and systemic circulation irritating the delicate tissue of the inner ear; an immune response to cochlear-specific protein could cause damage to the cochlea with hearing loss similar to that seen in autoimmune sensorineural hearing loss; and post-viral autoimmune induced tissue damage could chronically affect the labyrinth following vaccination relying on an entry in the record by Dr. Brookes that "clinically, this fits best with a post-viral damage." Resp. Ex. E at 2-3. Dr. Collins agreed that the initial presentation may have fit post-viral damage due to URI but post-viral damage due to a URI should be transient, so the theory falls apart due to the chronicity of petitioner's symptoms. Petitioner's vestibular testing was normal with no evidence of viral damage. Resp. Ex. E at 3; Pet. Ex. 9 at 13.

Dr. Collins added that Dr. Tuohy's theory is further flawed because it invokes both elements of a weak immune response suggesting the persistence of an uncleared virus and an overly strong immune response invoking autoimmunity to explain petitioner's chronic symptoms. However, he provided no evidence to support that influenza virus can cause persistent infection with chronic symptoms and, in fact, acknowledged that live attenuated influenza virus vaccination would be transient and would not explain chronic symptoms. Resp. Ex. E at 3. The overly strong immune system response is problematic in that autoimmune responses against cochlear proteins would result in cochlea damage and hearing loss, which petitioner does not have. *Id.* at 4.

As for Dr. Hicks's theory that FluMist was a stressor that reactivated HSV-1 latent in the geniculate and vestibular ganglion, leading to an inflammatory response of the superior vestibular nerve, is also flawed. Dr. Hicks relied on his references 6, 8, 28, 29, 31, 32, 33, 36, 37, 42, 43, 44, 52, 57, and 58¹¹² to show the presence of HSV-1 in animals and in the temporal bone on autopsy in humans and included epidemiology studies that show the presence of latent HSV-1 in the trigeminal, genicular, and vestibular ganglions, either individually or collectively. Pet. Ex. 32;¹¹³ Pet. Ex. 33;¹¹⁴ Pet. Ex. 43;¹¹⁵ Pet. Ex. 44;¹¹⁶ Pet. Ex. 46;¹¹⁷ Pet. Ex. 47;¹¹⁸ Pet. Ex. 48;¹¹⁹

¹¹¹ Robertson, *supra* note 14.

¹¹² Dr. Hick's references 52, 57, and 58 were not filed.

¹¹³ Baloh, *supra* note 9.

¹¹⁴ Arbusow, *supra* note 59.

¹¹⁵ Richard & Linthicum, *supra* note 51.

¹¹⁶ Arbusow et al., *supra* note 87.

¹¹⁷ Arbusow et al., *supra* note 89.

¹¹⁸ Martha F. Kramer et al., *Latent Herpes Simplex Virus Infection of Sensory Neurons Alters Neuronal Gene Expression*, 77 J. VIROLOGY 9533 (2003), filed as "Pet. Ex. 47."

¹¹⁹ Yasushi Furuta et al., *Latent Herpes Simplex Virus Type 1 in Human Vestibular Ganglia*, 503 ACTA OTOLARYNGOLICA SUPP. 85 (1993), filed as "Pet. Ex. 48."

Pet. Ex. 51;¹²⁰ Pet. Ex. 52;¹²¹ Pet. Ex. 57;¹²² Pet. Ex. 58;¹²³ Pet. Ex. 59.¹²⁴ However, while Dr. Collins agreed that indirect evidence exists that HSV-1 has been found in the ganglion on autopsy slides from normal people, there is no proof that HSV-1 infection can cause vestibular neuritis. Further, antivirals used to treat to HSV-1 infection are not beneficial to those suffering from vestibular neuritis, suggesting that HSV-1 infection does not cause vestibular neuritis. Resp. Ex. E at 4; Resp. Ex. C, Tab 1;¹²⁵ Pet. Ex. 13.

Dr. Collins agreed it is generally accepted that VZV (herpes zoster virus),¹²⁶ which is different from HSV-1, can play a role in causing Bell's palsy and infection of the 7th and 8th cranial nerves. However, petitioner did not have symptoms of herpes zoster infection and Dr. Hicks's reliance on herpes zoster and Bell's palsy does not translate to HSV-1 causing vestibular neuritis. Resp. Ex. E at 4.

Dr. Collins repeated what was contained in her first report regarding Dr. Hicks's opinions and literature. Resp. Ex. E at 4-7. She added that the model Dr. Hicks proposes is inconsistent and flawed in explaining how a virus can be active to cause to disease yet latent for drugs to be ineffective. Antiviral medications treat reactivated HSV-1 and prevent further reactivation. The ineffectiveness of antiviral medication in the treatment of vestibular neuritis argues against the role of HSV-1, and Dr. Hicks provides no evidence that vaccines can cause reactivation of HSV-1. Resp. Ex. E at 7.

Dr. Collins concluded that Dr. Tuohy's logic is similarly flawed because his autoimmune theories would lead to hearing loss, which petitioner did not have as noted by Dr. Hicks. Resp. Ex. E at 7. Both Drs. Tuohy and Hicks agree that persistence of a live virus is not a viable option in an immunocompetent person like petitioner. Thus, her conclusions in this case remained the same. *Id.*

V. Discussion

A. Legal Standard

The Vaccine Act provides two avenues for petitioners to receive compensation. First, a petitioner may demonstrate a "Table" injury—i.e., an injury listed on the Vaccine Injury Table that occurred within the provided time period. 42 U.S.C. § 300aa-11(c)(1)(C)(i). "In such a case, causation is presumed." *Capizzano v. Sec'y of Health & Human Servs.*, 440 F.3d 1317, 1320 (Fed. Cir. 2006); *see* § 13(a)(1)(B). Second, where the alleged injury is not listed on the Vaccine Injury Table, a petitioner may demonstrate an "off-Table" injury, which requires that the petitioner "prove by a preponderance of the evidence that the vaccine at issue caused the injury." *Capizzano*, 440 F.3d at 1320; *see* § 11(c)(1)(C)(ii). A petitioner need not show that the vaccination was the sole cause, or even the predominant cause, of the alleged injury; showing

¹²⁰ Veltri et al., *supra* note 92.

¹²¹ Falser et al., *supra* note 93.

¹²² Divito et al., *supra* note 98.

¹²³ Whitley, *supra* note 99.

¹²⁴ Feldman et al., *supra* note 100.

¹²⁵ Baloh, *supra* note 9.

¹²⁶ Herpes zoster virus is also called varicella zoster virus (VZV). Resp. Ex. C at 9.

that the vaccination was a “substantial factor” and a “but for” cause of the injury is sufficient for recovery. *Pafford v. Sec’y of Health & Human Servs.*, 451 F.3d 1352, 1355 (Fed. Cir. 2006); *Shyface v. Sec’y of Health & Human Servs.*, 165 F.3d 1344, 1352 (Fed. Cir. 1999). Petitioners are not required “to eliminate alternative causes as part of establishing [their] prima facie case.” *Doe v. Sec’y of Health & Human Servs.*, 601 F.3d 1349, 1357-58 (Fed. Cir. 2010); see *Walther v. Sec’y of Health & Human Servs.*, 485 F.3d 1146, 1152 (Fed. Cir. 2007) (holding that a “petitioner does not bear the burden of eliminating alternative independent potential causes”). Once a petitioner has proven causation by preponderant evidence, “the burden then shifts to the respondent to show by a preponderance of the evidence that the injury is due to factors unrelated to the administration of the vaccine.” *Deribeaux ex rel. Deribeaux v. Sec’y of Health & Human Servs.*, 717 F.3d 1363, 1367 (Fed. Cir. 2013) (citing 42 U.S.C. § 300aa-13(a)(1)(B)).

To prove causation, petitioners must satisfy the three-pronged test established in *Althen v. Sec’y of Health & Human Servs.*, 418 F.3d 1274 (Fed. Cir. 2005). *Althen* requires that petitioners show by preponderant evidence that a vaccination petitioner received caused his or her injury “by providing: (1) a medical theory causally connecting the vaccination and the injury; (2) a logical sequence of cause and effect showing that the vaccination was the reason for the injury; and (3) a showing of a proximate temporal relationship between vaccination and injury.” *Id.* at 1278. Together, these prongs must show “that the vaccine was ‘not only a but-for cause of the injury but also a substantial factor in bringing about the injury.’” *Stone v. Sec’y of Health & Human Servs.*, 676 F.3d 1373, 1379 (Fed. Cir. 2012) (quoting *Shyface*, 165 F.3d at 1352-53). Causation is determined on a case-by-case basis, with “no hard and fast per se scientific or medical rules.” *Knudsen v. Sec’y of Health & Human Servs.*, 35 F.3d 543, 548 (Fed. Cir. 1994). Petitioners are not required to identify “specific biological mechanisms” to establish causation, nor are they required to present “epidemiologic studies, rechallenge, the presence of pathological markers or genetic disposition, or general acceptance in the scientific or medical communities.” *Capizzano*, 440 F.3d at 1325 (quoting *Althen*, 418 F.3d at 1280). “[C]lose calls regarding causation are resolved in favor of injured claimants.” *Althen*, 418 F.3d at 1280.

Each *Althen* prong requires a different showing. Under the first prong, petitioner must provide a “reputable medical theory” demonstrating that the vaccine received can cause the type of injury alleged. *Pafford*, 451 F.3d at 1355-56 (citation omitted). To satisfy this prong, petitioner’s “theory of causation must be supported by a ‘reputable medical or scientific explanation.’” *Andreu*, 569 F.3d at 1379 (quoting *Althen*, 418 F.3d at 1278). This theory need only be “legally probable, not medically or scientifically certain.” *Id.* at 1380 (emphasis omitted) (quoting *Knudsen*, 35 F.3d at 548). Nevertheless, “petitioners [must] proffer trustworthy testimony from experts who can find support for their theories in medical literature.” *LaLonde*, 746 F.3d at 1341.

The second *Althen* prong requires proof of a “logical sequence of cause and effect.” *Capizzano*, 440 F.3d at 1326 (quoting *Althen*, 418 F.3d at 1278). Even if the vaccination can cause the injury, petitioner must show “that it did so in [this] particular case.” *Hodges v. Sec’y of Health & Human Servs.*, 9 F.3d 958, 962 n.4 (Fed. Cir. 1993) (citation omitted). “A reputable medical or scientific explanation must support this logical sequence of cause and effect,” *Id.* at 961 (citation omitted), and “treating physicians are likely to be in the best position to determine whether a logical sequence of cause and effect show[s] that the vaccination was the reason for

the injury,” *Paluck v. Sec’y of Health & Human Servs.*, 786 F.3d 1373, 1385 (Fed. Cir. 2015) (quoting *Andreu*, 569 F.3d at 1375).

The third *Althen* prong requires that petitioner establish a “proximate temporal relationship” between the vaccination and the alleged injury. *Althen*, 418 F.3d at 1281. This “requires preponderant proof that the onset of symptoms occurred within a timeframe for which, given the medical understanding of the disorder’s etiology, it is medically acceptable to infer causation-in-fact.” *De Bazan v. Sec’y of Health & Human Servs.*, 539 F.3d 1347, 1352 (Fed. Cir. 2008). Typically, “a petitioner’s failure to satisfy the proximate temporal relationship prong is due to the fact that onset was too late after the administration of a vaccine for the vaccine to be the cause.” *Id.* However, “cases in which onset is too soon” also fail this prong; “in either case, the temporal relationship is not such that it is medically acceptable to conclude that the vaccination and the injury are causally linked.” *Id.*; see also *Locane v. Sec’y of Health & Human Servs.*, 685 F.3d 1375, 1381 (Fed. Cir. 2012) (“[If] the illness was present before the vaccine was administered, logically, the vaccine could not have caused the illness.”).

Finally, although this decision discusses some but not all the literature in detail, I have reviewed and considered all of the medical records and literature submitted in this matter. See *Moriarty ex rel. Moriarty v. Sec’y of Health & Human Servs.*, 844 F.3d 1322, 1328 (Fed. Cir. 2016) (“We generally presume that a special master considered the relevant record evidence even though [s]he does not explicitly reference such evidence in h[er] decision.”); *Simanski v. Sec’y of Health & Human Servs.*, 115 Fed. Cl. 407, 436 (2014) (“[A] Special Master is ‘not required to discuss every piece of evidence or testimony in her decision.’” (citation omitted)), *aff’d*, 601 F. App’x 982 (Fed. Cir. 2015).

B. Analysis of *Althen* Factors

Because petitioner does not allege an injury listed on the Vaccine Injury Table, his claim is classified as “off-Table.” As noted above, for petitioner to prevail on an “off-Table” claim, he must show by preponderant evidence that his claimed injury resulted from the vaccination at issue. *Capizzano*, 440 F.3d at 1320. Doing so shifts the burden to respondent to show that the injury was caused by factors unrelated to the vaccination. *Deribeaux*, 717 F.3d at 1367.

1. The Record Does Not Support a Diagnosis of Vestibular Neuritis

As a threshold matter, petitioner must first establish that he suffered the injury alleged in the petition. See *Broekelschen v. HHS*, 618 F.3d 1339,1346 (Fed. Cir. 2010). As the Federal Circuit has made clear, “the statute places the burden on petitioner to make a showing of at least one defined and recognized injury.” *Lombardi v. HHS*, 656 F.3d 1343,1353 (Fed. Cir. 2011) (affirming a special master’s decision to dismiss a petition when the petitioner could not establish that she had any of the three diagnoses alleged). “The function of a special master is not to ‘diagnose’ vaccine-related injuries, but instead to determine based on the record evidence as a whole and the totality of the case, whether it has been shown by a preponderance of the evidence that a vaccine caused [petitioner’s] injury.” *Lombardi*, 656 F.3d at 1352-53 (internal citation omitted). Thus, where “the existence and nature of the injury itself is in dispute, it is the special master’s duty to *first determine* which injury is best supported” by the evidence before applying

the *Althen* test to determine causation. *Id.* at 1352 (citing *Broekelschen*, 618 F.3d at 1345) (emphasis added).

The parties dispute petitioner's proper diagnosis in this matter. In the petition, petitioner alleged that an influenza vaccine received on October 17, 2013 caused him to suffer a "severe adverse reaction." Pet. at ¶1. Thereafter, petitioner argued that he suffers from vestibular neuritis, as opined by his expert Dr. Hicks. Respondent argued that petitioner suffers from vestibular migraines/migrainous vertigo ("vestibular migraines"). Mot. for Ruling on the Record at 17, ECF No. 65; Resp. Ex. A at 21; Resp. Ex. C at 9.

Several diagnoses were considered by petitioner's treating physicians over the course of his treatment. When petitioner presented in October 2013 following his October 17, 2013 flu vaccine, possible viral labyrinthitis was suggested. Labyrinthitis was again mentioned on November 1, 2013. Pet. Ex. 4 at 23. Three months later, at his next medical visit on February 11, 2014, when petitioner presented to his PCP seeking clearance to fly, his history included resolved labyrinthitis. At that visit, petitioner reported being symptom free since December 2013. *Id.* at 24.

On April 30, 2014, petitioner presented to Dr. Brooks reporting an upper respiratory infection in February 2014 with chronic symptoms of vertigo since. Following an MRI and vestibular testing, Dr. Brookes opined that petitioner's symptoms clinically fit best with "post-viral damage and decompensation" following an upper respiratory infection in February 2014. Pet. Ex. 7 at 1; Pet. Ex. 4 at 111. On May 9, 2014, Dr. Khemani opined that petitioner had an episode of viral neuronitis from which he recovered fully but has had episodes of decompensation likely triggered by proprioceptive cause, particularly cervicogenic in nature. Pet. Ex. 8 at 51. In November 2014, following additional vestibular testing, Dr. Low concluded that petitioner had vestibular migraines. Pet. Ex. 5 at 6. Petitioner then saw Dr. Bronstein, who provided two possible interpretations: *inferior* nerve vestibular neuritis¹²⁷ (emphasis added) with residual symptoms perhaps not fully compensated due to migraine, or migraine with vestibular flavor. Pet. Ex. 4 at 124. On February 9, 2015, Dr. Khemani concluded the diagnosis was probable vestibular migraines. Pet. Ex. 8 at 14.

Various diagnoses were considered, but following extensive testing, vestibular migraines with cervical contribution was the most agreed upon diagnosis by petitioner's treating physicians and what petitioner's treating physicians treated him for. Respondent's experts, unlike petitioner's treating physicians, had the benefit of petitioner's history of prior episodes of vertigo and agreed that petitioner suffered from vestibular migraines. However, petitioner and his expert, Dr. Hicks, maintain that petitioner suffers from vestibular neuritis. The literature filed provides that the diagnosis for both vestibular neuritis and vestibular migraine is based largely on clinical presentation with no specific diagnostic testing as confirmatory. *See* Resp. Ex. C, Tab 2¹²⁸; Resp. Ex. C, Tab 5.¹²⁹ Thus, to be thorough, I must look at the opinions of the experts in this case and the evidence upon which they based their opinions.

¹²⁷ Dr. Bronstein's record noted that "inferior nerve vestibular neuritis is much more rare than the usual superior nerve type." Pet. Ex. 4 at 124.

¹²⁸ Furman, *supra* note 10, at 3.

¹²⁹ Robertson, *supra* note 14, at 6.

Dr. Tuohy does not provide a diagnosis for petitioner beyond an assertion that petitioner developed persistent inner ear inflammation as a result of an autoimmune inner ear disease as the “more reasonable” cause of petitioner’s chronic symptoms. Pet. Ex. 11 at 2, 4. Dr. Hicks, Dr. Bigelow, and Dr. Collins agree petitioner does not have AIED. *See* Pet. Ex. 69 at 1; Resp. Ex. A at 16; Resp. Ex. C at 5.

Dr. Hicks described and concluded that petitioner suffers from vestibular neuritis. Pet. Ex. 13 at 5; Pet. Ex. 69 at 1; Pet. Ex. 75 at 1. He argued that petitioner’s primary care physician misdiagnosed him with labyrinthitis, which has the same symptoms as vestibular neuritis but includes hearing loss, which petitioner did not have. Pet. Ex. 75 at 4; *see* Pet. Ex. 69 at 1. Dr. Hicks further argued that petitioner’s normal vestibular test results were unreliable. Pet. Ex. 75 at 2. To that end, he quoted Dr. Bronstein’s February 2015 letter in which he was “a little suspicious” about the findings of the cVEMP test because it was a new test and he lacked confidence in his own ability to interpret the six canal vHIT test. *Id.* at 2-3. Dr. Hicks suggested that the other ordered testing, including oVEMP or posturography testing, could have identified vestibular deficiency and malingering, but were not performed. *Id.* at 2.

Dr. Hicks disregarded the portion of Dr. Bronstein’s February 2015 letter in which he concluded that migraines were a contributory factor and “definitely in the cards.” Dr. Bronstein provided “two parallel possible interpretations”: inferior nerve vestibular neuritis¹³⁰ with residual symptoms perhaps not fully compensated due to migraine, or migraine with vestibular flavor. Both interpretations include vestibular migraine. Pet. Ex. 4 at 124. Dr. Bronstein prescribed Amitriptyline used to treat migraines and specific exercises for visuo-vestibular compensation in the vertical plane. *Id.*

Dr. Hicks submitted that vestibular neuritis “is a clinical condition with a clinical solution”, which requires thorough understanding of anatomy, physiology, pathophysiology, and inner ear disorders and their differences. He has “treated thousands of patients with vestibular disorders, including vestibular neuritis and how it differs from other inner ears disorders such as labyrinthitis.” Dr. Hicks claimed the migraine medication prescribed to petitioner was ineffective. Thus, vestibular neuritis is the more likely diagnosis based on his theory of HSV-1 reactivation. Pet. Ex. 69 at 6. Dr. Hicks wrote: “intranasal LAV vaccination > systemic spread > stress response” > reactivation of latent HSV-1 from geniculate ganglion and vestibular ganglion > inner ear inflammatory response of superior vestibular nerve > acute vestibular symptoms – vertigo, nausea, vomiting > acute treatment, none (no steroids provided) > delayed treatment, vestibular suppressants for one month > failure of naturally occurring vestibular compensation > chronic vestibular symptoms > lose job.” Pet. Ex. 69 at 6.

Drs. Bigelow and Collins opined that petitioner suffers from vestibular migraines, agreeing with petitioner’s treaters, Drs. Low, Bronstein, and Khemani. Resp. Ex. A at 21; Resp. Ex. C at 9. Drs. Bigelow and Collins relied on petitioner’s full medical records, vestibular testing, personal history of vertigo and migraine, family history of migraine, and the nature and course of petitioner’s symptoms.

¹³⁰ Dr. Bronstein’s record noted that “inferior nerve vestibular neuritis is much more rare than the usual superior nerve type.” Pet. Ex. 4 at 124.

Drs. Tuohy and Hicks and petitioner dispute the accuracy of petitioner's documented medical history. Dr. Tuohy claims that it is "untenable" that respondent's experts embraced the diagnosis of migrainous vertigo as suggested by petitioner's treaters because petitioner "has no migraine history in his medical records." Pet. Ex. 68 at 1. However, petitioner's records document a history of vertigo in the years prior to the alleged vaccination for which petitioner sought the care of Dr. Warrington. He also has a family history of migraine from his mother. Pet. Ex. 4 at 53; Pet. Ex. 3 at 1. Though petitioner denied having vertigo and migraines at his visit with Dr. Bronstein on February 9, 2015, he provided a history of sinus-related headaches behind his eyes, sometimes of only one orbit. *Id.* Petitioner's medical records include past complaints similar to those reported in October 2013 and again in April 2014 following an upper respiratory infection in February 2014. In 2006, petitioner reported three episodes of vertigo described as "a sensation of spinning associated with nausea and it happens on moving", without hearing loss, tinnitus, or other notable symptoms. Pet. Ex. 4 at 78. On December 20, 2011, petitioner presented to his PCP for "several issues," reporting that he "had flu jab, then had uris sxs, back and forth from sinuses to chest and back, pounding HAs on descent, pain behind eyes..." Pet. Ex. 4 at 21. He returned to the doctor on December 28, 2011. "...still having sinus sxs – HA worse over the past few days ...has not returned to work, has leave from 1.1.12; first missed day 19.12.11...advised sxs may linger for weeks, but if ongoing beyond, pt may wish referral on his private insurance to ENT." Pet. Ex. 4 at 21.

Notably, petitioner denied that he would ever have used the term "vertigo" because it would have meant he would be unable to fly. Pet. Ex. 76 at 1. Petitioner also never reported his prior history of episodes similar to his complaints after the October 17, 2013 flu vaccine and February 2014 upper respiratory infection to any of his treating physicians in the fall of 2013 and thereafter.

Despite Dr. Hicks's arguments to the contrary, Drs. Collins and Bigelow referenced petitioner's medical records confirming that petitioner was treated with and responded to amitriptyline, a medication effective in treating migraine headaches. Pet. Ex. 69 at 1; Resp. Ex. F at 3; Resp. Ex. C at 9 (citing Resp. Ex. C, Tab 13¹³¹ at 3). Petitioner reported 60-70% improvement with amitriptyline to Dr. Bronstein on June 6, 2015. Pet. Ex. 3 at 3. He reported "very severe recurrence of his symptoms if he stopped taking amitriptyline to Dr. Khemani on June 15, 2015. Pet. Ex. 4 at 131. He continued reporting that he felt 60-70% better on amitriptyline in September 2015. *Id.* at 133. Dr. Bigelow opined that it would be an "error in medical judgment" to conclude that a partial but not complete response to the medication indicates that petitioner does not have vestibular migraine, particularly because patients often only respond partially, and it is common to try a series of medications to find something that works for an individual. Resp. Ex. F at 3.

Additionally, Dr. Bigelow explained that if petitioner had vestibular neuritis there would be significant injury to the vestibular system, testing would demonstrate peripheral vestibular abnormalities, and for someone like petitioner who experiences recurring symptoms, the

¹³¹ F. Michael Cutrer & Zahid Bajwa, *Pathophysiology, clinical manifestations, and diagnosis of migraine in adults*, UPTODATE (July 29, 2017, 11:33 AM), <https://www.uptodate.com/contents/pathophysiology-clinical-manifestations-and-diagnosis-of-migraine-in-adults>, filed as "Resp. Ex. C, Tab 13."

vestibular testing would remain abnormal unless the symptoms were unrelated to inner ear vestibular pathology. Resp. Ex. A at 18. Further, vestibular neuritis is typically unilateral, has an extremely low recurrence rate of 1.9%,¹³² and a second occurrence typically affects the contralateral ear. It is therefore “extremely unlikely” that petitioner’s recurring symptoms were caused by vestibular neuritis. Resp. Ex. F at 6. Petitioner did not experience any unilateral symptoms and his vestibular testing in April 2014 and November 2014 failed to demonstrate evidence of viral damage to the inner ear. Pet. Ex. 5 at 6, 13.

Dr. Hicks conceded that “migraine is a possible diagnosis as it contributed to his symptoms” then rejected the diagnosis, claiming it cannot be proven or defined by any test. He then embraced the diagnosis of vestibular neuritis, which he also conceded cannot be proven by specific diagnostic testing. Pet. Ex. 69 at 10. Petitioner’s treating physicians treated him for and maintained based on his clinical history and presentation that he suffered from vestibular migraines. This is also supported by the opinions of both of respondent’s experts. All experts agree there is no specific diagnostic testing for either vestibular neuritis or vestibular migraine. However, the literature supports abnormal findings on vestibular testing where vestibular neuritis exists. Despite the foregoing, Dr. Hicks maintains that petitioner has vestibular neuritis, but points to nothing in the record to support the diagnosis. He discredits petitioner’s vestibular testing as unreliable and claims other testing should have been performed that would have proven useful. Though other testing may or may not have been helpful, speculation does not support a diagnosis of vestibular neuritis. The vestibular testing that was conducted was not supportive and nothing else in the record suggests a diagnosis of vestibular neuritis. Further, while Dr. Hicks argues that amitriptyline was ineffective or unsuccessful, petitioner’s medical records show that it was 60-70% effective and his symptoms worsened when he failed to take it. Pet. Ex. 3 at 3. Therefore, there is no persuasive evidence in the record to establish vestibular neuritis as petitioner’s diagnosis.

Treating doctors’ views about the appropriate diagnosis are often persuasive because the doctors have direct experience with the patient they are diagnosing. *See McCulloch v. Sec’y of Health & Human Servs.*, No. 09-293V, 2015 WL 3640610, at *20 (Fed. Cl. Spec. Mstr. May 22, 2015). The medical records, opinions of petitioner’s treating physicians, objective test results, family history of migraines in his mother, prior history of vertigo and response to amitriptyline used to prevent recurring migraines even if not 100% effective provides preponderant evidence supportive of vestibular migraines and unresponsive of vestibular neuritis. Therefore, there is no support in the record that petitioner suffered from vestibular neuritis but rather from vestibular migraines which remain chronic but are 60-70% controlled with migraine medication. Pet. Ex. 4 at 112; Pet. Ex. 8 at 2.

2. Petitioner Failed to Advance a Sound and Reliable Medical Theory

The first *Althen* prong requires petitioner to provide a “reputable medical theory” demonstrating that the vaccines received *can* cause the type of injury alleged. *Pafford*, 451 F.3d at 1355-56 (citation omitted). To satisfy this prong, petitioner’s “theory of causation must be supported by a ‘reputable medical or scientific explanation.’” *Andreu ex rel. Andreu v. Sec’y of Health & Human Servs.*, 569 F.3d 1367, 1379 (Fed. Cir. 2009) (quoting *Althen*, 418 F.3d at

¹³² Huppert et al., *supra* note 61.

1278). This theory need only be “legally probable, not medically or scientifically certain.” *Id.* at 1380 (emphasis omitted) (quoting *Knudsen*, 35 F.3d at 548). This standard was recently clarified by the Federal Circuit. See *Boatmon*, 941 F.3d at 1359-60 (stating that the correct standard for *Althen* prong one is “reputable,” and “sound and reliable” not a “lower reasonable standard” (internal quotations omitted)). Nevertheless, “petitioners [must] proffer trustworthy testimony from experts who can find support for their theories in medical literature.” *LaLonde v. Sec’y of Health & Human Servs.*, 746 F.3d 1334, 1341 (Fed. Cir. 2014). In this case, petitioner has not offered a reputable medical theory of causation that the flu vaccine caused or significantly aggravated petitioner’s vestibular neuritis.

Though it has already been determined that there is a lack of evidence to support a diagnosis of vestibular neuritis in this case, for purposes of being thorough, petitioner’s experts offered two theories as to how the FluMist vaccine could cause vestibular neuritis to satisfy Prong I. Neither of petitioner’s experts offered a theory for how the flu vaccine could cause or aggravate vestibular migraines.

a. Memory response

Dr. Tuohy opined that petitioner suffered inner ear symptoms following receipt of the FluMist intranasal vaccine which were consistent with a memory response causing rapid clonal expansion of previously primed lymphocytes. Pet. Ex. 11 at 2-3 (citing Pet. Ex. 16¹³³ at 1; Pet. Ex. 17¹³⁴ at 2, 5; Pet. Ex. 18¹³⁵ at 1; Pet. Ex. 20¹³⁶ at 18, 24). In other words, a memory response from either prior flu virus or vaccination produced inflammatory cytokines in the nasal mucosa that were enhanced by the viral induced innate immune response and entered blood circulation through the mucosal blood vessels in the nasal sinuses. Due to the proximity of the sinuses to the inner ear tissues, the cytokines then damaged inner ear tissues, which have “extremely high sensitivity” to inflammatory cytokines. *Id.* at 3. Dr. Tuohy relied on several studies that discuss autoimmune inner ear disease where an absence of molecules that oppose the inflammatory cytokine, IL-1 β , results in an inflammatory cytokine cascade which can promote the development of autoimmune disease of the inner ear through cytokines that damage the tissue. Pet. Ex. 11 at 3 (citing Pet. Ex. 22¹³⁷ at 2; Pet. Ex. 21¹³⁸ at 2, 7).

Dr. Tuohy further opined that the chronicity of petitioner’s symptoms resulted from the induction of postinfectious autoimmune inner ear disease leading to “cascading waves of neoautoactivity and incomplete recoveries.” He relied on literature that discussed autoimmune

¹³³ Shin-ichi Tamura et al., *Superior cross-protective effect of nasal vaccination to subcutaneous inoculation with influenza hemagglutinin vaccine*, 22 EUR. J. IMMUNOLOGY 477 (1992), filed as “Pet. Ex. 16.”

¹³⁴ Terrence M. Tumpey et al., *Mucosal Delivery of Inactivated Influenza Vaccine Induces B-Cell-Dependent Heterosubtypic Cross-protection against Lethal Influenza A H5N1 Virus Infection*, 75 J. VIROLOGY 5141 (2001), filed as Pet. Ex. 17.”

¹³⁵ Ayato Takada et al., *Intranasal immunization with formalin-inactivated virus vaccine induces a broad spectrum of heterosubtypic immunity against influenza A virus infection in mice*, 21 VACCINE 3212 (2003), filed as “Pet. Ex. 18.”

¹³⁶ Carter & Curran, *supra* note 54.

¹³⁷ Pathak et al., *supra* note 16.

¹³⁸ Vambutas et al., *supra* note 66.

myocarditis¹³⁹, autoimmune encephalomyelitis¹⁴⁰, and multiple sclerosis.¹⁴¹ None of the literature related to flu virus or vaccination. Pet. Ex. 11 at 4 (citing Pet. Ex. 25¹⁴²; Pet. Ex. 27¹⁴³).

Dr. Bigelow opined that Dr. Tuohy's theory did not fit with the anatomy of the ear because although the nose and ear are in close proximity of one another, the blood supply to the inner ear is not connected to the nasal mucosa and sinuses. Resp. Ex. A at 16. Specifically, the labyrinthine artery, which provides the blood supply to the cochlea and the vestibular end organs, is not connected to the nasal vasculature but rather is a branch of the anterior inferior cerebellar artery. *Id.* Thus, if the vaccine caused inflammatory cytokines to circulate to the labyrinthine artery, both the vestibular end organ and cochlea would have been affected and petitioner would have experienced hearing loss or tinnitus, which he did not have. *Id.*

Drs. Tuohy and Hicks addressed Dr. Bigelow's criticism, explaining that intranasal vaccination facilitates rapid entrance of drugs into the local and systemic blood supply and allows for bypassing of the blood brain barrier to the central nervous system and brain. Pet. Ex. 68 at 2 (citing Pet. Ex. 70¹⁴⁴ at 4); Pet. Ex. 69 at 8. In response, Dr. Bigelow pointed out that the literature relied on by petitioner's experts involved midazolam¹⁴⁵, a medication known to easily pass the blood brain barrier, not influenza vaccine. Resp. Ex. F at 4. According to Dr. Bigelow, there is no literature that suggests that the flu vaccine can pass the blood brain barrier, and if it did, petitioner would have had symptoms of viral encephalitis, which he did not. *Id.*

Dr. Bigelow conceded it is "potentially feasible" that flu virus could enter the inner ear if there was disseminated virus in the bloodstream, but if this were to happen, based on the anatomy of the ear the labyrinthine artery would distribute the viral load to the cochlea causing hearing loss or tinnitus from damage to the cochlea. Resp. Ex. F at 4-5.

Dr. Collins agreed that an autoimmune response against cochlear proteins would lead to hearing loss, but petitioner did not have hearing loss. She added that Dr. Tuohy provided no evidence to support that an over-secretion of cytokines from receipt of an intranasal vaccine can cause inner ear inflammation. Resp. Ex. E at 3. Further, she disputed Dr. Tuohy's assertion that post-viral autoimmune-induced tissue damage could chronically affect the labyrinth, noting that while petitioner's initial presentation may have fit with post-viral damage, such damage would be transient. *Id.*; Pet. Ex. 5 at 14. Overall, Dr. Collins opined that Dr. Tuohy provided no evidence that influenza virus can cause persistent infection with chronic symptoms. Resp. Ex. E at 3.

¹³⁹ Myocarditis is inflammation of the muscular walls of the heart. *Dorland's* 1204.

¹⁴⁰ Encephalomyelitis refers to inflammation involving both the brain and the spinal cord. *Dorland's* 607.

¹⁴¹ Multiple sclerosis is "a disease in which there are foci of demyelination throughout the white matter of the central nervous system, sometimes extending into the gray matter; symptoms usually include weakness, incoordination, paresthesias, speech disturbances, and visual complaints. The course of the disease is usually prolonged, so that the term *multiple* also refers to remissions and relapses that occur over a period of many years." *Dorland's* 1653.

¹⁴² Rose et al., *supra* note 40.

¹⁴³ Tuohy et al., *supra* note 77.

¹⁴⁴ Djupesland, *supra* note 41.

¹⁴⁵ Midazolam is a benzodiazepine used as an antianxiety agent and muscle relaxant. *Dorland's* 1148.

b. HSV-1 Reactivation

Dr. Hicks deferred to Dr. Tuohy's immunological explanations then provided an alternative theory which he described as "complementary." Pet. Ex. 13 at 9, 16; Pet. Ex. 75 at 2. Dr. Hicks opined that the intranasal live attenuated virus vaccine caused a stress response in the vestibular system, reactivating latent HSV-1 in the geniculate and vestibular ganglion, resulting in an inflammatory response of the superior vestibular nerve within its narrow bony channel, causing symptoms.¹⁴⁶ Pet. Ex. 69 at 5-6. Dr. Hicks argued that reactivation of latent HSV-1 is the assumed etiology of vestibular neuritis, which he opined was what petitioner suffered from. Pet. Ex. 13 at 15. He referenced literature to support reactivation of HSV-1 as a factor in vestibular neuritis and as evidence that latent HSV-1 can be found in the geniculate and vestibular ganglion. Pet. Ex. 69 at 2; *see* Pet. Ex. 33,¹⁴⁷ Pet. Ex. 44,¹⁴⁸ Pet. Ex. 46,¹⁴⁹ Pet. Ex. 48.¹⁵⁰

Dr. Hicks proposed that his theory involves two pathways that "more likely led to petitioner's disease": 1) the intranasal vaccine initiated both a humeral and vigorous cellular response superimposed on a pre-existing memory cell population of latent HSV-1; or 2) the intranasal vaccine resulted in a fulminant infection which compromised the immune system and reactivated latent HSV-1. Pet. Ex. 13 at 16. This occurs when intranasal flu vaccine is absorbed by the nasal membranes that are rich in blood vessels, leading to a rapid spread to the inner ear via branches of the maxillary artery and anterior vestibular artery. Either of these pathways can lead to inner ear vestibular injury by reactivating latent HSV-1 due to a stress or inflammatory response from co-infection. *Id.*; Pet. Ex. 69 at 8-9. "[B]roader and deeper distribution of vaccine into the nasal respiratory mucosa" can support the stress response that caused the reactivation of HSV-1. *Id.* In other words, the live attenuated nasal vaccine causes a stronger, more vigorous immune response than an intramuscular flu vaccine and is then enhanced by a memory cell population from prior infection with HSV-1, influenza vaccine, or both. This triggered inflammation or a stress response within the vestibular system resulting in the reactivation of latent HSV-1 within the vestibular ganglion, spreading centrally and peripherally causing damage to the vestibular system. Dr. Hicks submits that Dr. Tuohy's and his theories complement each other, and both provide biologically plausible explanations for why the FluMist is responsible for petitioner's vestibular complaints and resulting damage. Pet. Ex. 13 at 9.

Dr. Bigelow opined that it would be "extremely unlikely" that FluMist vaccine would cause enough stress to reactivate latent HSV-1 leading to secondary inner ear injury. Further, he could not find any published studies associating flu or other vaccines with reactivation of latent HSV-1. Resp. Ex. A at 17. Dr. Bigelow noted that the route of spread through the Eustachian tube to the middle ear then the inner ear via the round or oval windows is potentially possible, since the Eustachian tube connects the nasopharynx to the inner ear. *Id.* at 18. However, if that

¹⁴⁶ Dr. Hicks discusses this theory in the subsections for Prong II in his reports, but because he states that it is complementary to and part of "a continuum of the seamless cascade of events" described by Dr. Tuohy, the analysis is better suited as part of Prong I. Pet. Ex. 75 at 2.

¹⁴⁷ Arbusow et al., *supra* note 59.

¹⁴⁸ Arbusow et al., *supra* note 87.

¹⁴⁹ Arbusow et al., *supra* note 89.

¹⁵⁰ Furuta et al., *supra* note 119.

were the case, Dr. Bigelow would expect a middle ear infection to have occurred and there to have been symptomatic fluid in the inner ear and hearing loss. *Id.*

Dr. Hicks responded that latent HSV-1 can be reactivated by simple genotoxic stress, such as too much sun, emotional or physical stress, fever, or the common cold, and therefore disagreed that the FluMist was unlikely to reactivate latent HSV-1, stating “I believe it can.” Pet. Ex. 69 at 9.

Dr. Collins added that vaccinations have not been shown to induce HSV-1 reactivation. Resp. Ex. C at 9. Further, whether HSV-1 can cause vestibular neuritis is controversial. She explained that Dr. Hicks’s theory is flawed because he invokes reactivated HSV-1 as the cause of petitioner’s symptoms but claims that antiviral medications effective in treating HSV-1 in other contexts are not effective in treating vestibular neuritis because the HSV-1 has returned to its latent state. Resp. Ex. E at 7. Succinctly, Dr. Collins submitted that antiviral medication effective in treating HSV-1 reactivation has not demonstrated any benefit in those with vestibular neuritis, which argues against a role of HSV-1 in vestibular neuritis. *Id.*; Resp. Ex. C, Tab 1.¹⁵¹

c. Analysis

Ultimately, neither Dr. Tuohy nor Dr. Hicks adequately explained how the anatomy of the inner ear supports their respective theories of causation in a manner that overcomes the criticisms raised by Drs. Bigelow and Collins. While Dr. Tuohy cited literature supporting that a memory response could occur, a disconnect remains as to how the inflammatory cytokines could then cause damage to the inner ear without damage to the cochlea and hearing loss or lead to vestibular neuritis if the anatomical pathway is not possible. Dr. Hicks’s HSV-1 reactivation theory faces similar anatomical concerns. Further, there is no evidence to support that influenza vaccine can reactivate latent HSV-1, that HSV-1 infection can cause vestibular neuritis or that petitioner suffered from a reactivation of an HSV-1 infection.

In discussing the pathogenesis of vestibular neuritis, Dr. Hicks relied on the *Greco* study which stated:

It is a well-established axiom of otolaryngology that when the inner ear is involved in disease, cochlear and vestibular elements are compromised, which leads to hearing loss and vertigo. In cases of vestibular neuronitis, vertigo occurs in the absence of hearing loss, *the inner ear is not involved*, and the lesion lies in the vestibular neurons central to the labyrinth.

Resp. Ex. C, Tab 4¹⁵² at 2 (emphasis added). Further, *Greco* noted that it is unclear whether the disease is caused by direct infection, localized thrombosis or an autoimmune reaction. *Id.* Association with preceding or concurrent infectious illnesses occur in 43-46% of cases. *Id.* at 3. Studies have demonstrated serological evidence of recent upper respiratory tract infections including influenza A, B, and adenovirus, herpes simplex virus, cytomegalovirus, Epstein Barr

¹⁵¹ Baloh, *supra* note 9.

¹⁵² Greco et al., *supra* note 48.

Virus, rubella virus, and parainfluenza virus. However, no virus has been isolated from the blood, respiratory tract, or cerebral spinal fluid of patients. *Id.*

Dr. Hicks's theory is merely an iteration of the hypothesis in the *Greco* study but with a different outcome. The *Greco* study noted that the histopathology of vestibular neuritis showed atrophy of the vestibular nerve and the vestibular sensory epithelium, which were similar in known viral disorders such as herpes zoster oticus.¹⁵³ Resp. Ex. C, Tab 4 at 3. Animal models of vestibular neuritis were then developed by injecting HSV-1 into the auricle¹⁵⁴ of mice, inducing vestibular symptomatology. The presence of viral antigens was identified within the vestibular membrane of the labyrinth and Scarpa's ganglion¹⁵⁵ cells, however "[e]vidence for viral infection in vestibular neuritis in humans was less convincing." *Id.* Vestibular neuritis and Bell's palsy share similarities, and reactivation of neurotropic viruses including HSV-1 has been suggested as the cause of both. HSV-1 DNA has been detected by polymerase chain reaction (PCR) at the time of autopsy in human vestibular ganglia. Resp. Ex. C, Tab 4 at 3. It was hypothesized that if HSV-1 was the most likely cause of vestibular neuritis, the virus would reside in a latent state in the vestibular ganglia or ganglionic nuclei as reported in other cranial nerves. Other biological factors would allow the virus to suddenly replicate, inducing inflammation and edema causing secondary cell damage of the vestibular ganglion cells and axons in the bony canal. *Id.* However, evidence to support the hypothesis was circumstantial. *Id.* The authors noted that while an inflammatory component resulting from a viral infection might be the cause, treatment with corticosteroids has proven to have a better clinical outcome than antivirals which showed no effectiveness. *Id.* The authors concluded that "[t]hese results are in agreement with the hypothesis that vestibular neuritis is not a viral disease but is an autoimmune disease." *Id.* at 6.

Dr. Hicks opined that intranasal flu vaccine is absorbed by the nasal membranes which are rich in blood vessels, leading to a rapid spread to the inner ear via branches of the maxillary artery and anterior vestibular artery, and can lead to inner ear vestibular injury by reactivating latent HSV-1 due to an inflammatory or stress response as a result of co-infection. Pet. Ex.13 at 16; Pet. Ex. 69 at 9. However, as *Greco* highlighted, vestibular neuritis does not involve the inner ear, creating an irreconcilable flaw in Dr. Hicks's theory of how the FluMist reactivated HSV-1 and caused inner ear vestibular injury leading to petitioner's alleged vestibular neuritis. Petitioner has failed to provide a sound and reliable scientific theory for how FluMist can cause vestibular neuritis. Neither Dr. Tuohy nor Dr. Hicks provided any theory for how the intranasal flu vaccine could cause or aggravate vestibular migraine, the more supported diagnosis in this case.

Therefore, without any evidence supporting a biologically sound and reliable theory for how the intranasal flu vaccine can cause vestibular neuritis, petitioner has failed to meet his burden under *Althen* Prong I.

¹⁵³ Herpes zoster oticus is another name for Ramsay Hunt Syndrome. See Resp. Ex. C, Tab 4 at 2.

¹⁵⁴ The auricle is "the projecting, shell-like structure on the side of the head, constituting, with the external acoustic meatus, the external ear. *Stedman's* 86270.

¹⁵⁵ Scarpa's ganglion, or the vestibular ganglion, is the "sensory ganglion located in the upper part of the lateral end of the internal acoustic meatus, the bipolar nerve cells of which give rise to the fibers of the vestibular nerve." *Dorland's* 752.

3. There is a Lack of Logical Connection Between Petitioner's Vaccination and his Alleged Injury.

The second *Althen* prong requires proof of a “logical sequence of cause and effect.” *Capizzano*, 440 F.3d at 1326 (quoting *Althen*, 418 F.3d at 1278). In other words, even if the vaccinations can cause the injury, petitioner must show “that it did so in [this] particular case.” *Hodges v. Sec’y of Health & Human Servs.*, 9 F.3d 958, 962 n.4 (Fed. Cir. 1993) (citation omitted). “A reputable medical or scientific explanation must support this logical sequence of cause and effect,” *id.* at 961 (citation omitted), and “treating physicians are likely to be in the best position to determine whether a logical sequence of cause and effect show[s] that the vaccination was the reason for the injury,” *Paluck v. Sec’y of Health & Human Servs.*, 786 F.3d 1373, 1385 (Fed. Cir. 2015) (quoting *Andreu*, 569 F.3d at 1375). Petitioner is not, however, required “to eliminate alternative causes as part of establishing [their] prima facie case.” *Doe v. Sec’y of Health & Human Servs.*, 601 F.3d 1349, 1357-58 (Fed. Cir. 2010); see *Walther v. Sec’y of Health & Human Servs.*, 485 F.3d 1146, 1152 (Fed. Cir. 2007) (holding that a “petitioner does not bear the burden of eliminating alternative independent potential causes”).

Petitioner's claims that the FluMist vaccine caused him to suffer vestibular neuritis that is chronic. Petitioner did not claim that the FluMist vaccine caused him to suffer from vestibular migraines, that it aggravated his vestibular migraines, or that the FluMist vaccine can cause vestibular migraines. Even if petitioner had been able to demonstrate that he experienced vestibular neuritis and/or presented a medical theory that FluMist vaccine can cause vestibular neuritis to satisfy Prong I, the record does not support a relationship between the FluMist vaccine he received on October 17, 2013 and his chronic symptoms. Although petitioner and his experts dispute the accuracy and significance of his medical history, petitioner's medical history and clinical course demonstrate that petitioner has suffered from the same or similar symptoms at various times since at least 2006. Further, petitioner's development of chronic symptoms in April 2014 occurred following an upper respiratory infection in February of 2014 which was unrelated to the October 17, 2013 vaccine.

a. Petitioner's Past History of Vertigo

Petitioner has a documented history of vertigo that predates his receipt of the flu vaccine on October 17, 2013. In July 2006, petitioner was evaluated by ENT surgeon Dr. Warrington after experiencing three reported episodes of vertigo in that year: the first in January lasting for about ten hours, the second a few months later for the same duration, and the third in July lasting for 36 hours. Pet. Ex. 4 at 78. The vertigo was described as a sensation of spinning associated with nausea that happened on moving, though it did not appear to be strictly positional. *Id.*

Petitioner denies having ever experienced vertigo prior to receiving the vaccine at issue. Pet. Ex. 10 at 1; Pet. Ex. 76 at 1. He described the symptoms he experienced in 2006 as “mild dizziness” related to sinus congestion and stated that he never would have used the term vertigo to describe those symptoms because that would have resulted in his inability to fly. *Id.*

Petitioner in his Motion for Ruling on the Record and his experts in their respective reports rely on petitioner's sworn statements as evidence that he did not experience vertigo prior to his October 17, 2013 FluMist vaccine. However, Dr. Tuohy (and petitioner) disregarded the history that Dr. Warrington documented, opting only to rely on Dr. Warrington's statement that "there does not appear to be anything sinister behind his episodes of vertigo and that it is unlikely that the vertigo shall ever seriously interfere with his ability to fly." Dr. Tuohy therefore questioned the validity of the 2006 vertigo diagnosis as being accurate. Pet. Ex. 68 at 1. Dr. Tuohy concluded that petitioner's symptoms of true vertigo experienced after the vaccine and chronically since could not be mistaken for the benign dizziness he experienced in 2006. *Id.* He further disregarded petitioner's presentation for medical care on December 20, 2011 for "several issues," including his having "had flu jab, then had uris sxs, back and forth from sinuses to chest and back, pounding HAs on descent, pain behind eyes..." and return for care on December 28, 2011 with continuing symptoms and worsening headache. He had to take leave from flying during this episode as well, with referral to an ENT again considered. Pet. Ex. 4 at 21.

Drs. Tuohy and Hicks criticized petitioner's medical care, claiming there were many misdiagnoses. Dr. Tuohy relied on notations in the record "marked in error" to argue that evidence of petitioner's 2006 vertigo diagnosis was likely erroneous as well. Pet. Ex. 13 at 19; Pet. Ex. 68 at 1; *see* Pet. Ex. 4 at 21, 25. However, what was marked as "error" was not the findings and diagnosis of an examination, but the content of a letter following an examination that was notably not uploaded to the file due to incorrect data. Pet. Ex. 4 at 21. The record itself was not marked "in error". Dr. Tuohy claimed that other diagnoses such as gastrointestinal issues were listed in error, when the record supports petitioner seeking care and being treated for gastrointestinal issues for years prior and after the alleged vaccination. Pet. Ex. 68 at 1; Pet. Ex. 4 at 10, 12, 26.

Medical records created contemporaneously with the events they describe are generally considered to be more trustworthy. *Cucuras v. Sec'y of Health & Human Servs.*, 993 F.2d 1525, 1528 (Fed. Cir. 1993); *but see Kirby v. Sec'y of Health & Human Servs.*, 993 F.3d 1378, 1382-83 (Fed. Cir. 2021) (clarifying that *Cucuras* does not stand for the proposition that medical records are presumptively accurate and complete). While not presumed to be complete and accurate, medical records made while seeking treatment are generally afforded more weight than statements made by petitioner after-the-fact. *See Gerami v. Sec'y of Health & Human Servs.*, No. 12-442V, 2013 WL 5998109, at *4 (Fed. Cl. Spec. Mstr. Oct. 11, 2013) (finding that contemporaneously documented medical evidence was more persuasive than the letter prepared for litigation purposes), *mot. for rev. denied*, 127 Fed. Cl. 299 (2014). Indeed, "where later testimony conflicts with earlier contemporaneous documents, courts generally give the contemporaneous documentation more weight." *Campbell ex rel. Campbell v. Sec'y of Health & Human Servs.*, 69 Fed. Cl. 775, 779 (2006); *see United States v. U.S. Gypsum Co.*, 333 U.S. 364, 396 (1948). A patient's motivation for providing an accurate recount of symptoms is more immediate as opposed to testimony offered after the events in question, which is considered inherently less reliable. *Reusser v. Sec'y of Health & Human Servs.*, 28 Fed. Cl. 516, 523 (1993); *see Murphy v. Sec'y of Health & Human Servs.*, 23 Cl. Ct. 726, 733 (1991), *aff'd*, 968 F.2d 1226 (Fed. Cir. 1992) (citing *United States v. U.S. Gypsum Co.*, 333 U.S. 364, 396 (1948)).

Petitioner denies using the term “vertigo” to describe his symptoms in 2006. However, the contemporaneous medical records created in 2006 indicate that the symptoms he was experiencing necessitated referral to a specialist, who assessed him with vertigo at that time. Dr. Warrington’s record is quite detailed in its description and duration of those symptoms. *See* Pet. Ex. 4 at 78. Petitioner’s experts rely on errors in the record unrelated to these events to suggest that records assessing petitioner with vertigo were in error. Pet. Ex. 13 at 5; Pet. Ex. 68 at 1-2. Their arguments are unpersuasive in bringing the reliability of the record into question.

Petitioner’s medical records confirm that petitioner’s symptoms and complaints were the same in 2006 following an upper respiratory infection, in 2011 following receipt of a flu vaccine and upper respiratory infections, in October 2013 following receipt of the FluMist vaccine, and in February of 2014 following another upper respiratory infection. The exception, however, was unlike his other episodes which fully resolved, petitioner’s upper respiratory infection in February 2014 brought on an onset of symptoms that did not resolve and prompted a visit to Dr. Brookes in April 2014 followed by treatment for migraines, vertigo, and neck pain. In all instances, petitioner reported dizziness and nausea without any hearing loss or tinnitus, and feelings of motion sickness.¹⁵⁶ Pet. Ex. 4 at 21.

Having denied that he had any prior history of vertigo or migraines, petitioner did not allege or submit a significant aggravation claim or analysis in this case. *See W.C. v. Sec’y of Health & Human Servs.*, 704 F.3d 1352, 1357 (Fed. Cir. 2013) (“[A] petitioner in an off-table case must show the vaccine actually caused the significant aggravation—not just that, accepting petitioner’s medical theory as sound, the person’s condition worsened within a medically-acceptable timeframe”). Having failed to provide a sound and reliable theory of causation for vertigo or migraines or any expert opinion of aggravation beyond a passing concession of exacerbation of vestibular migraines by Dr. Hicks,¹⁵⁷ that analysis is unnecessary. Further, as set forth at length above, petitioner’s symptoms fully resolved by December 2013, two months after his FluMist vaccine. The onset of his chronic vertigo began following an upper respiratory infection in February 2014 as he reported to Dr. Brookes in April 2014. Pet. Ex. 4 at 21.

b. Petitioner’s Clinical Course

Petitioner experienced symptoms of dizziness and nausea at some point following his October 17, 2013 FluMist vaccine. Petitioner did not complain of any symptoms of ear infection, fluid in the ear, hearing loss, or ringing in his ears as Dr. Bigelow opined would have been expected had the FluMist traveled through the Eustachian tube to the middle and inner ear. Resp. Ex. A at 18. Further, petitioner did not experience symptoms indicative of a fulminant flu infection following the subject flu vaccine, as Dr. Collins opined he would have if Dr. Hicks’s opinion of reactivation of HSV-1 had occurred. Resp. Ex. E at 7.

¹⁵⁶ In 2006, petitioner’s symptoms were noted as happening on moving. Pet. Ex. 4 at 78. After his receipt of the vaccine, in 2015, they were described as a “motion sickness type sensation” and “dizzy or disorientation feelings” that can increase in elevators, on planes when they tilt and there is no visual fixation, and in cars and trains. Pet. Ex. 3 at 1, 3.

¹⁵⁷ In his third report, Dr. Hicks stated that “what is indisputable is that MC’s symptoms were initiated (vestibular neuritis) or exacerbated (vestibular migraine) by his IN vaccination in October 2013.” *See* Pet. Ex. 75 at 5. There were no other opinions provided on significant aggravation, nor was the claim asserted by petitioner.

It is unknown whether petitioner's complaints following his receipt of the flu vaccine on October 17, 2013 were the result of an unrelated viral infection or triggered by his flu vaccine. Further, the time of onset is unclear. Petitioner reported receiving the FluMist in the U.S. and flying back to the U.K. "shortly thereafter" when he then developed symptoms.¹⁵⁸ Pet. Ex. 1 at 1. His record also documents his "awaking at 5pm in the afternoon" two days after his flu vaccine with dizziness and associated symptoms. Pet. Ex. 7 at 12. Regardless, the contemporaneous medical records document that petitioner had complete resolution of his illness by December 2013. Between his last medical visit in November 2013 and February 11, 2014, petitioner did not seek or receive any medical care associated with his vaccine related claims. Pet. Ex. 4 at 23-24.¹⁵⁹ Petitioner presented to his PCP on February 11, 2014, requesting a return-to-work certificate reporting that he felt well with no dizziness or headache after taking medication for dizziness "only for a few days." Pet. Ex. 4 at 24. He reported that his last symptoms were on December 23, 2013 and were minor. *Id.*

In his third sworn statement, however, petitioner affirmed that though his condition had improved by December 2013, it had "definitely not resolved" and he was still experiencing nausea and dizziness. Pet. Ex. 76 at 1. He affirmed that he still had symptoms of vertigo in February 2014 that were less intense and frequent, but he "proactively" requested clearance to return to work, thinking that he would fully recover in the time that it would take to recertify and retrain. *Id.* at 2. Petitioner affirmed that this choice was based on the mounting career and financial pressure he felt. *Id.*

Petitioner's affirmations conflict with the contemporaneous medical records. While it is reasonable that petitioner would feel pressure to return to work and take steps to do so, the disparity between what he reported to his PCP for purposes of receiving clearance to fly differs considerably from his affirmations of continuing symptoms for purposes of this case. It is difficult to reconcile the two sets of facts, particularly when he not only reported to his PCP on February 11, 2014 that his symptoms had completely resolved in December 2013, but again reported the same to Dr. Brookes on April 30, 2014 when he presented for symptoms that would not go away after an upper respiratory illness in February 2014 and for which he was grounded and no longer permitted to fly.

Further, other evidence in the medical record supports the resolution of symptoms in December 2013 and provides further explanation of what transpired after his February 11, 2014 visit with the PCP. When petitioner presented to Dr. Brookes on April 15, 2014, he reported that he had four weeks of vertigo and vomiting that eased and "had gone" two months later, in December 2013. Pet. Ex. 4 at 109; Pet. Ex. 5 at 22. He reported he was then symptom-free for two months until he caught an upper respiratory infection in February, after which his symptoms of nausea and a sensation of movement began again intermittently. *Id.*

As highlighted in Dr. Bigelow's reports, the contemporaneous medical records support that petitioner experienced a complete resolution of his initial illness in December 2013 and was

¹⁵⁸ It is unclear when petitioner's symptoms began and whether he was asymptomatic in the days following his receipt of the FluMist.

¹⁵⁹ The record includes an entry from January 22, 2014 that reads "Surgery: Mr. Jack Peevor" but does not provide any further information suggesting that there may be medical records that were not filed in this case. Pet. Ex. 4 at 24.

symptom-free until he suffered an upper respiratory infection sometime between his February 11, 2014 visit to his PCP and his presentation to Dr. Brookes. *See* Resp. Ex. A at 15; Resp. Ex. F at 2. The appearance of symptoms of dizziness in the context of this upper respiratory infection is not dissimilar to the dizziness and vertigo that he experienced in the context of sinus congestion in 2006 and again in 2011. Thus, given this history, the medical records support the onset of dizziness, nausea and vertigo after an upper respiratory illness in February 2014 for which he presented to his PCP on April 15, 2014 and requested a referral to an ENT. Unlike his past experiences with the same or similar symptoms after URI or other flu vaccine, his symptoms did not resolve but remained chronic and were deemed to be vestibular migraine related after extensive testing.

Petitioner experienced similar symptoms in the years prior to the receipt of the subject FluMist vaccine as he did after his receipt of the FluMist vaccine, following which he had a complete resolution after each episode including resolution in December 2013 following his October 2013 flu vaccine. Pet. Ex. 4 at 21, 24, 78. Petitioner had no additional medical care or complaints documented after November of 2013 or when he presented for and did return to work in February of 2014. He then suffered another upper respiratory infection at some point after February 11, 2014, with onset of symptoms of vertigo that reportedly remained chronic. *Id.* at 109. Petitioner's chronic symptoms which occurred after his February 2014 upper respiratory illness were not related to the FluMist vaccine received over four months prior. *See* Resp. Ex. A at 20. Petitioner has failed to satisfy his burden under *Althen* Prong II.

4. Proximate Temporal Relationship

To satisfy the third *Althen* prong, petitioner must establish a "proximate temporal relationship" between the vaccination and the alleged injury. *Althen*, 418 F.3d at 1281. This "requires preponderant proof that the onset of symptoms occurred within a timeframe for which, given the medical understanding of the disorder's etiology, it is medically acceptable to infer causation-in-fact." *de Bazan*, 539 F.3d at 1352. Typically, "a petitioner's failure to satisfy the proximate temporal relationship prong is due to the fact that onset was too late after the administration of a vaccine for the vaccine to be the cause." *Id.* However, "cases in which onset is too soon" also fail this prong; "in either case, the temporal relationship is not such that it is medically acceptable to conclude that the vaccination and the injury are causally linked." *Id.*; *see also Locane v. Sec'y of Health & Human Servs.*, 685 F.3d 1375, 1381 (Fed. Cir. 2012) ("[If] the illness was present before the vaccine was administered, logically, the vaccine could not have caused the illness.").

The evidence in this case supports a finding that petitioner suffered from the same symptoms prior to receiving the subject FluMist vaccine that he suffered following his receipt of the FluMist vaccine on October 17, 2013 that completely resolved two months later. However, even assuming petitioner had suffered from his claimed vestibular neuritis and Dr. Hicks's opinion that a secondary response by lymphocytes "typically has a much shorter lag period," neither of petitioner's experts provided evidence of a medically acceptable timeframe for the development of vestibular neuritis following an intranasal flu vaccine. Pet. Ex. 13 at 19 (citing Pet. Ex. 67¹⁶⁰ at 5). Neither discussed vestibular migraines. Dr. Collins explained that the

¹⁶⁰ ROBERT R. RICH ET AL., CLINICAL IMMUNOLOGY PRINCIPLES AND PRACTICE 199, 426 (3rd ed. 2008).

appearance of immune cells is not necessarily coincident with the development of vestibular symptoms, referencing two studies submitted by Dr. Tuohy in which symptom development took thirty days for Theiler's virus and up to two weeks for coxsackie B virus, even when activated immune cells were directly infused into the animal. Resp. Ex. C at 7; Pet. Ex. 28¹⁶¹; Pet. Ex. 27.¹⁶²

Accordingly, petitioner has failed to present preponderant evidence to satisfy his burden under *Althen* Prong III.

VI. Conclusion

Upon careful evaluation of all the evidence submitted in this matter—including the medical records, expert reports, and medical literature and other submitted arguments—I conclude that petitioner has not shown by preponderant evidence that he is entitled to compensation under the Vaccine Act. Petitioner has failed to offer sufficient evidence showing that the flu vaccination caused his alleged vestibular neuritis. **The petition is therefore DISMISSED. The Clerk shall enter judgment accordingly.**¹⁶³

IT IS SO ORDERED.

s/ Mindy Michaels Roth

Mindy Michaels Roth

Special Master

¹⁶¹ Miller et al., *supra* note 78.

¹⁶² Tuohy et. al, *supra* note 77.

¹⁶³ Pursuant to Vaccine Rule 11(a), entry of judgment can be expedited by each party filing a notice renouncing the right to seek review.